

# elbow; intercalary resection replantation

♂ 20 yo construction draftsman      1st referral: 27.02.2012

## HPI:

**Exulcerating Tumor right Elbow**

## PMH:

**Acute lymphatic B-cell leukemia June 1992**

# Jetziges Leiden

---

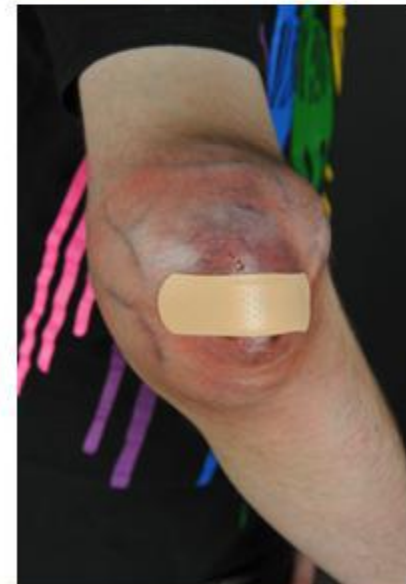
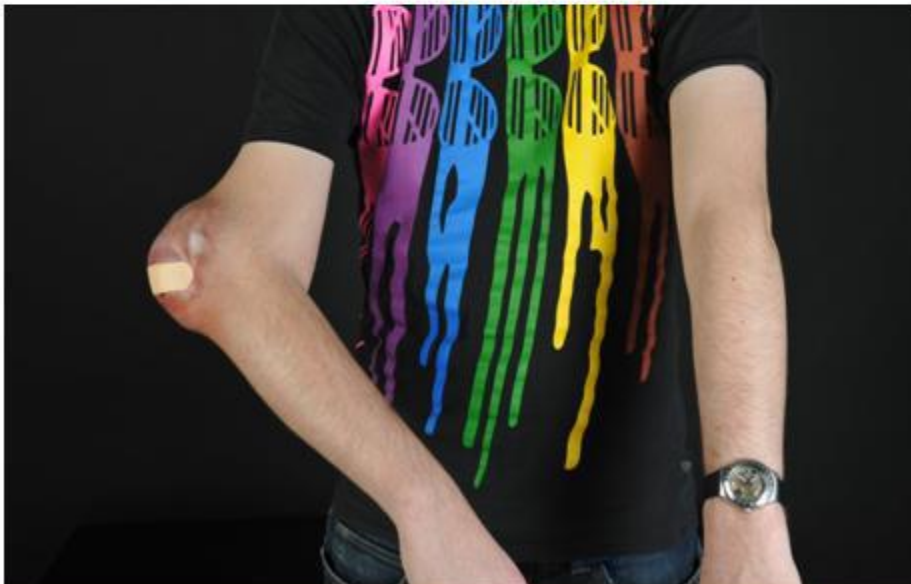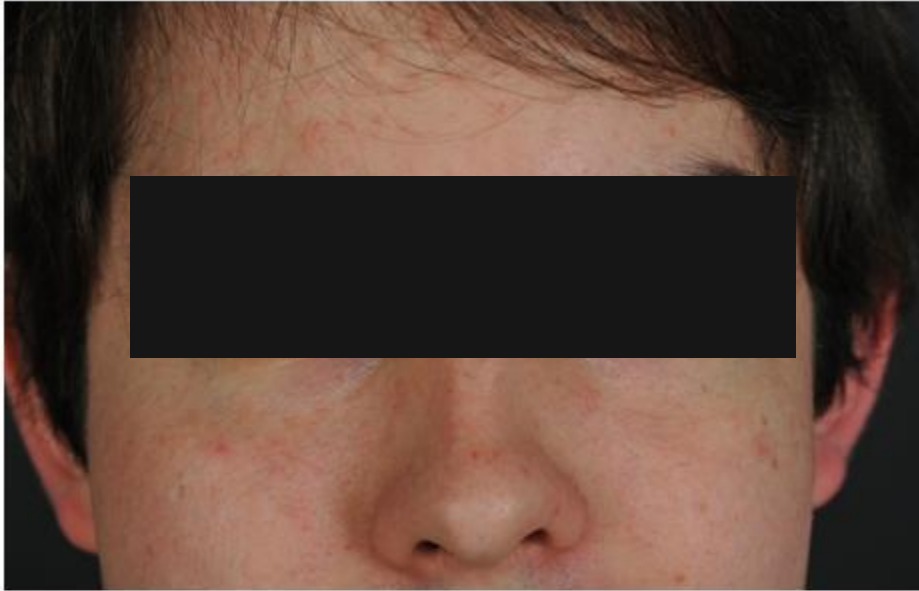2007:	Juni :	V.a. malignen Prozess im rechten Humerus, DD: Ewing-Sarkom, Osteosarkom, Osteomyelitis <b>1. Biopsie (Ellbogen):</b> V.a. Osteomyelitis ohne Erregernachweis antibiot. Therapie > Zunahme des Volumens
	Nov.:	<b>2. Biopsie (Ellbogen):</b> Reaktive T-zell-/histiozytäre Infiltration (Humerus und Synovia)
2008:	April:	Radiotherapie Ellbogen re 30 Gy >klinisch keine Besserung
	Juli:	Vergrößerung axill LK rechts <b>3. Biopsie (Lymphknoten):</b> T-zell-/histiozytäre Infiltration; V.a. Rosai-Dorfman disease Th mit Cladribine vorgeschlagen, von Fam. Abgelehnt
2010:	Feb:	PET-CT: Glc-uptake: dist. Humerus, Weichteile Oberarm und LK ax re
	März-Juli:	Cladribine (2-CDA) insgesamt 6 Zyklen
	Juli:	PET-CT: - dist. Humerus und Weichteile Oberarm: rückläufig - LK ax re: kein Glc-uptake mehr
	Dez :	PET-CT: - dist. Humerus und Weichteile Oberarm: progredient - LK ax re: erneuter Glc-uptake
2011	Juni–Nov:	LCHII: Prednison, Vinblastin, Mercaptopurin > klinischen Ansprechen jeweils unter den Steroidgaben
	Dez:	MR ; erneutes Chir. Konsilium weiterhin keine therapeutischen Möglichkeiten

# Februar 2012:

Ellbogen rechts mit klinisch eindrücklichem Tumor, lokale Schmerzen,  
kein Fieber, kein Gewichtsverlust, keine Knochenschmerzen  
lokal überwärmt, Bewegungsumfang stark eingeschränkt

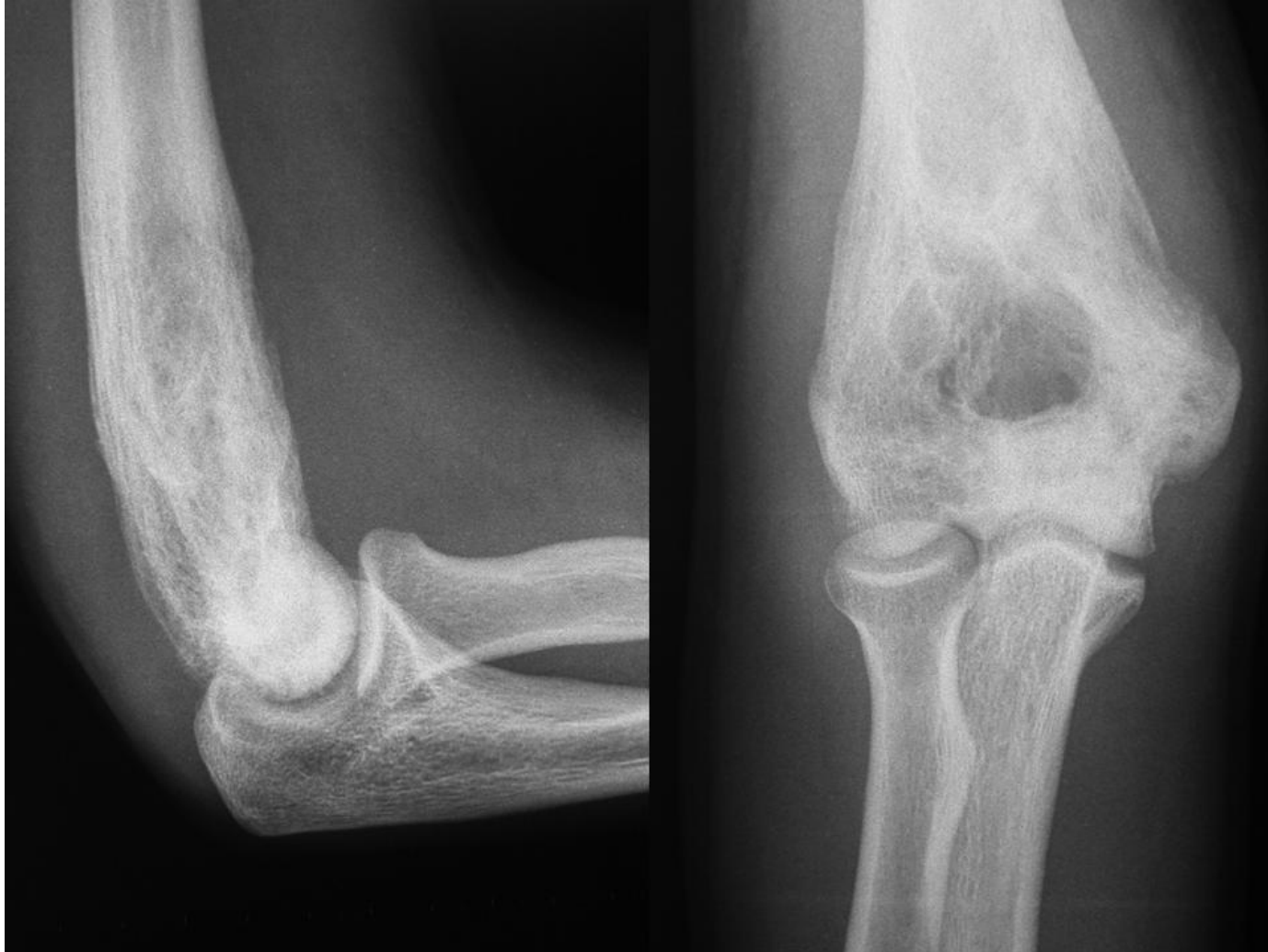Nieren- und Leberwerte, LDH, Harnsäure normal  
ausgeprägte Lymphopenie: CD4 0.06 G/l (ref. 0.30-1.40), Ig normal

# elbow; intercalary resection replantation



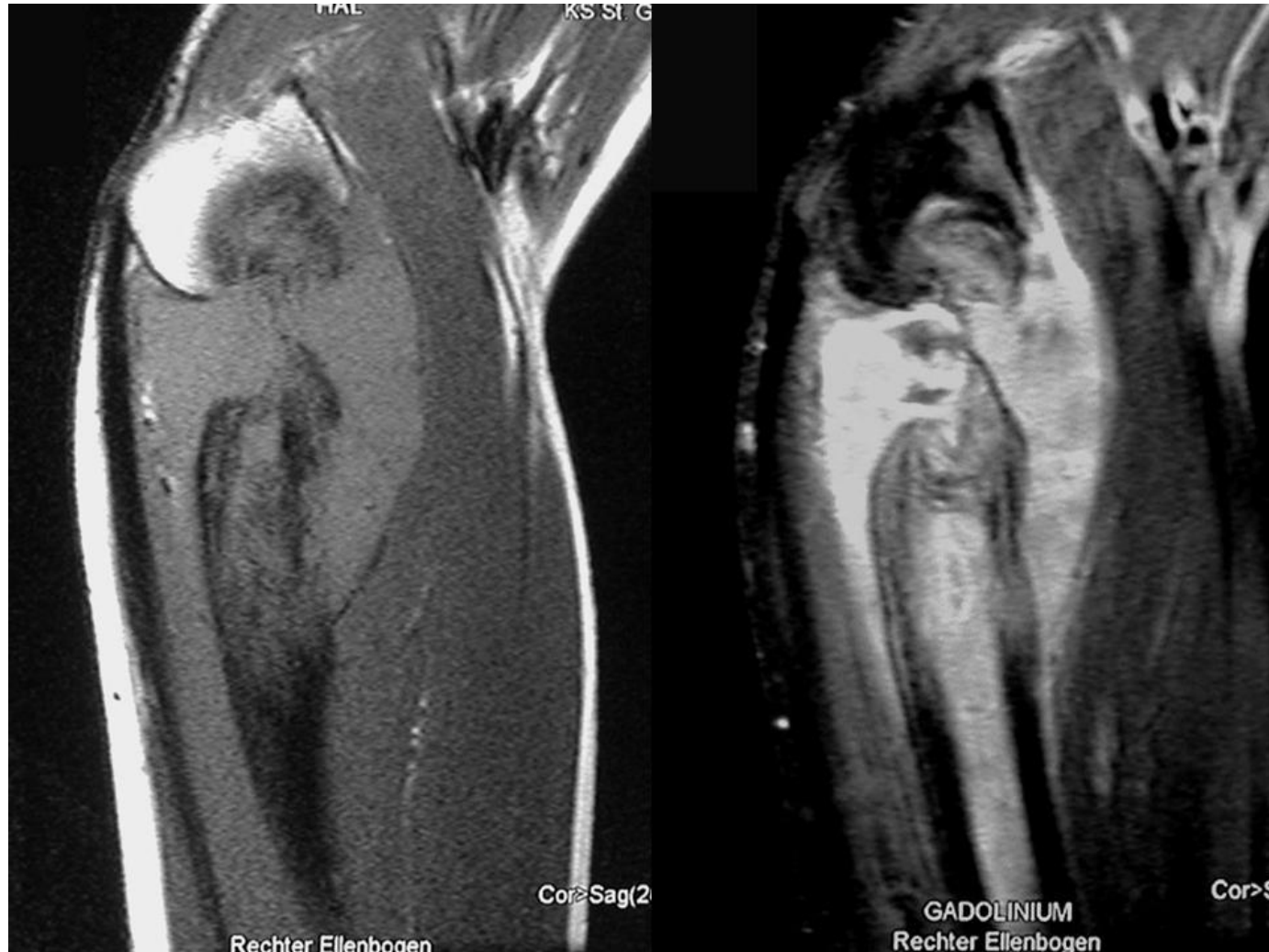
# elbow; intercalary resection replantation

## Xray elbow: May 2007



# elbow; intercalary resection replantation

## MRI elbow: May 2007



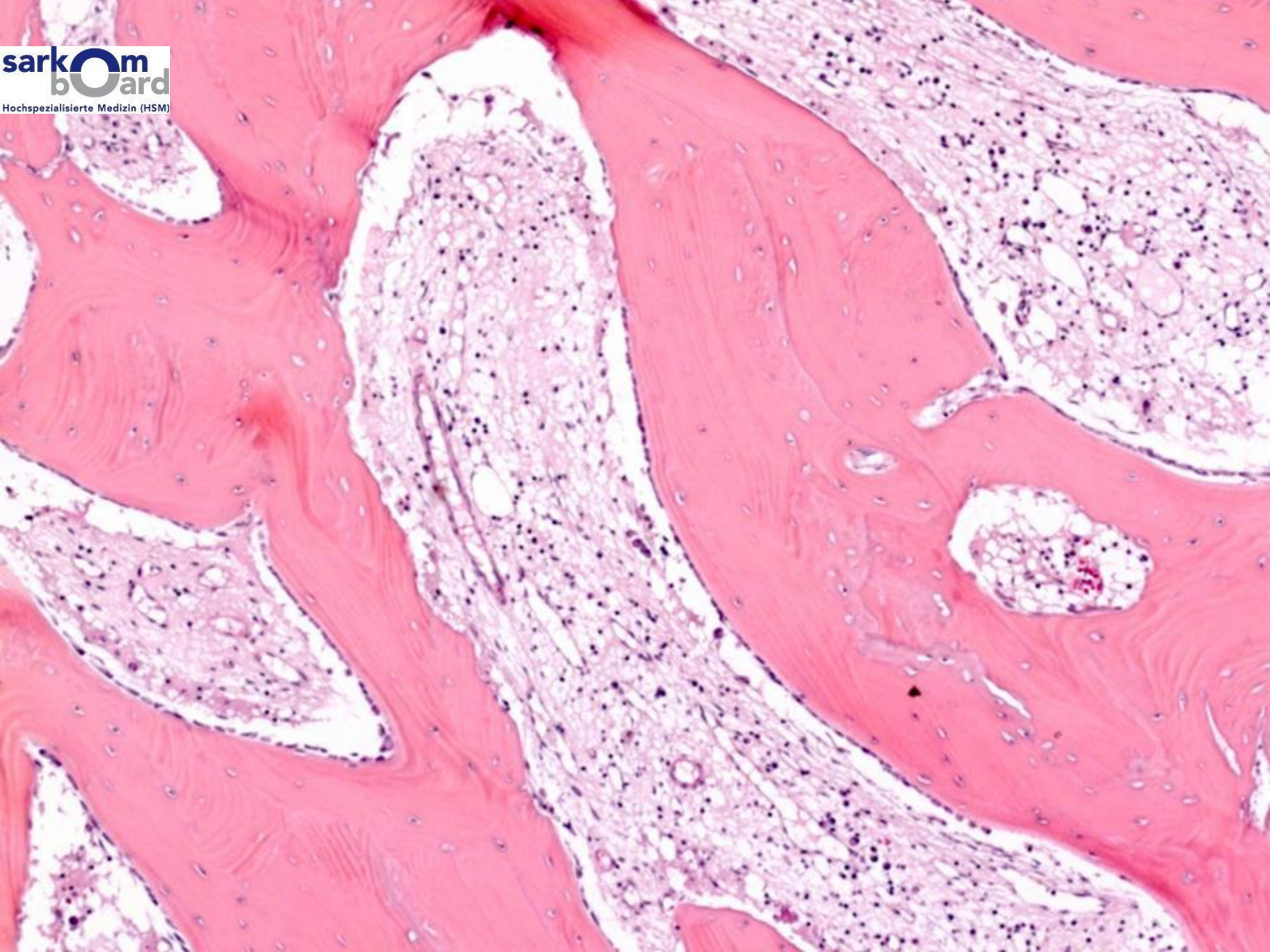
# 1. Biopsie Juni 2007

Klinische Angaben:

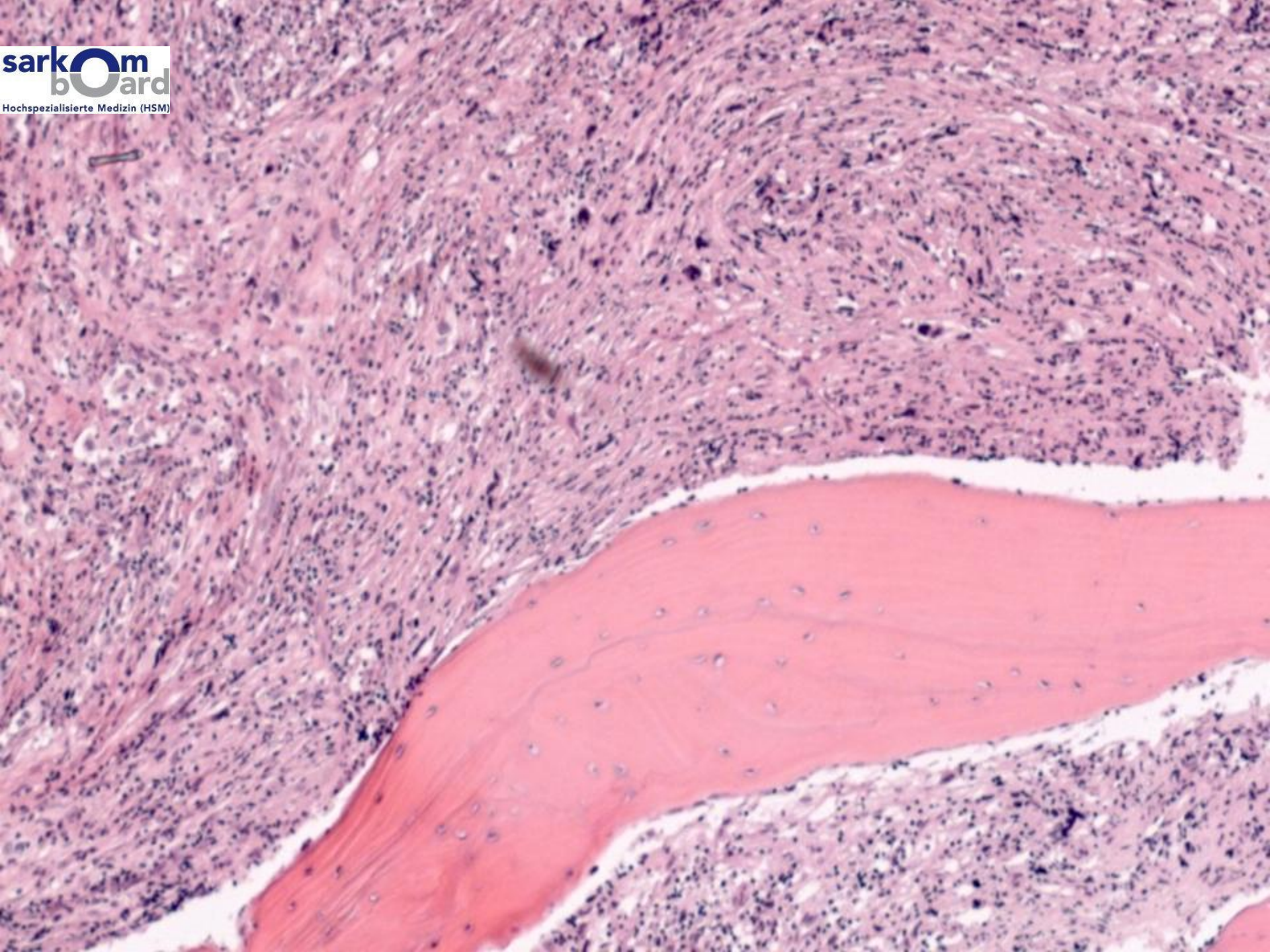
Vd. a. malignen Prozess im rechten Humerus, DD: Ewing-Sarkom,  
Osteosarkom, Osteomyelitis

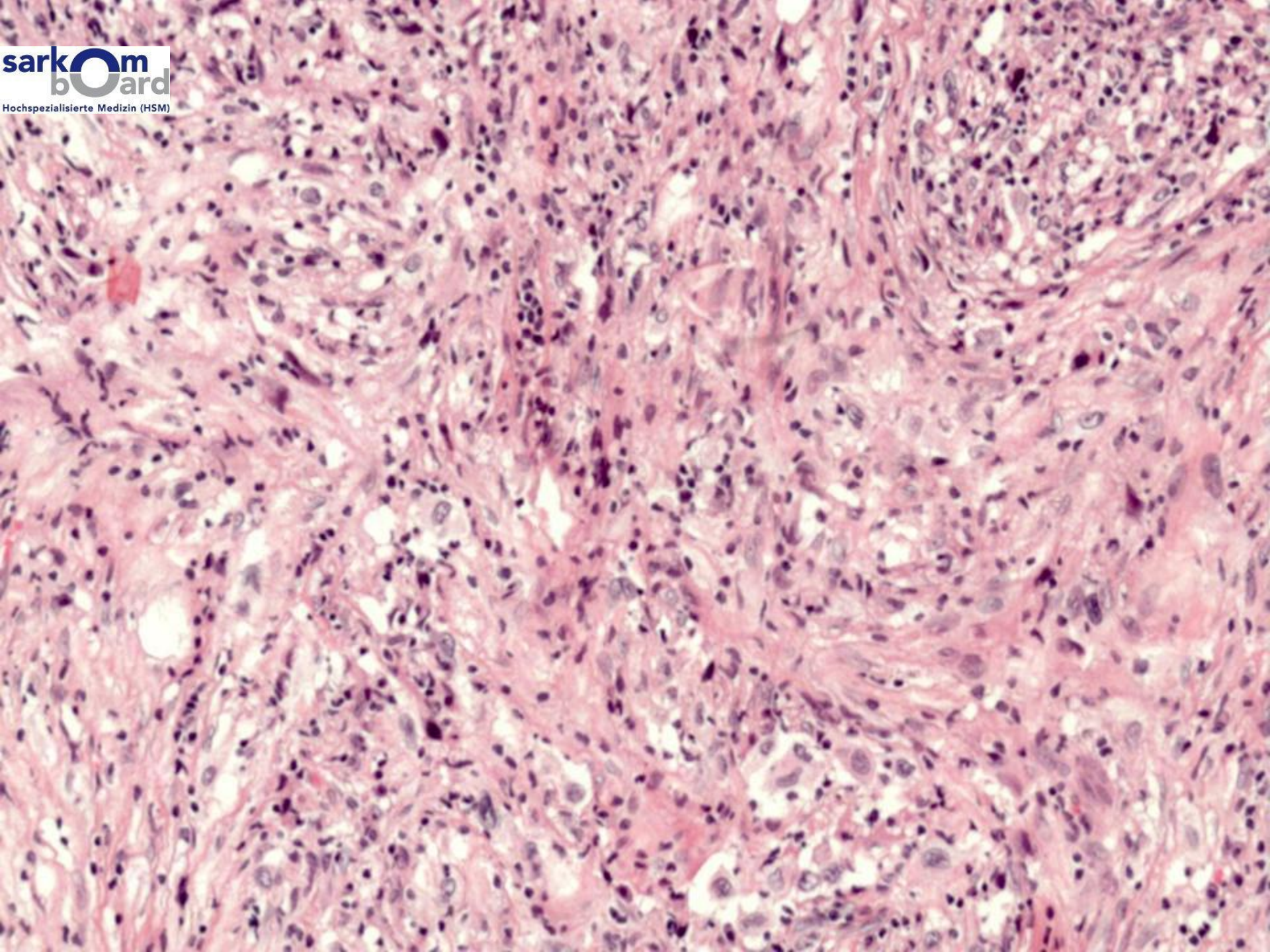
Pathologisch-anatomische Diagnose:

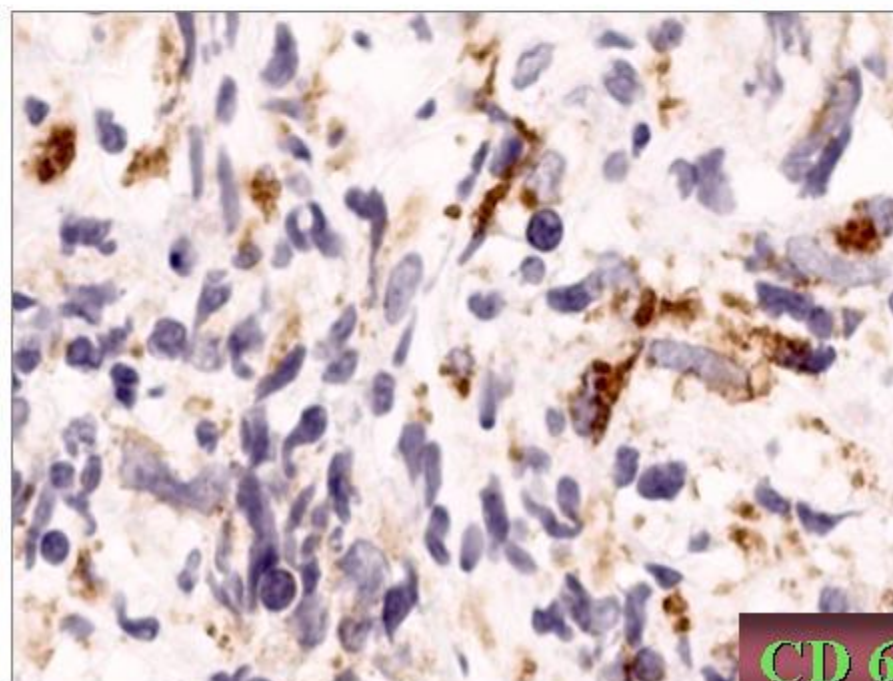
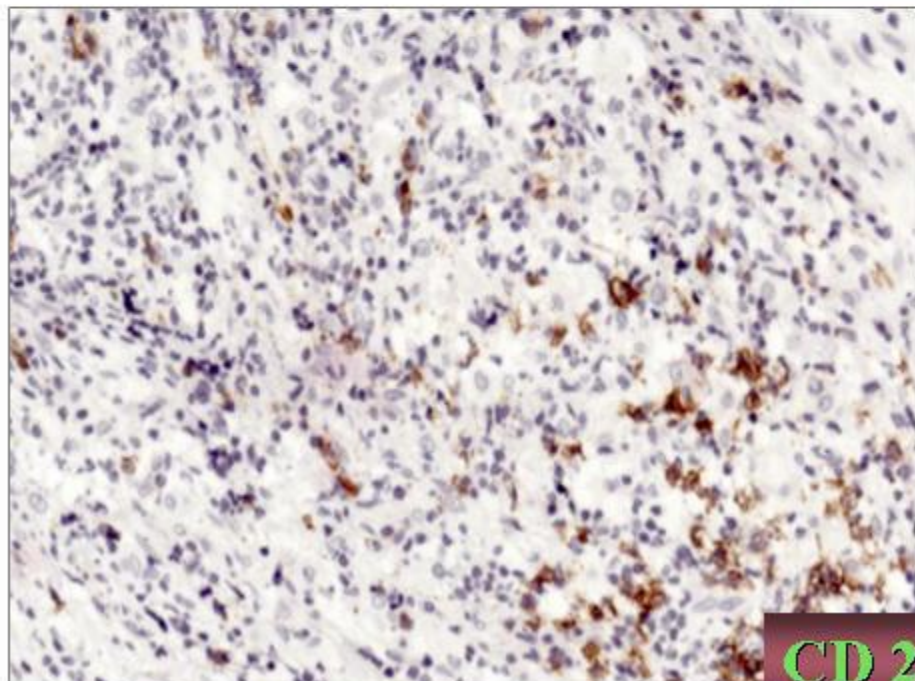
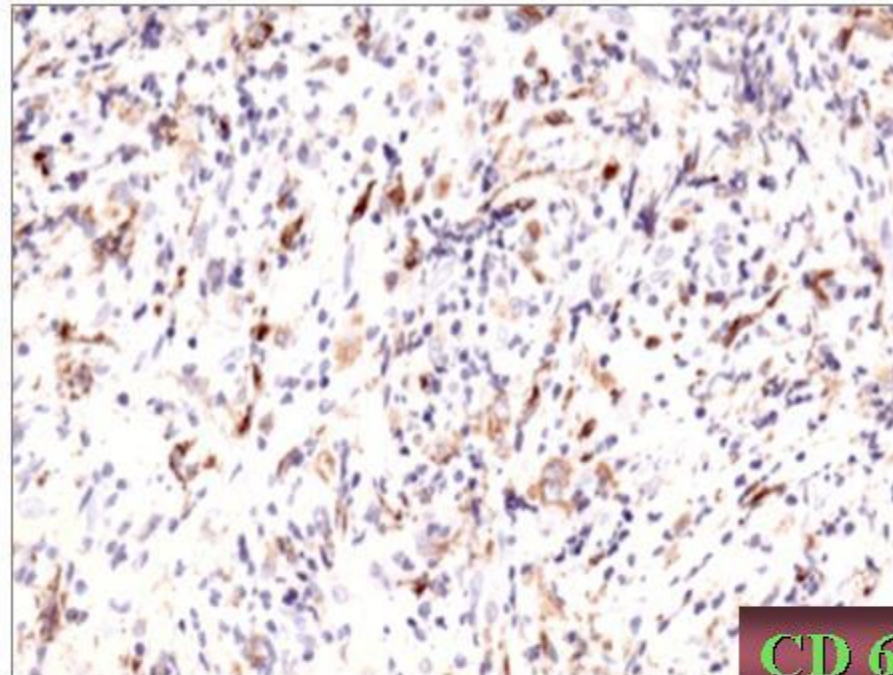
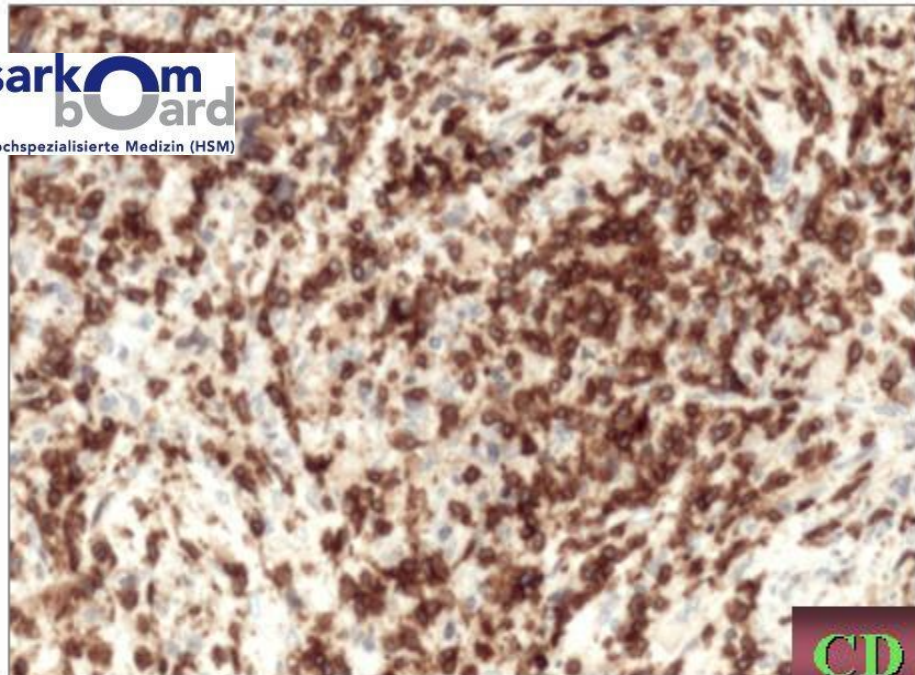
Chronische nur gering floride Osteomyelitis









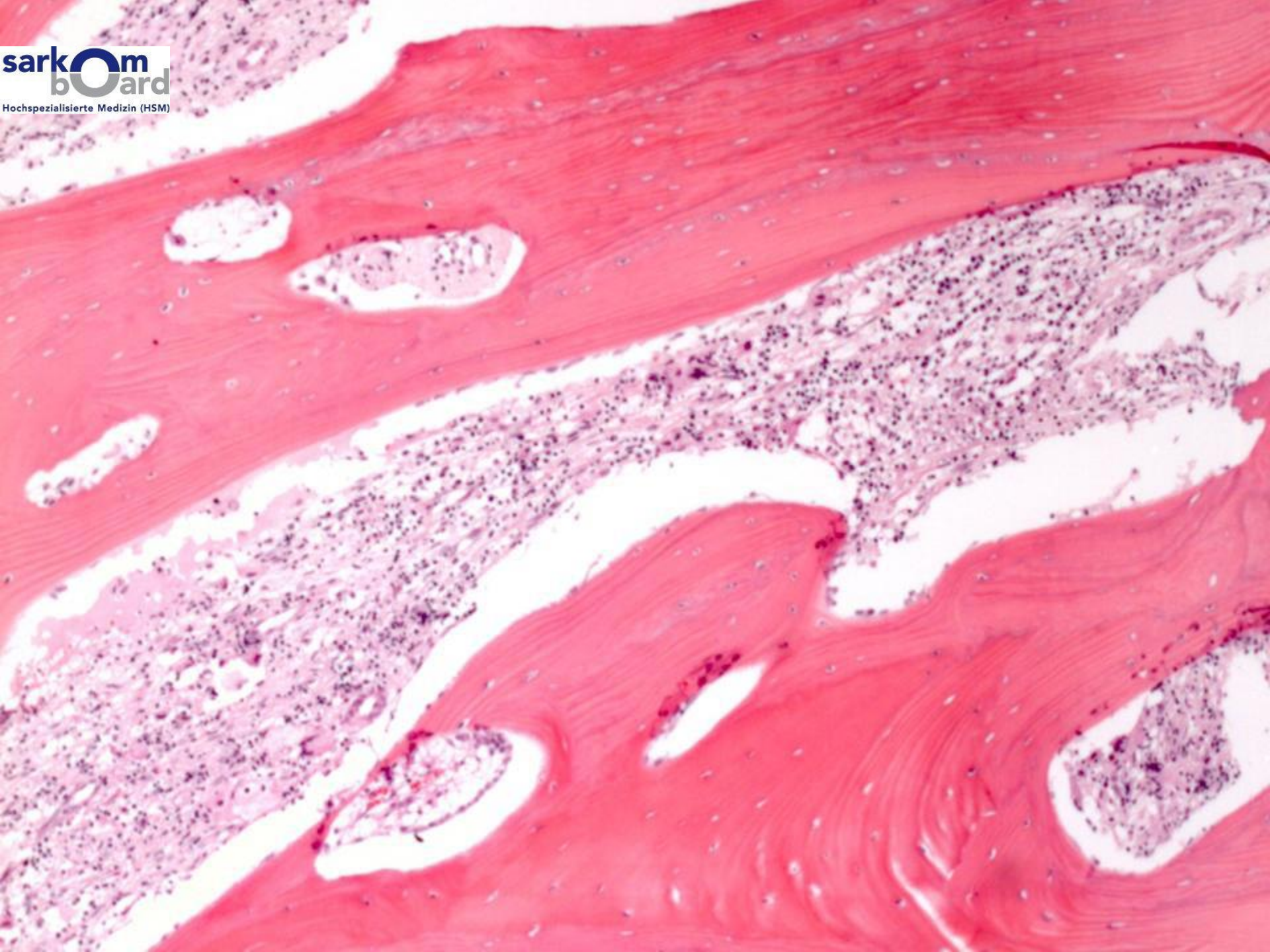


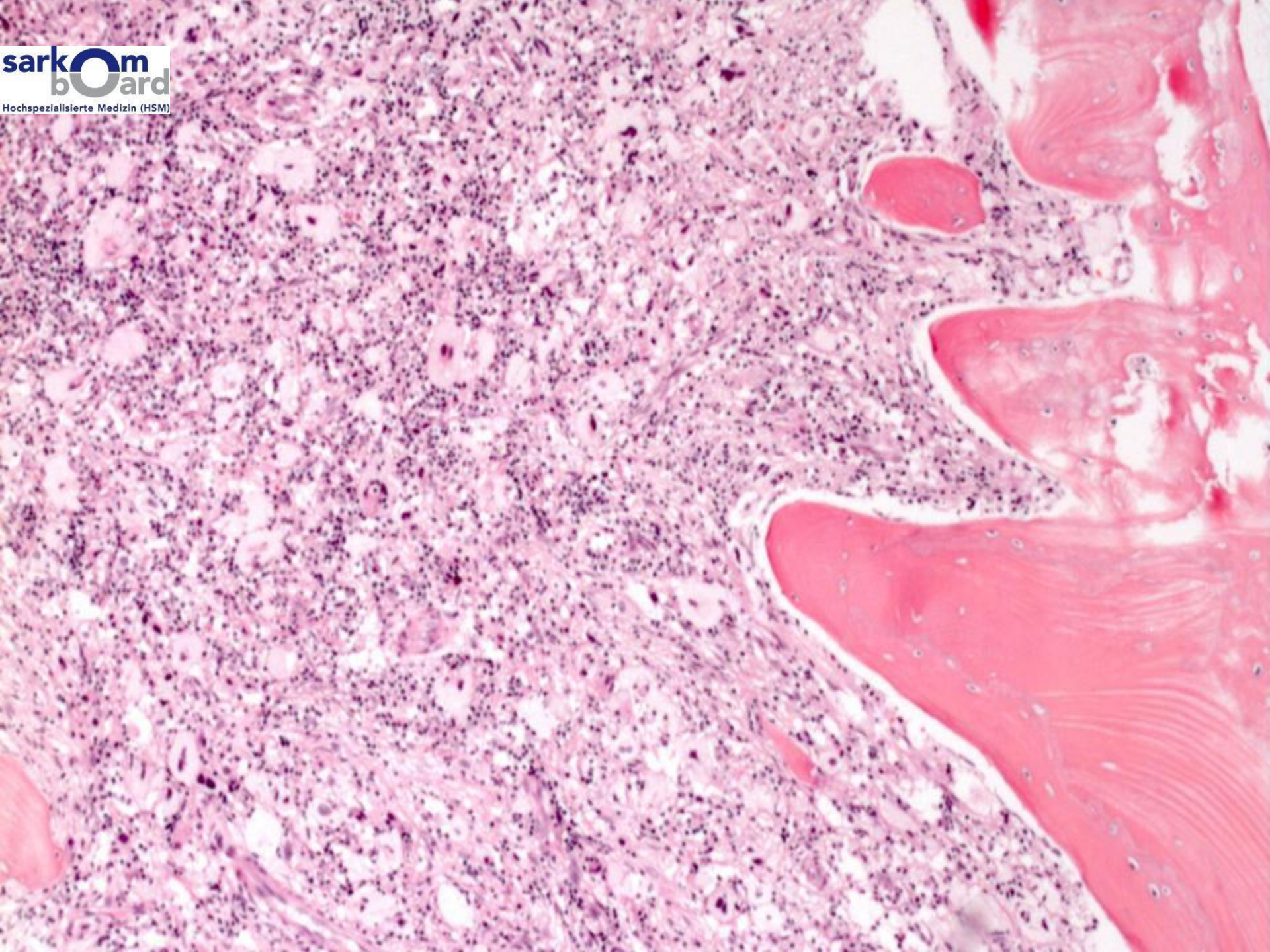
## 2. Biopsie: Dezember 2007

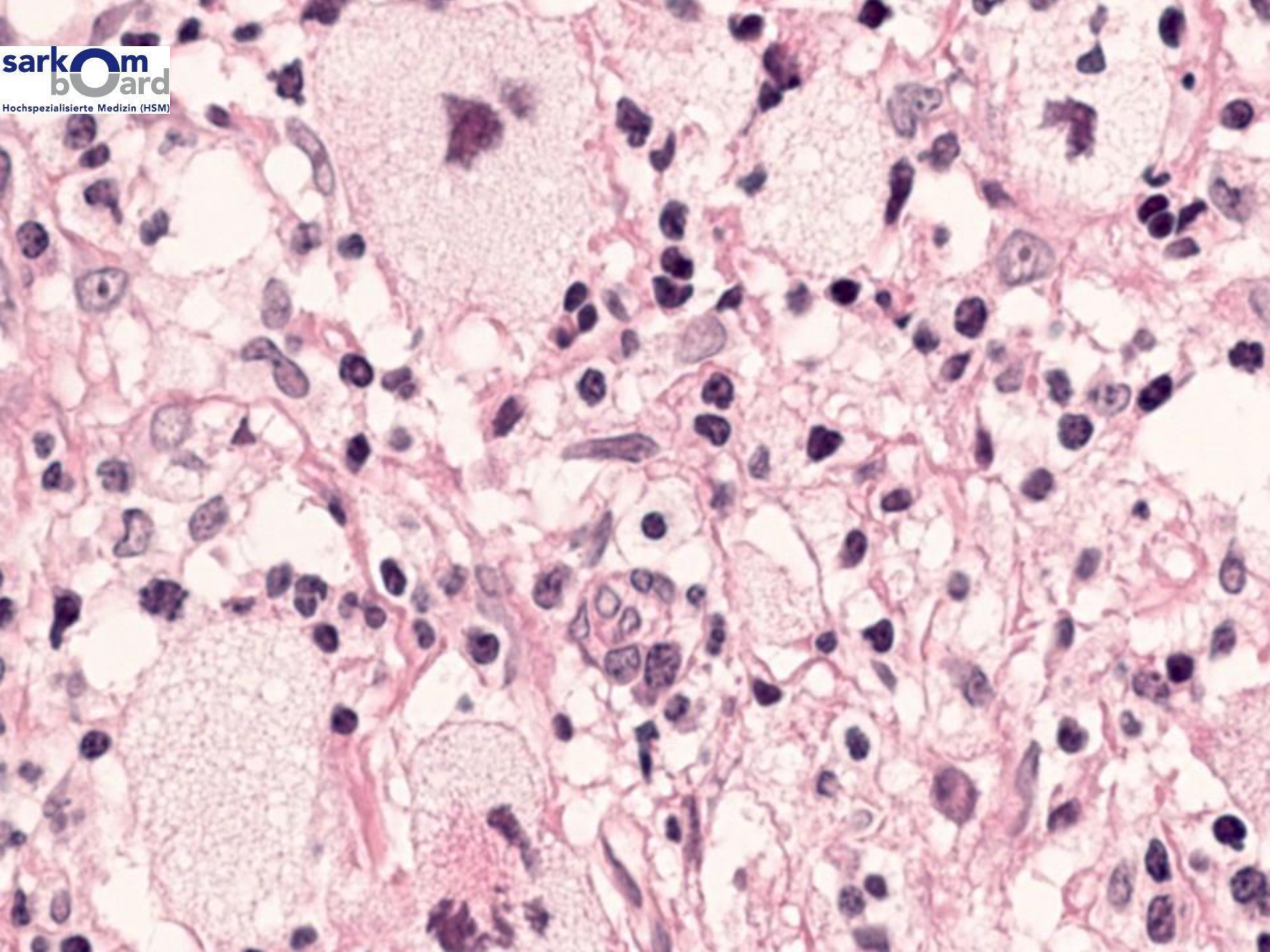
distaler Humerus rechts. Synovia Ellbogen re

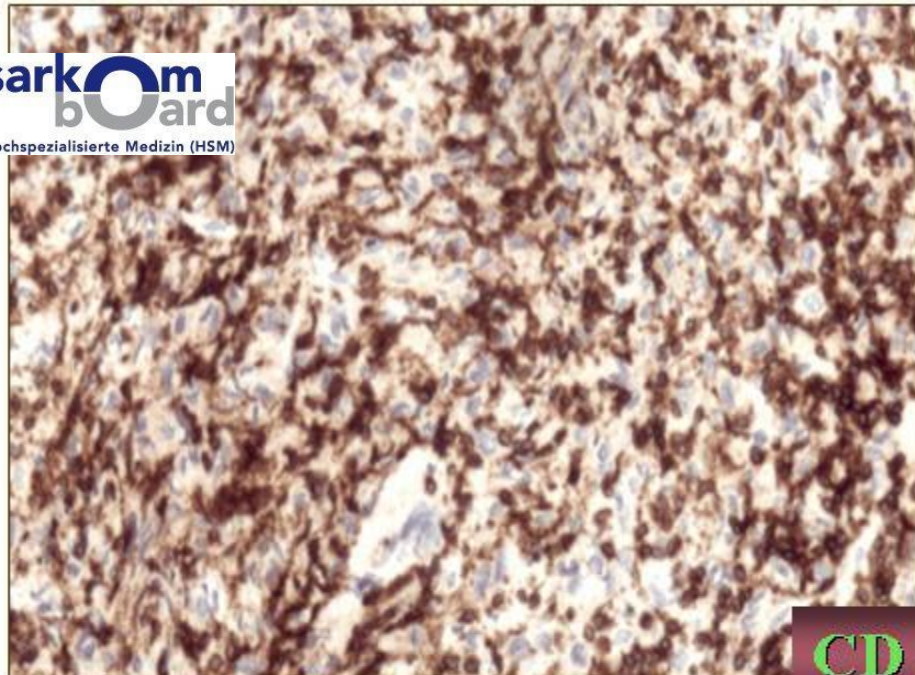
Pathologisch-anatomische Diagnose:

Reaktive T-zellreiche histiozytäre Infiltration ohne Anhalt für Malignität. Kein Nachweis von blutbildendem Knochenmark.

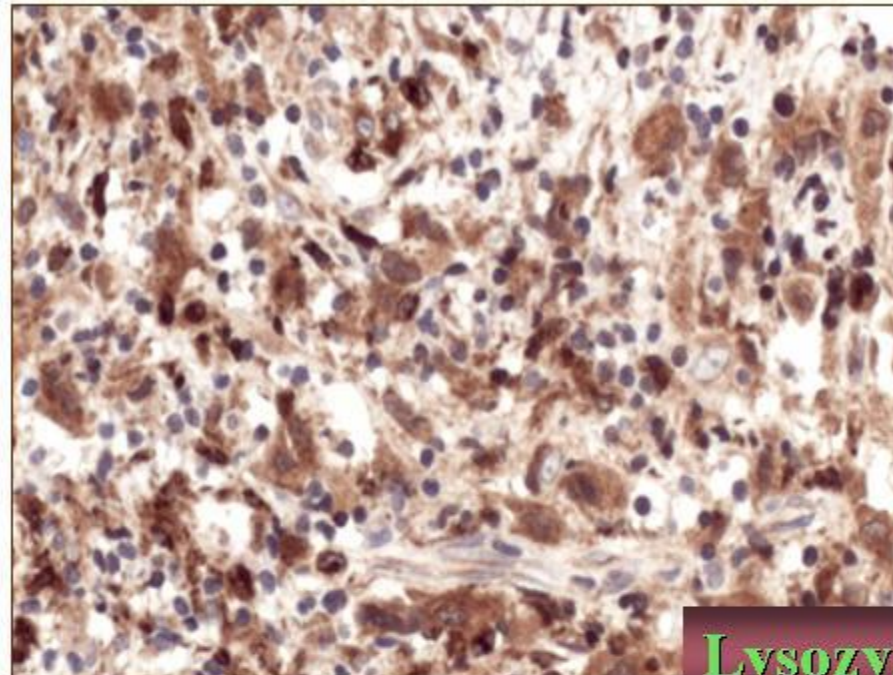




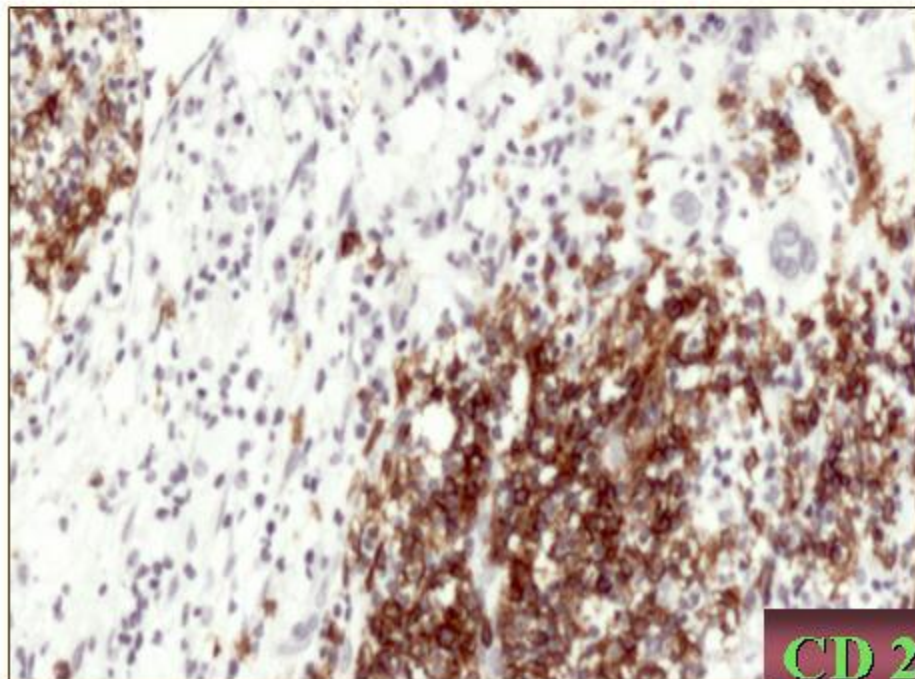




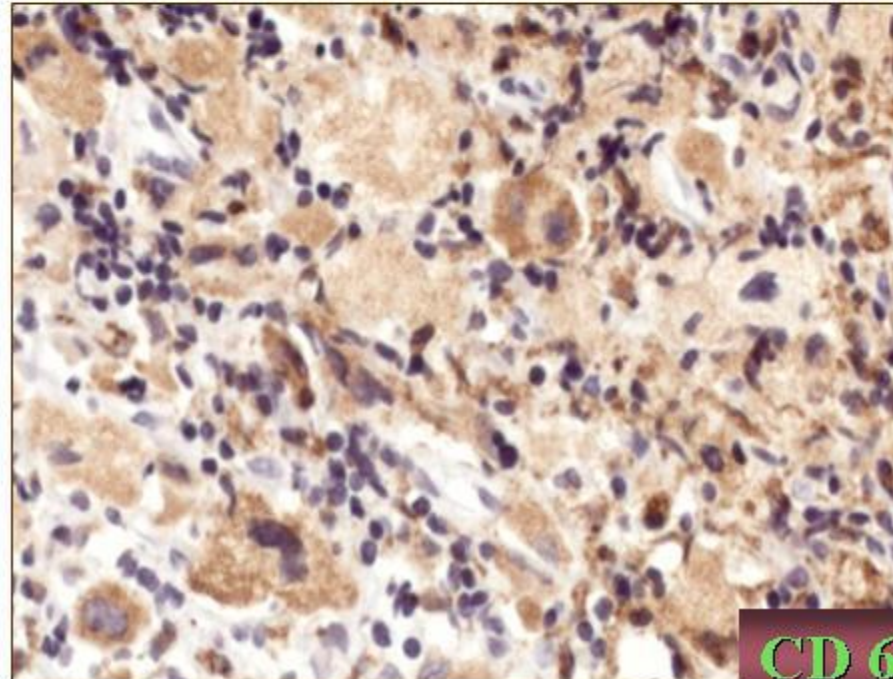
CD 3



Lysozym

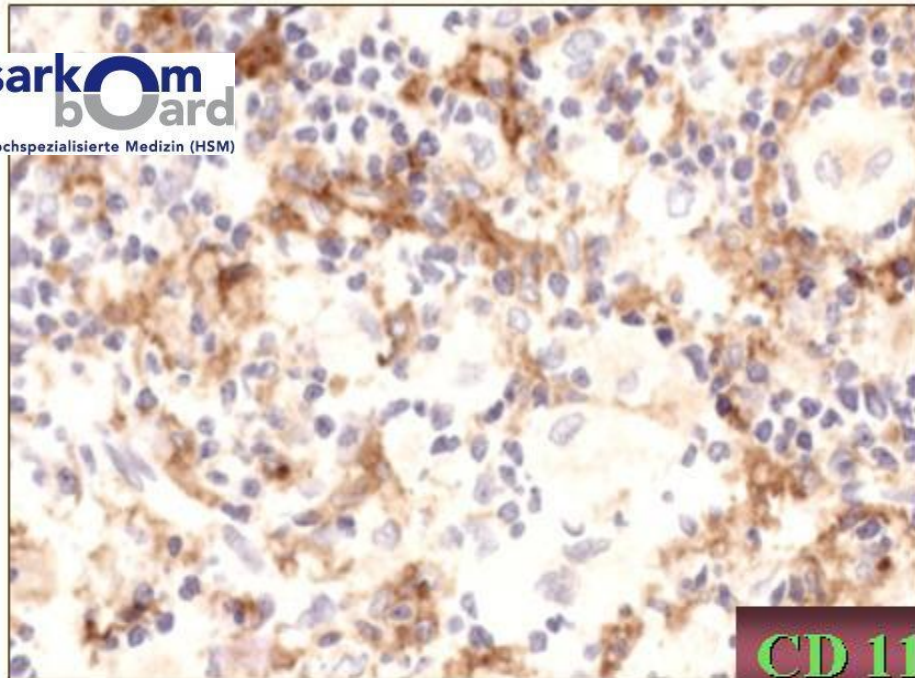


CD 20

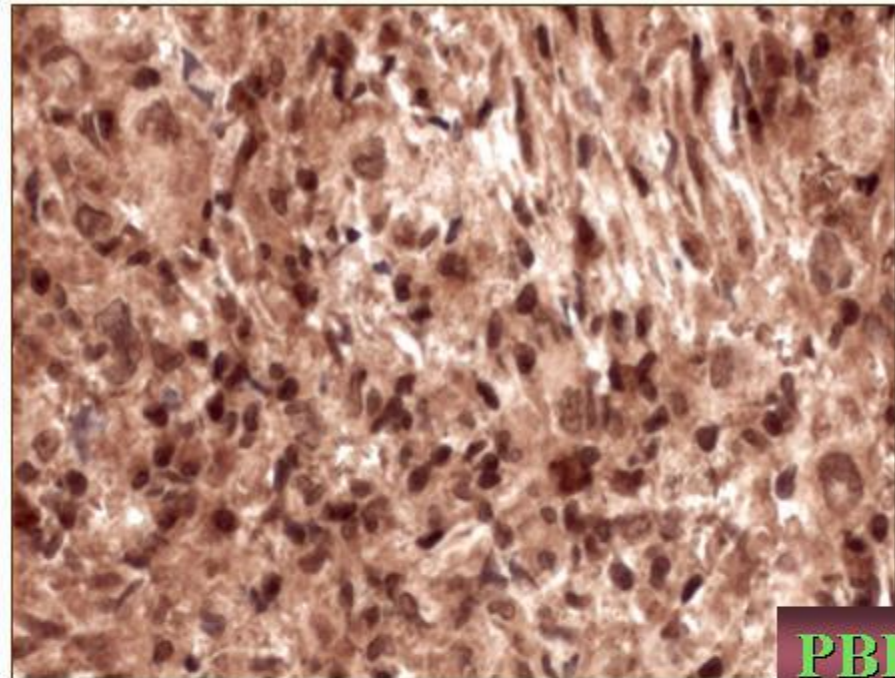


CD 68

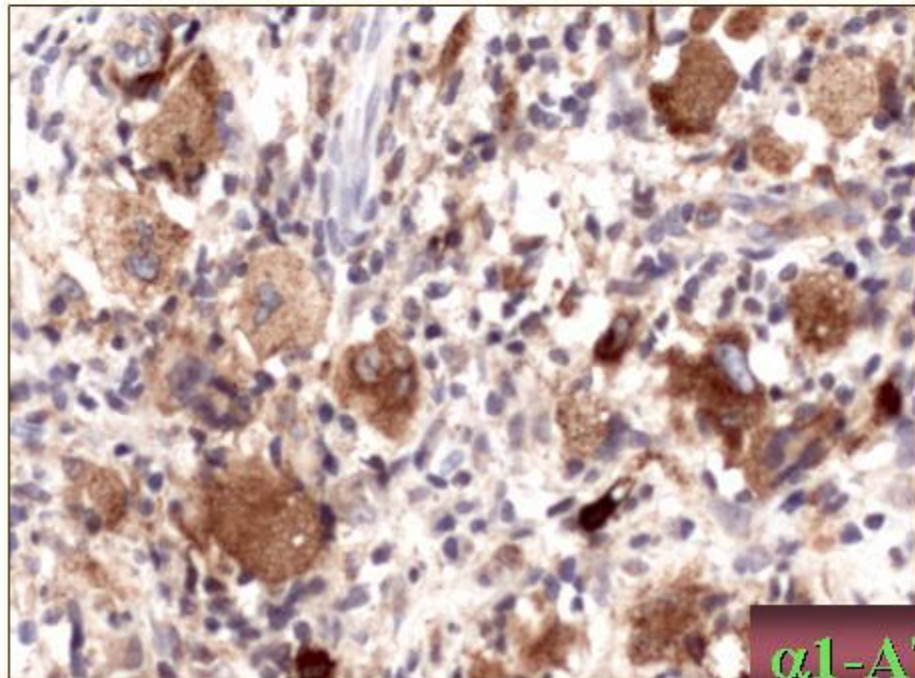




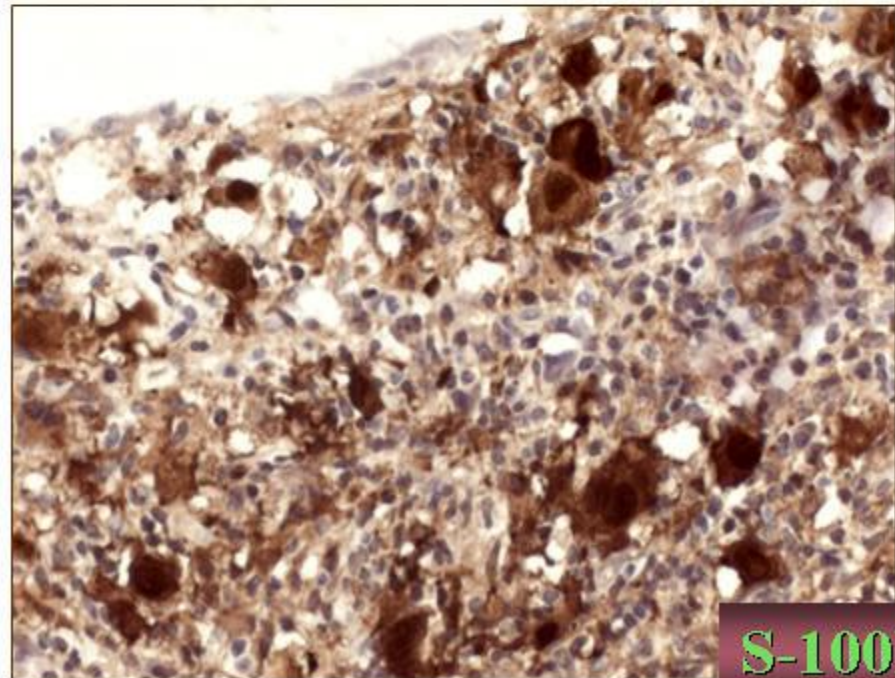
CD 11c



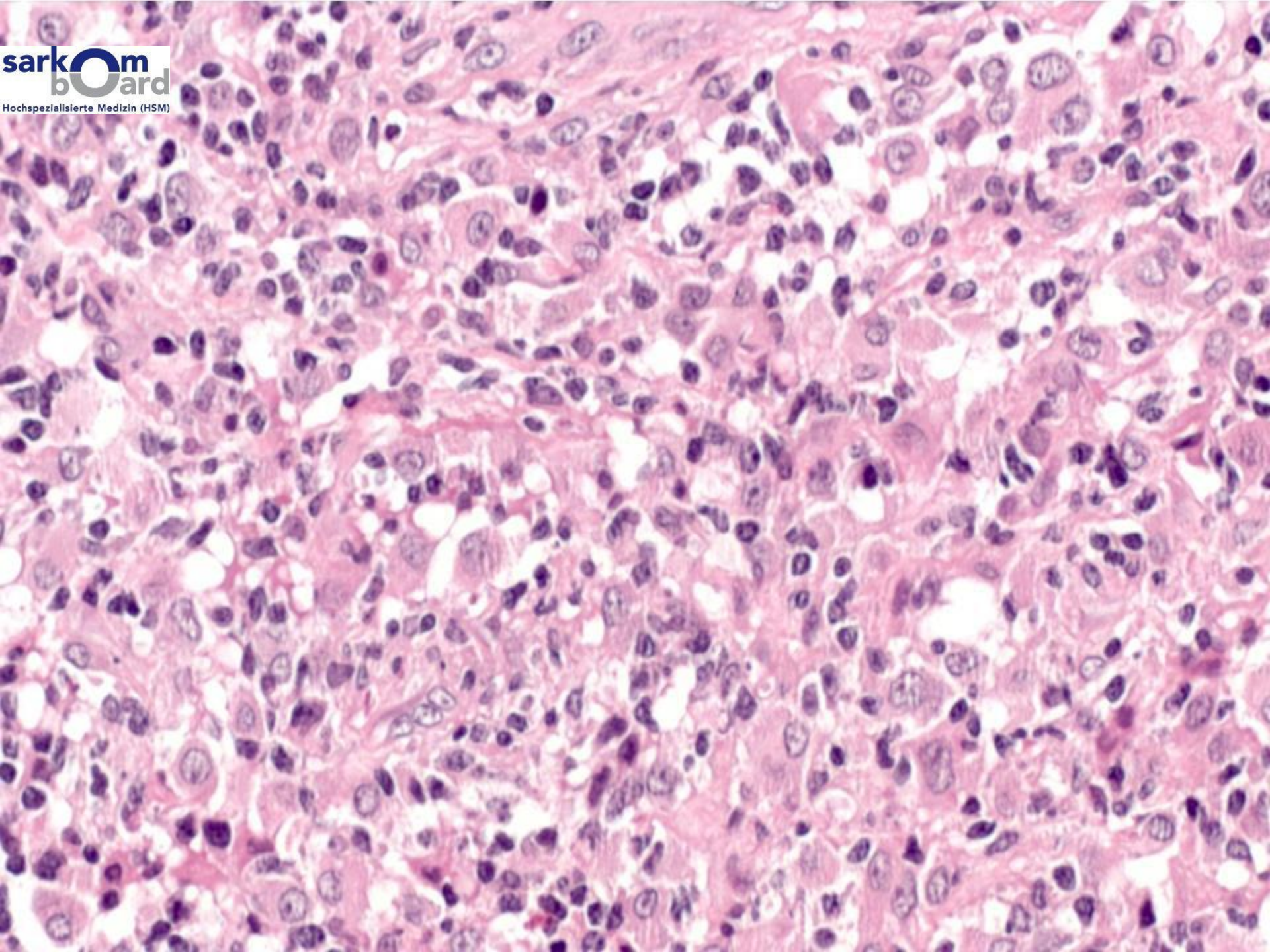
PBL

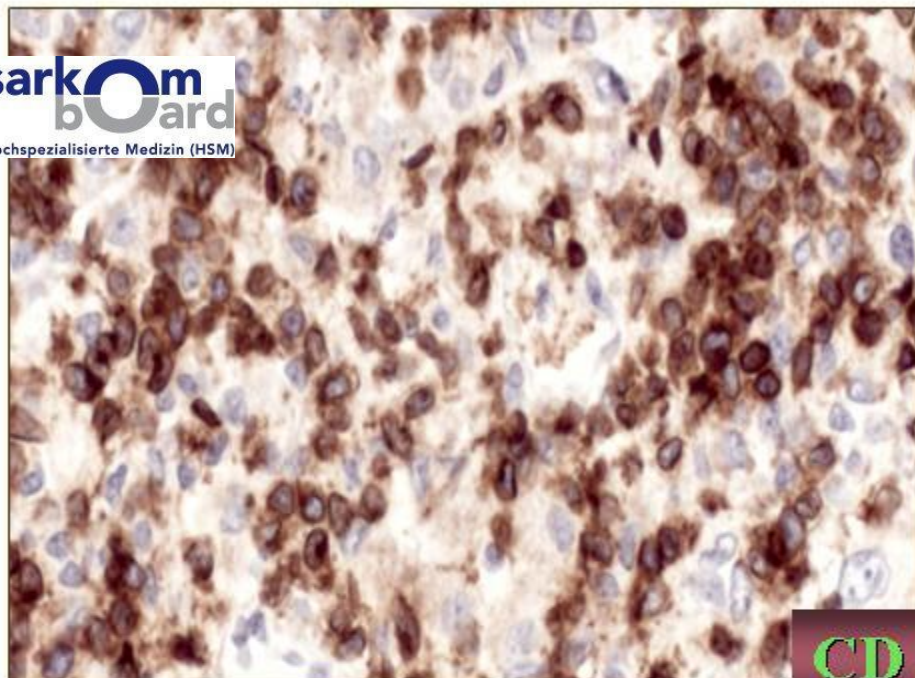


$\alpha$ 1-AT

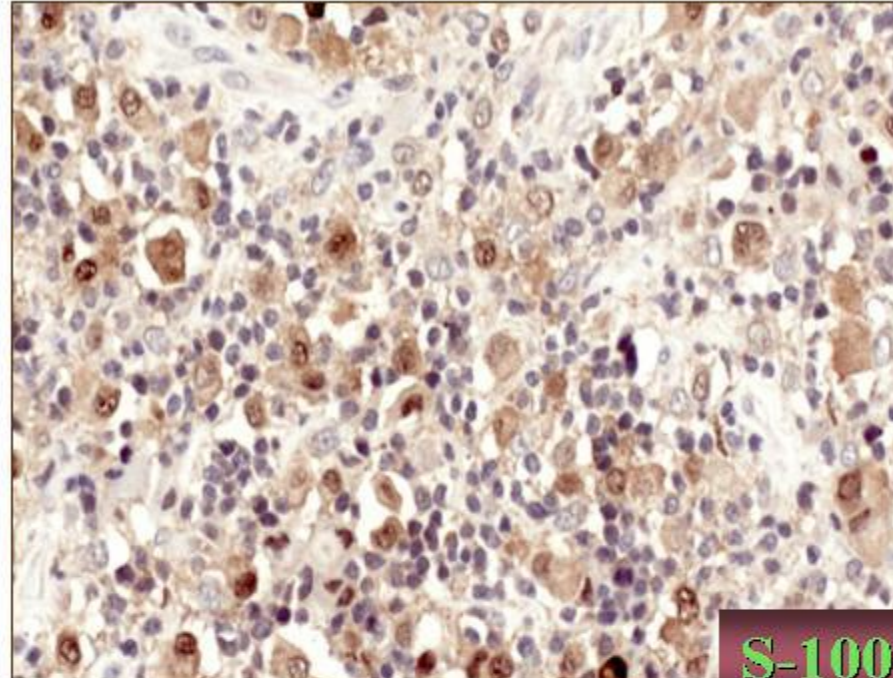


S-100P

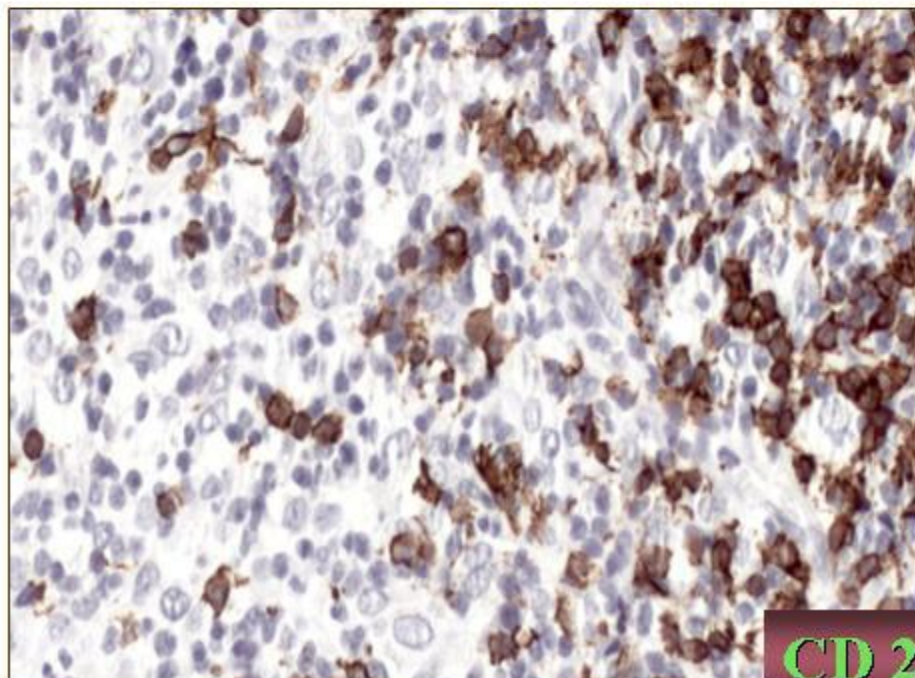




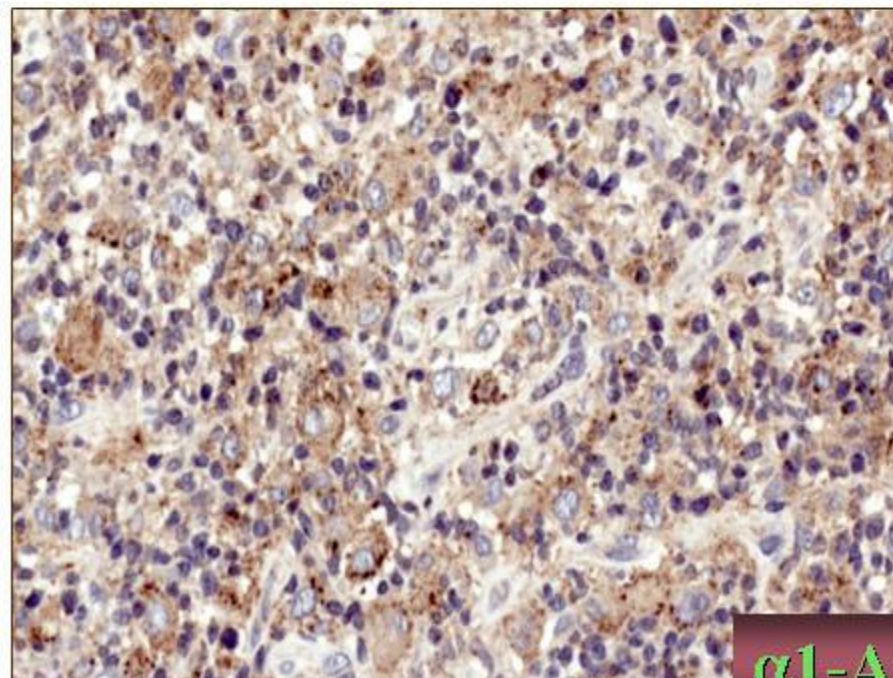
CD 3



S-100P

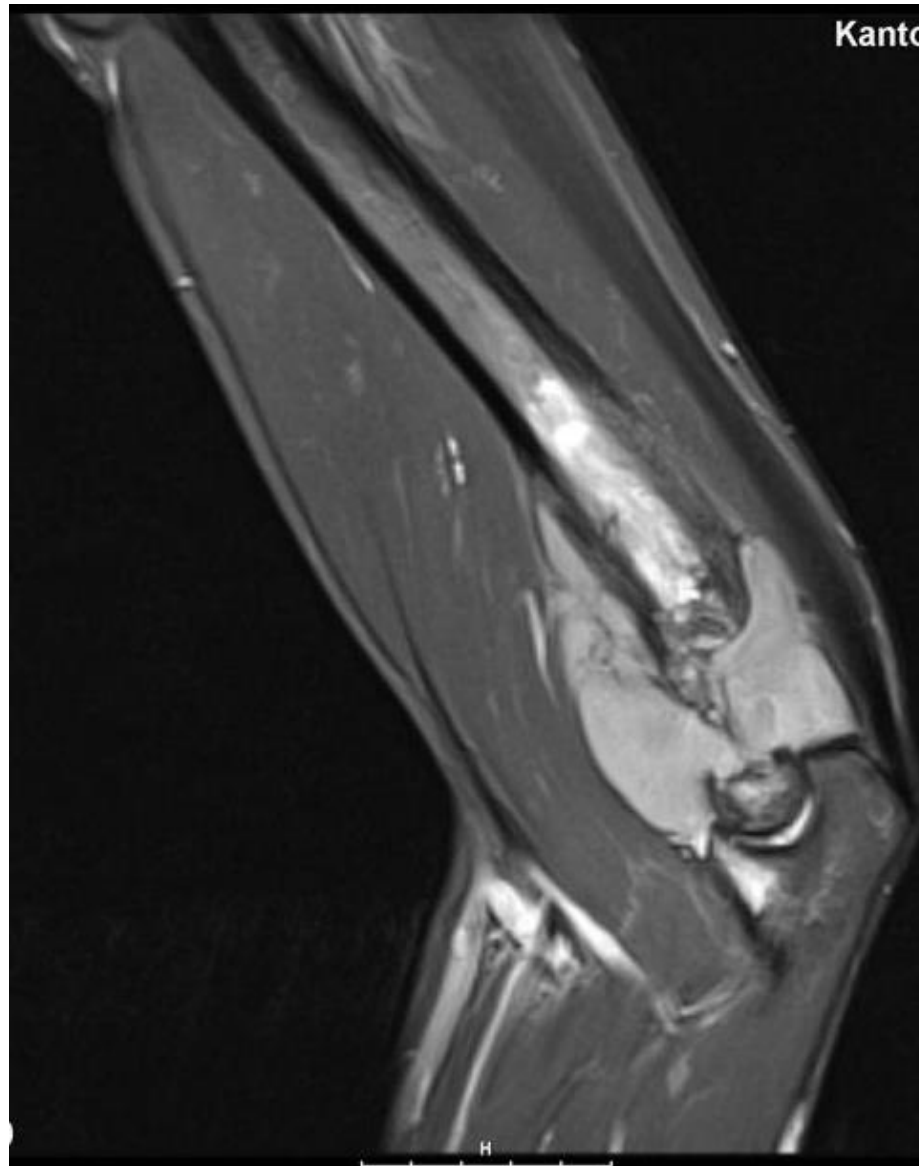


CD 20



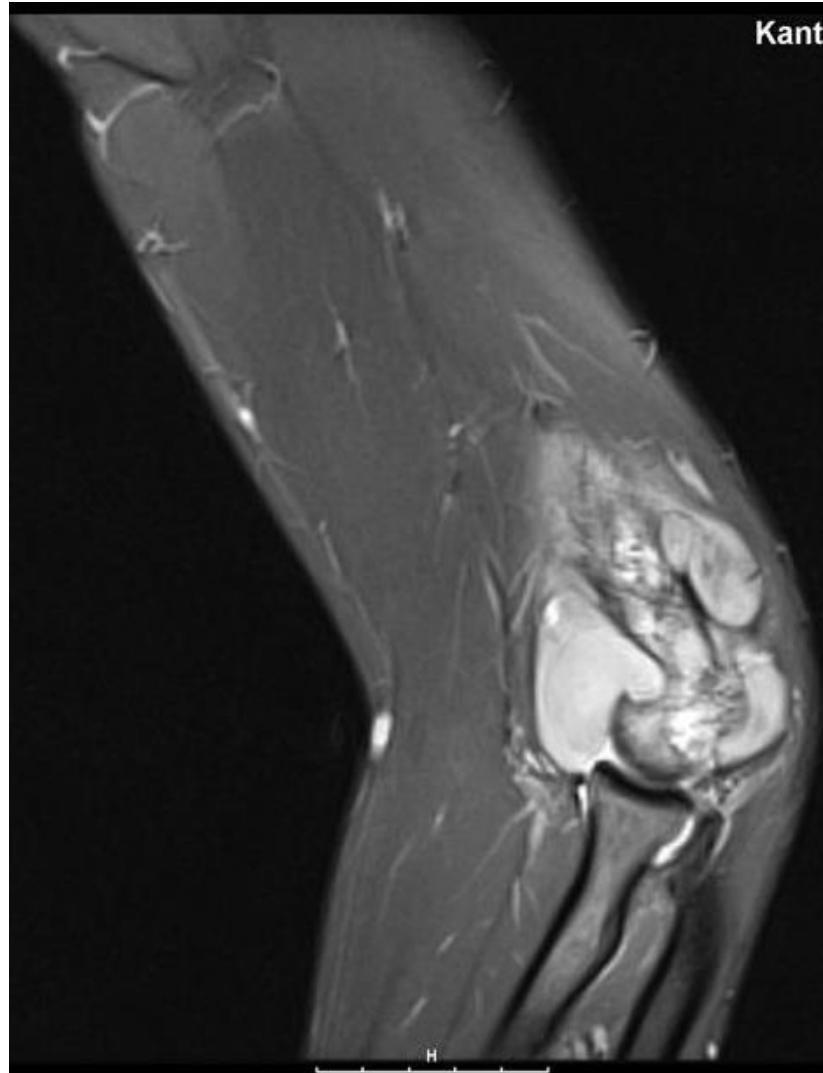
$\alpha$ 1-AT

# elbow; intercalary resection replantation MRI elbow: July 22nd, 2008



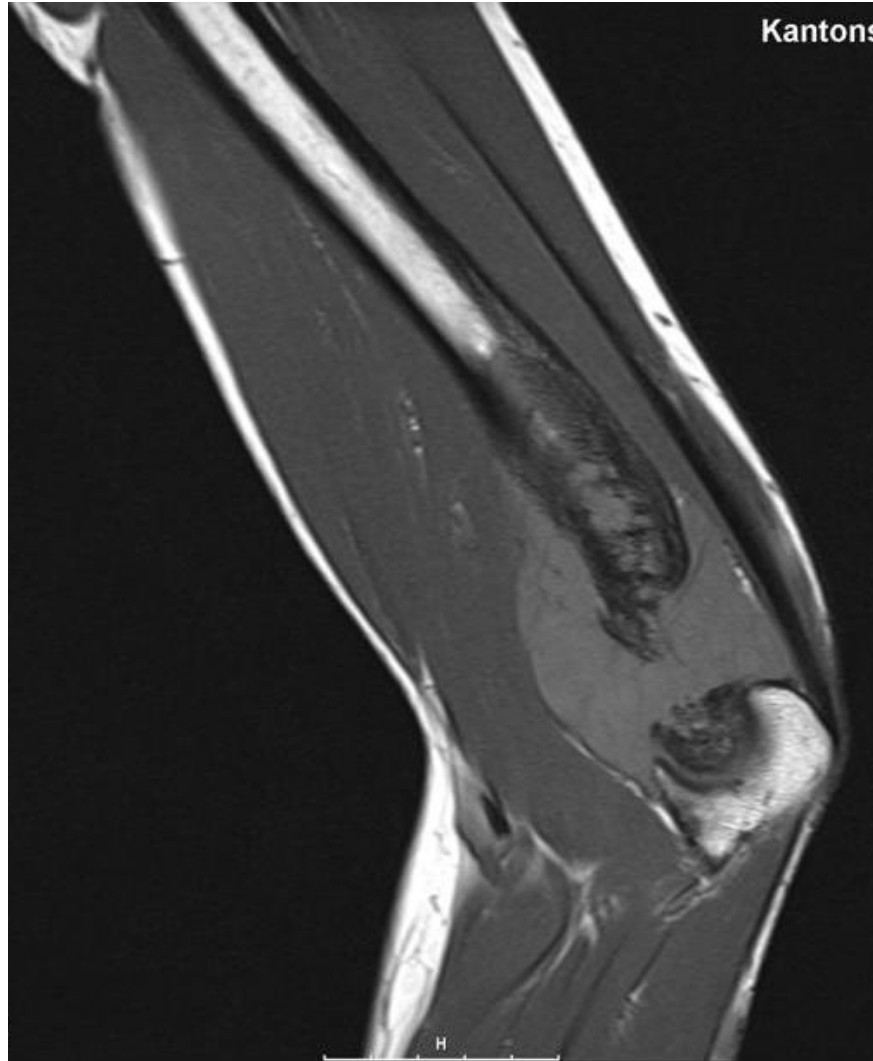
# elbow; intercalary resection replantation

## MRI elbow: July 22nd, 2008



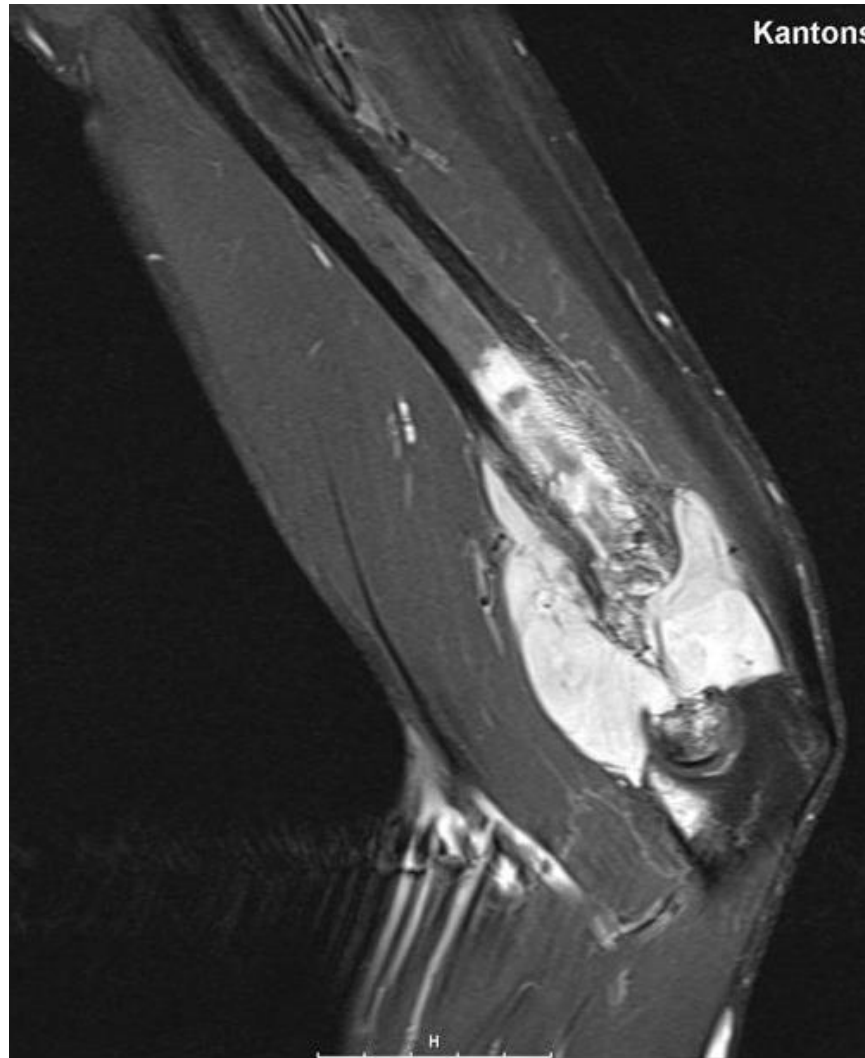
# elbow; intercalary resection replantation

## MRI elbow: July 22nd, 2008

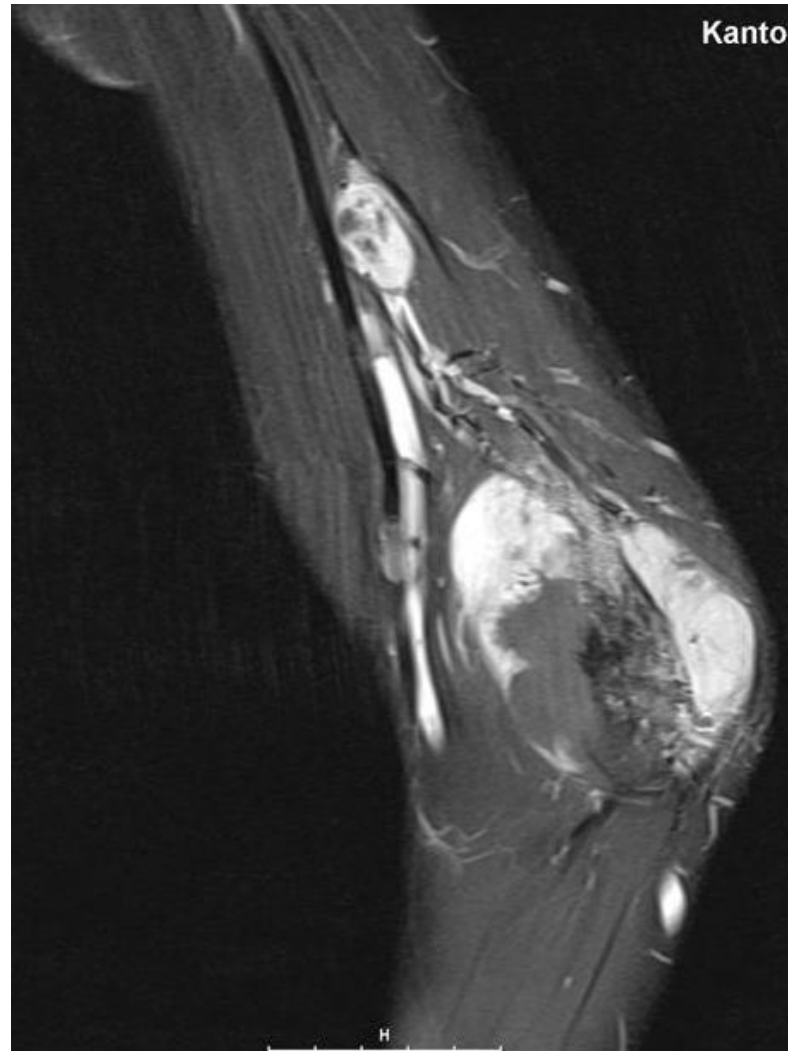


# elbow; intercalary resection replantation

## MRI elbow: July 22nd, 2008

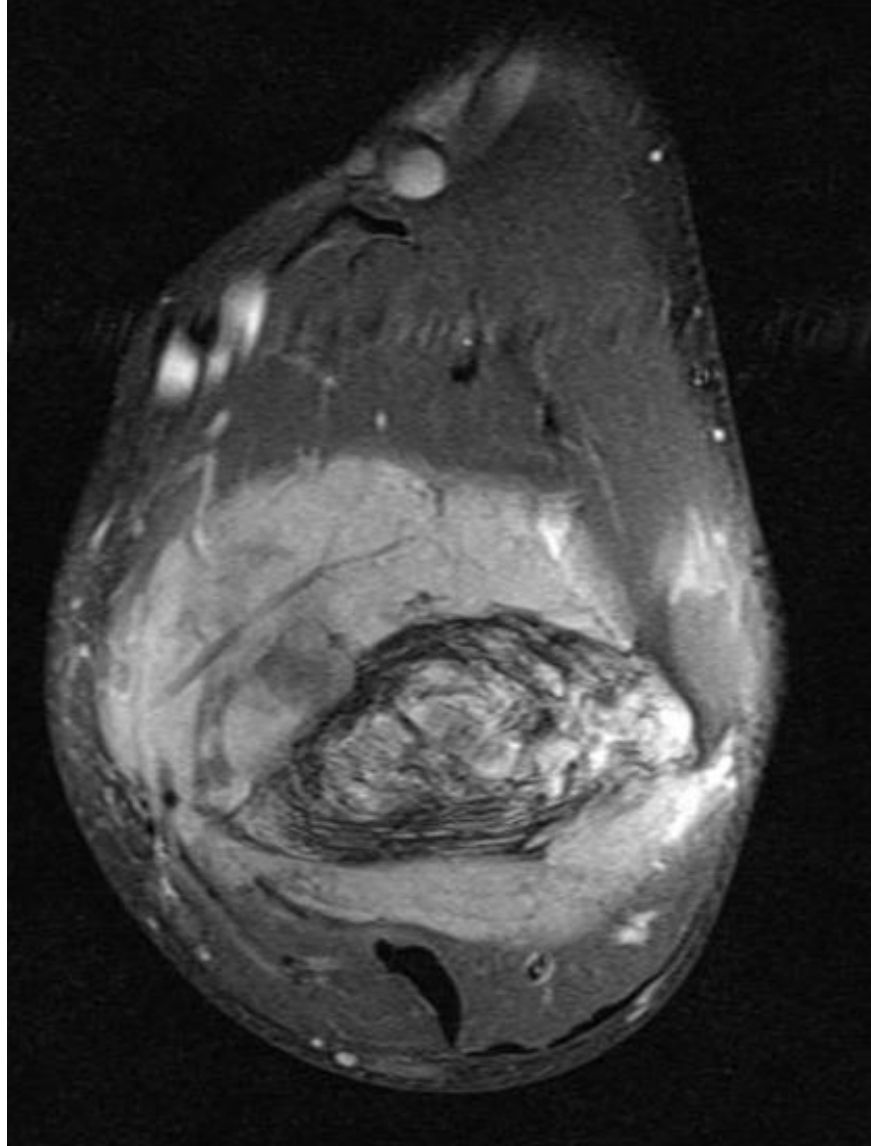


# elbow; intercalary resection replantation MRI elbow, July 22nd, 2008





# elbow; intercalary resection replantation MRI elbow, July 22nd, 2008



# Biopsie Juli 2008

Klinische Angaben:

St.n. B-ALL 1992. Ossäre Sinushistiozytose Typ Rosai-Dorfman.

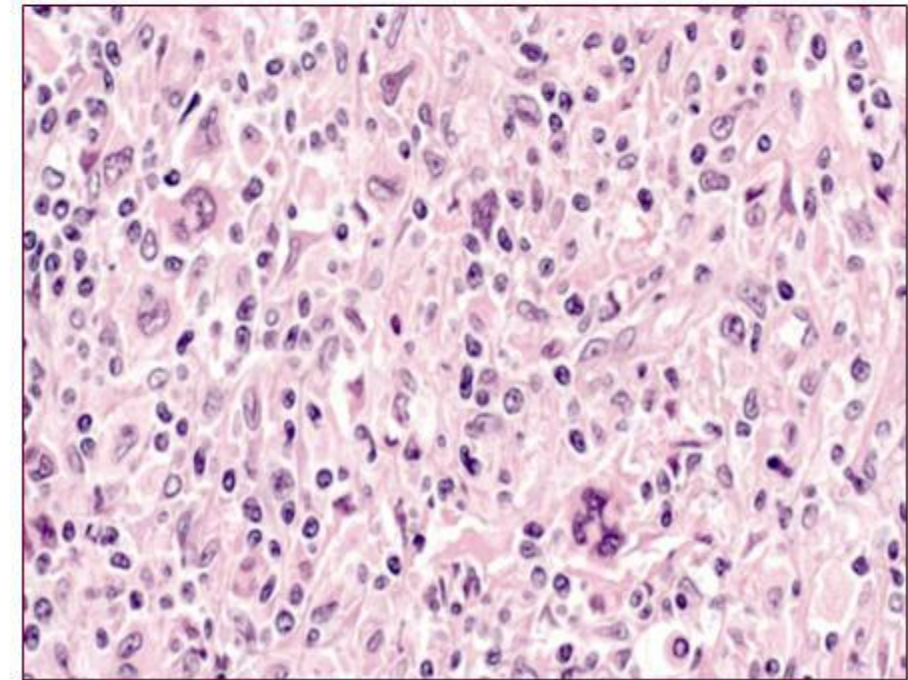
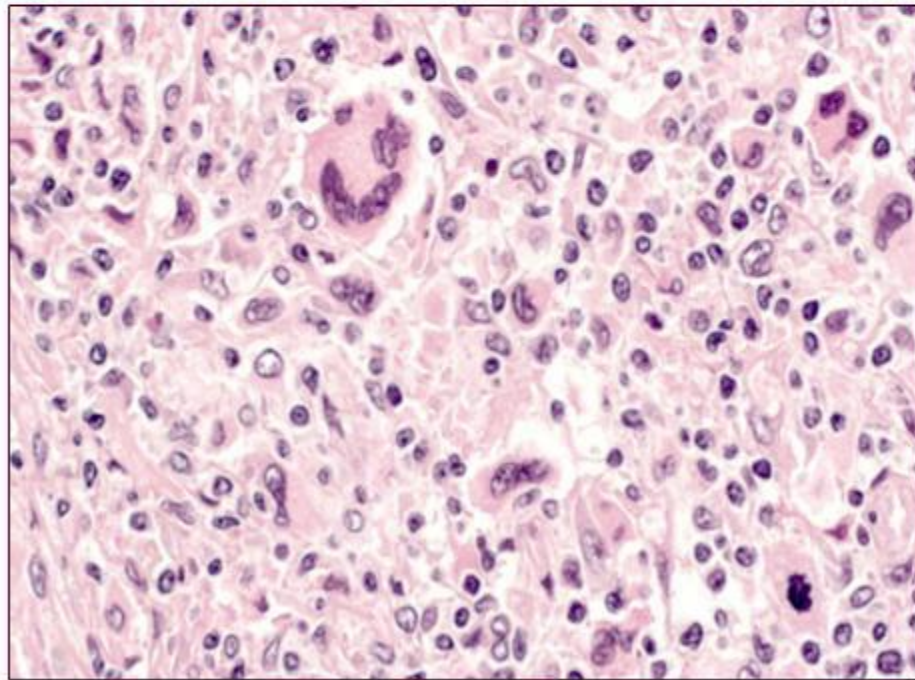
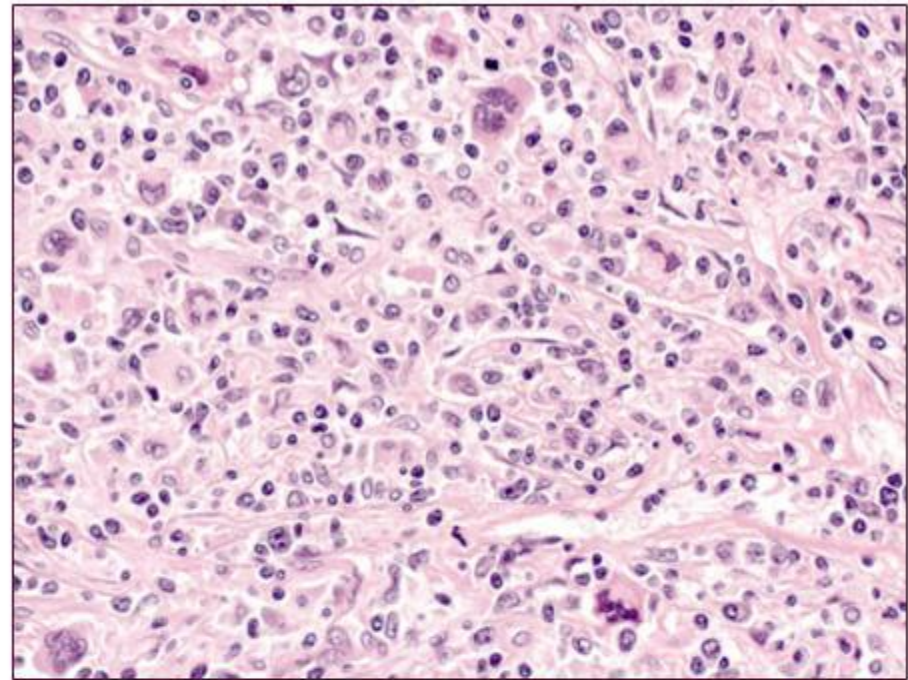
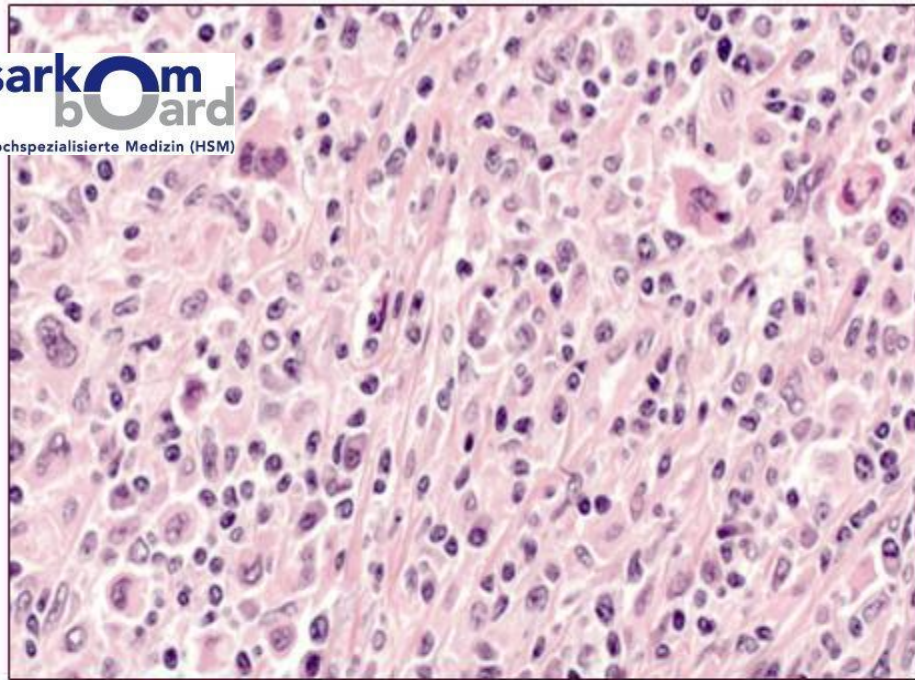
Weichteiltumor rechte ventrale Schulter. Frage nach Histiozytose?

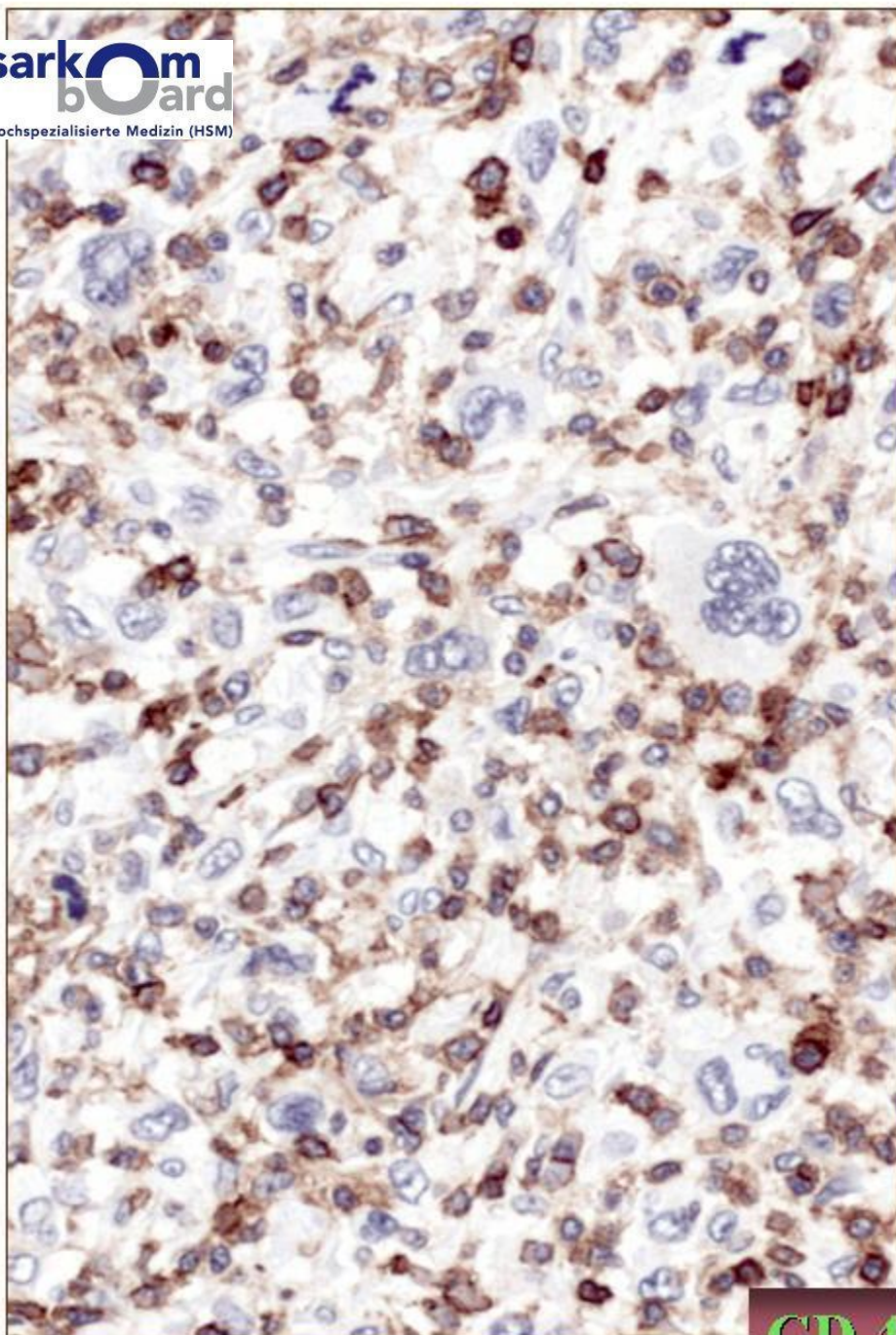
Pathologisch-anatomische Diagnose:

Stark vergrößerter rechts axillärer LK mit ausgeprägter histiozytärer Infiltration vereinbar mit Rosai-Dorfman

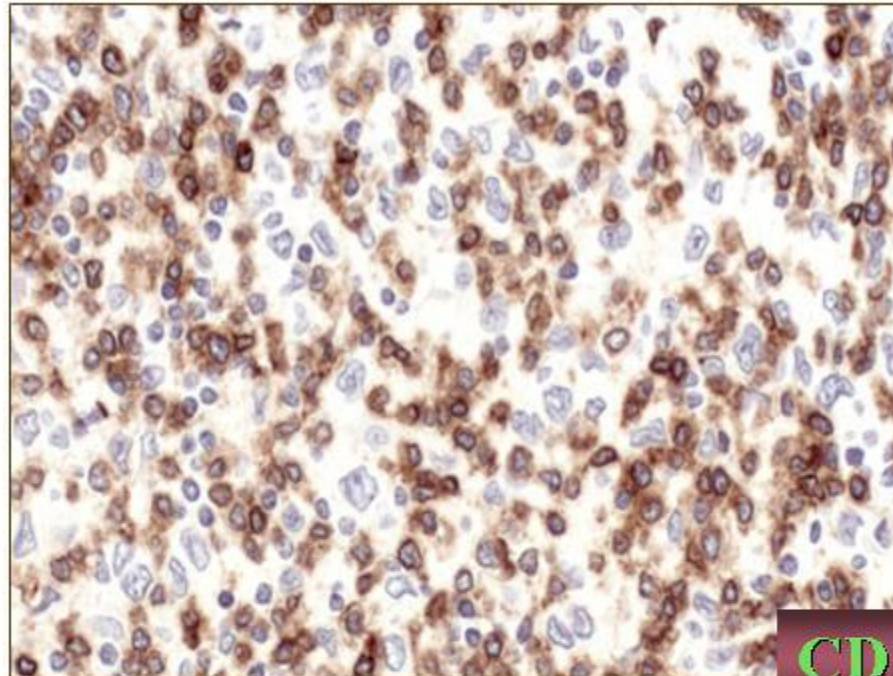
2. pathol.-anatomische Begutachtung

histiozytäre Läsion, ebenfalls als nicht-neoplastisch beurteilt, jedoch Kriterien eines Rosai Dorfman nicht vollständig erfüllt (bei strikter Definition der Kriterien)

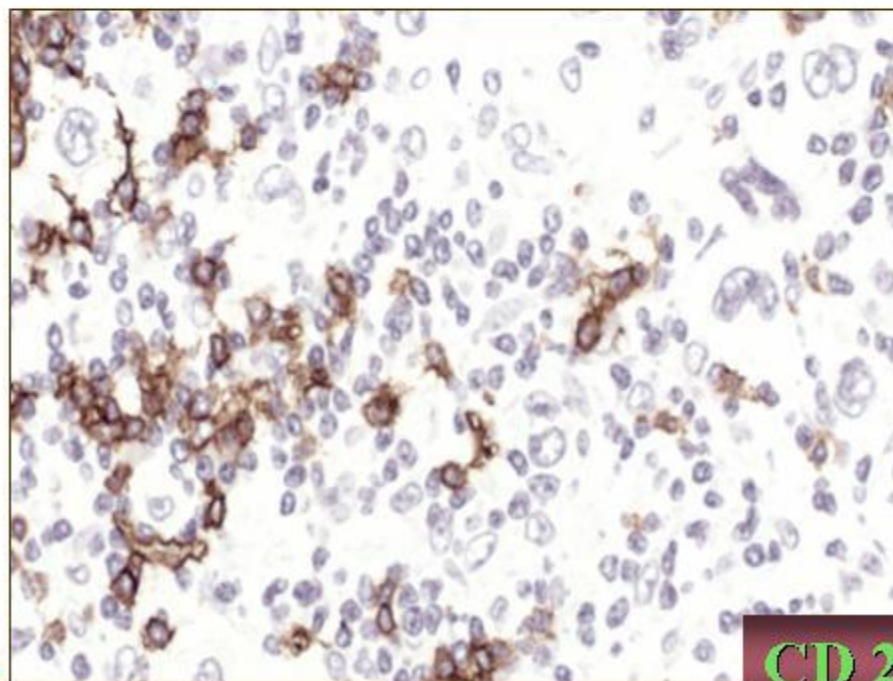




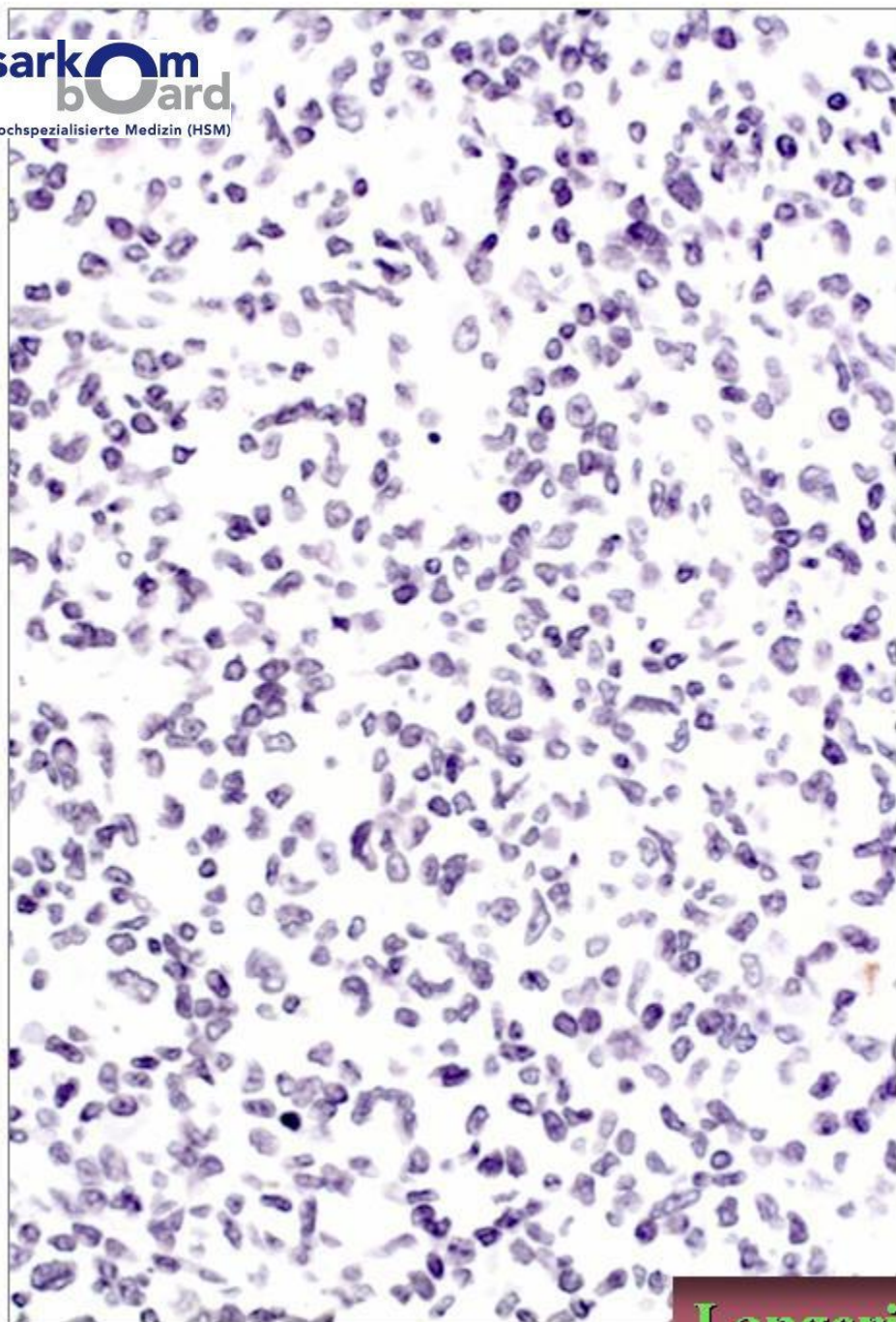
CD 45



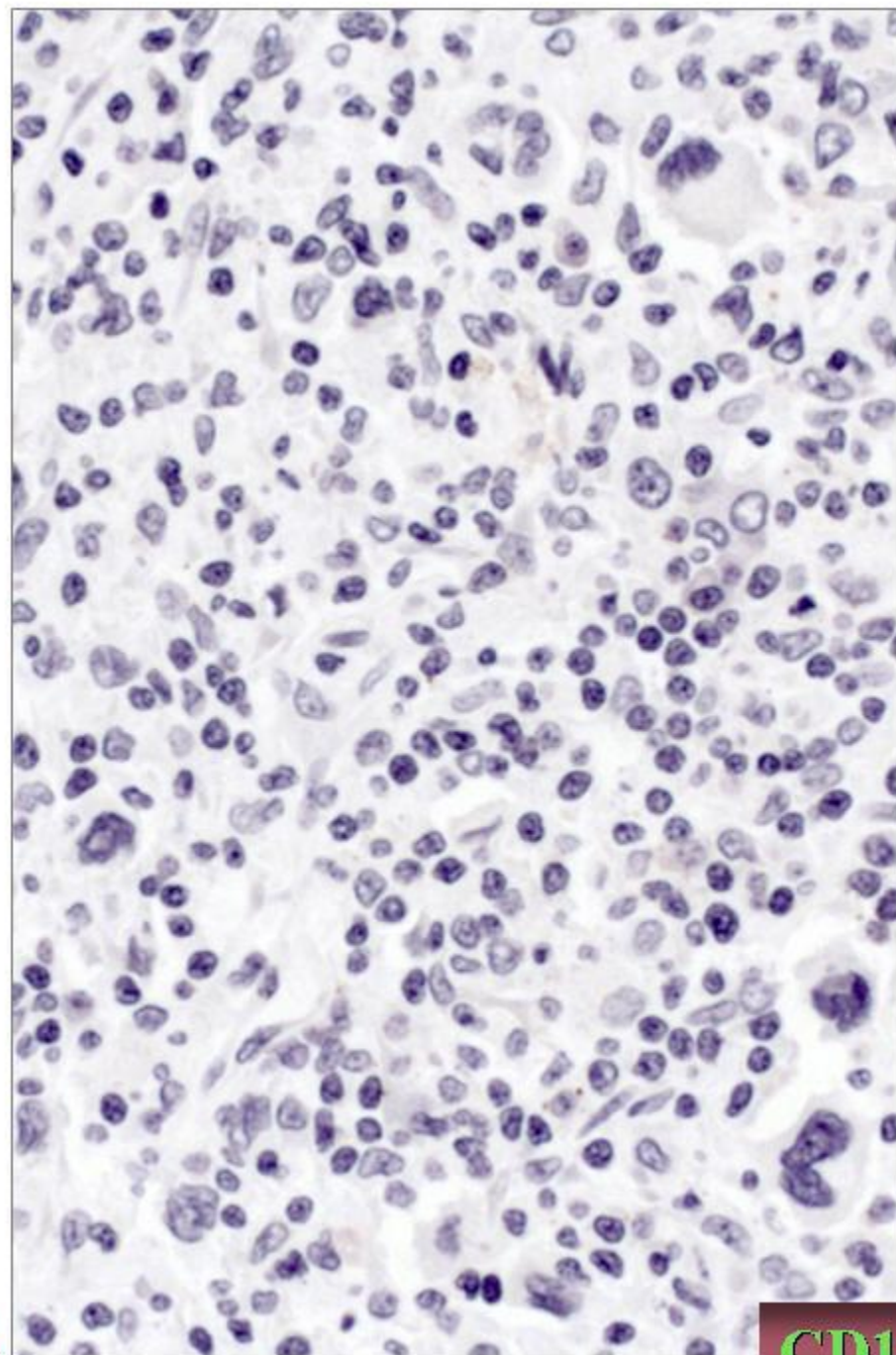
CD 3



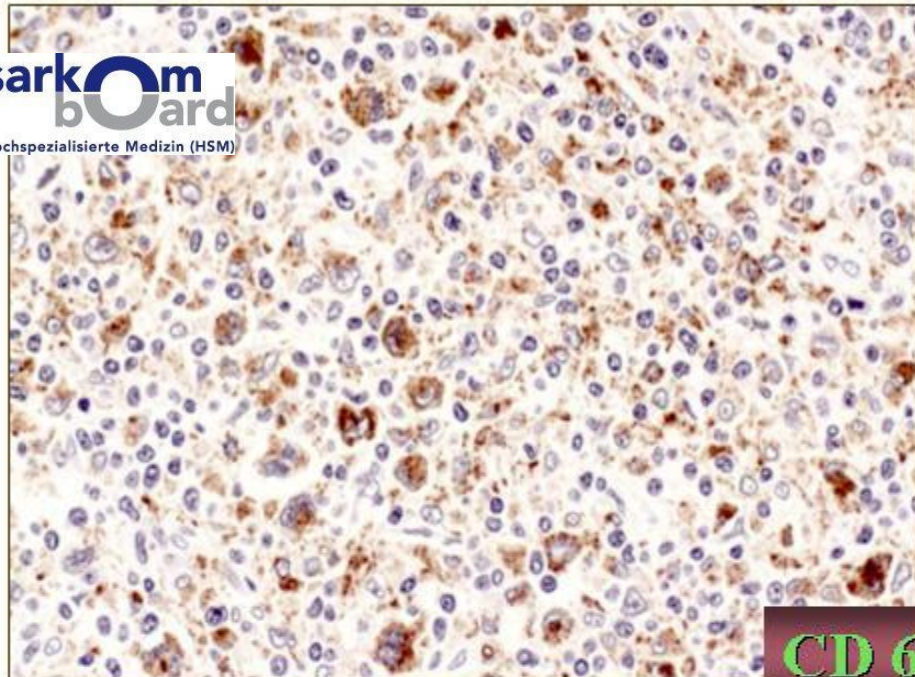
CD 20



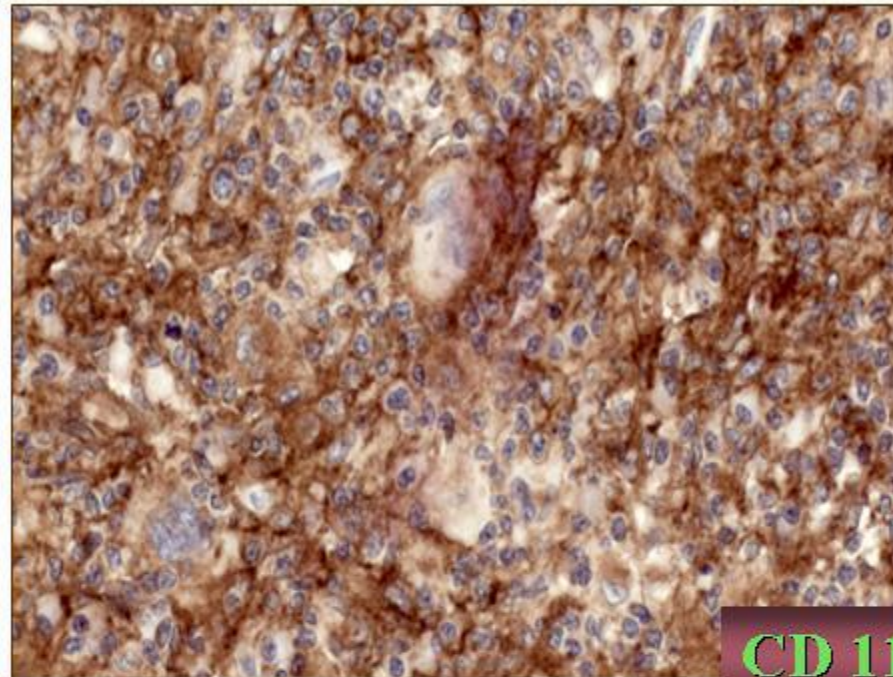
Langerin



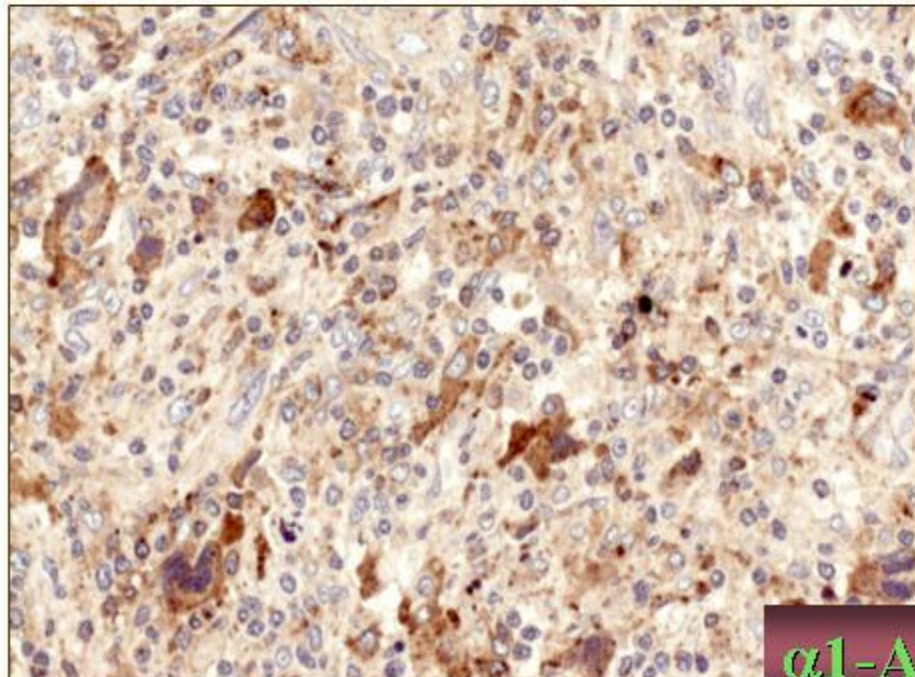
CD1a



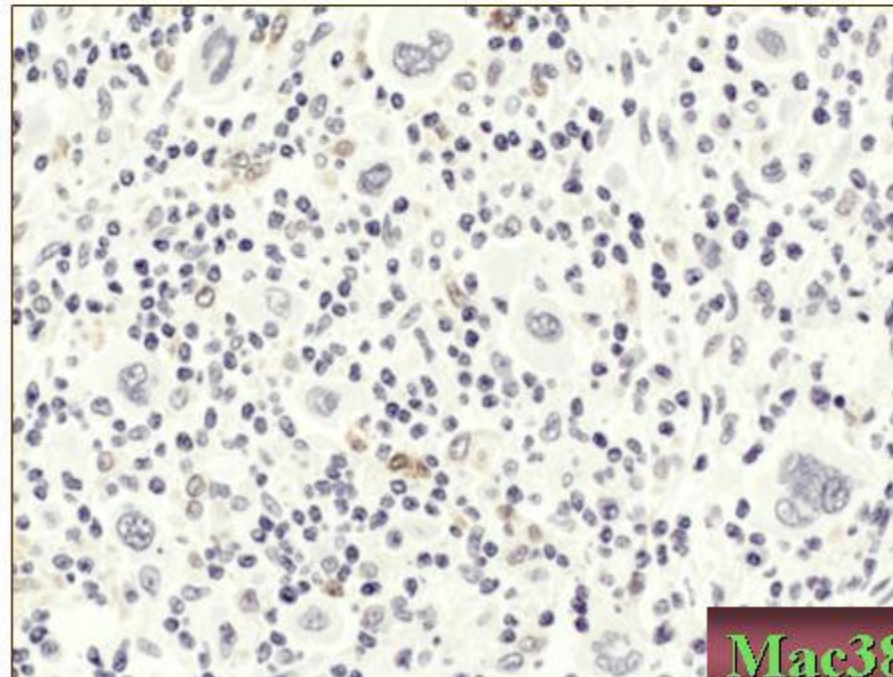
CD 68



CD 11c

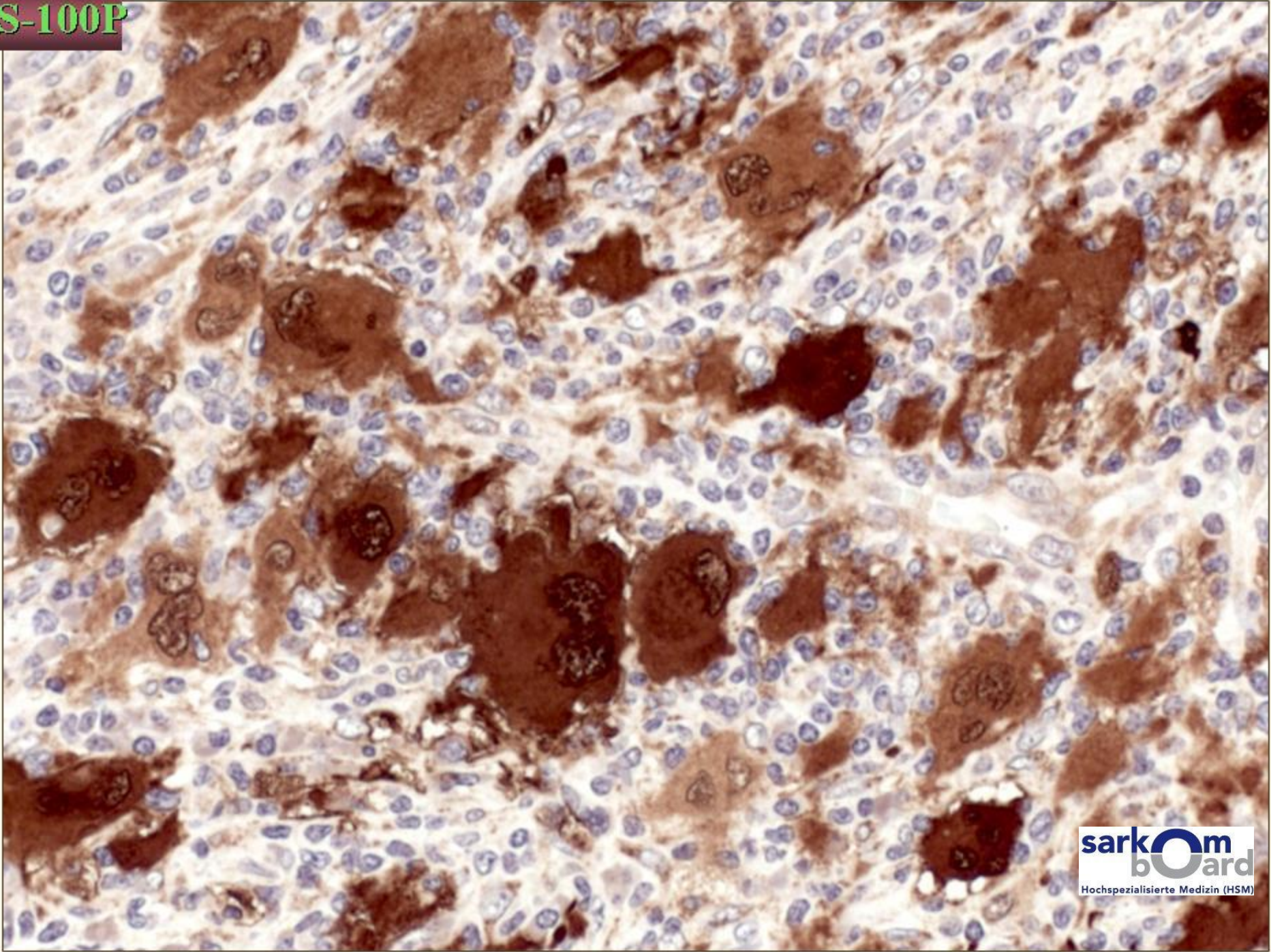


$\alpha$ 1-AT



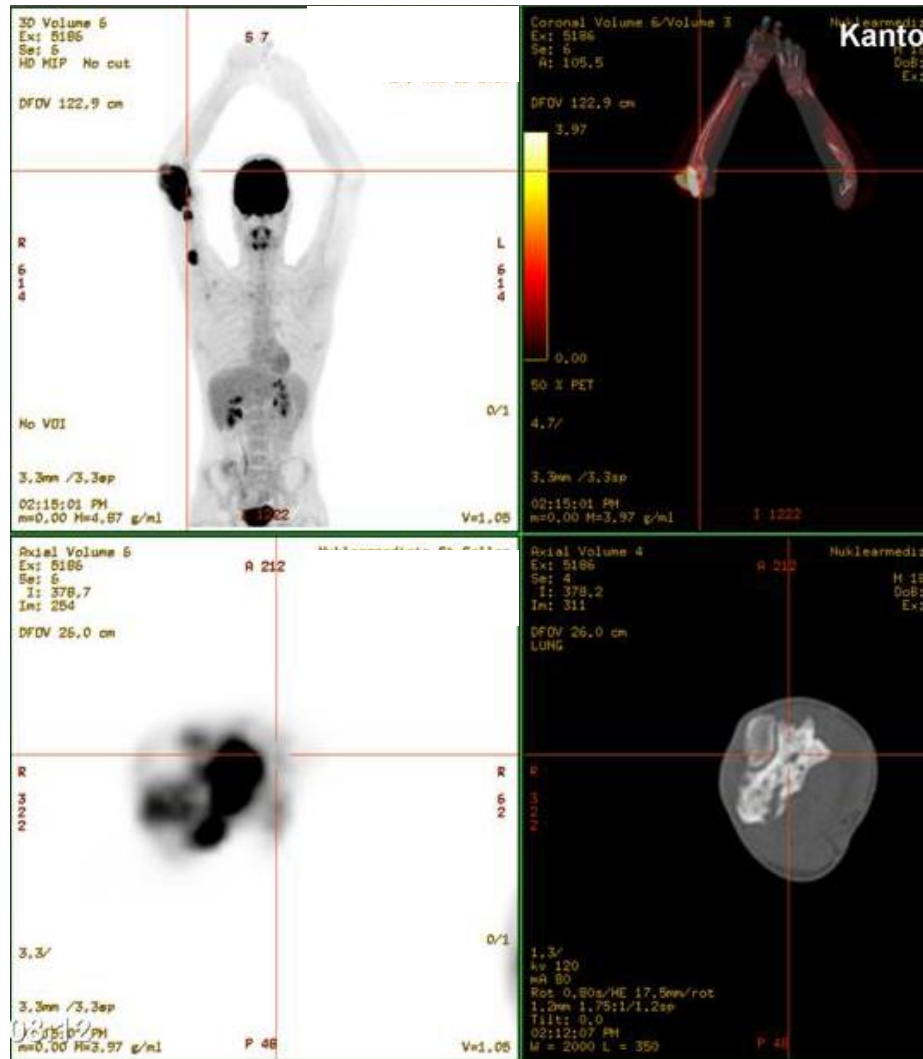
Mac387

S-100P



# elbow; intercalary resection replantation

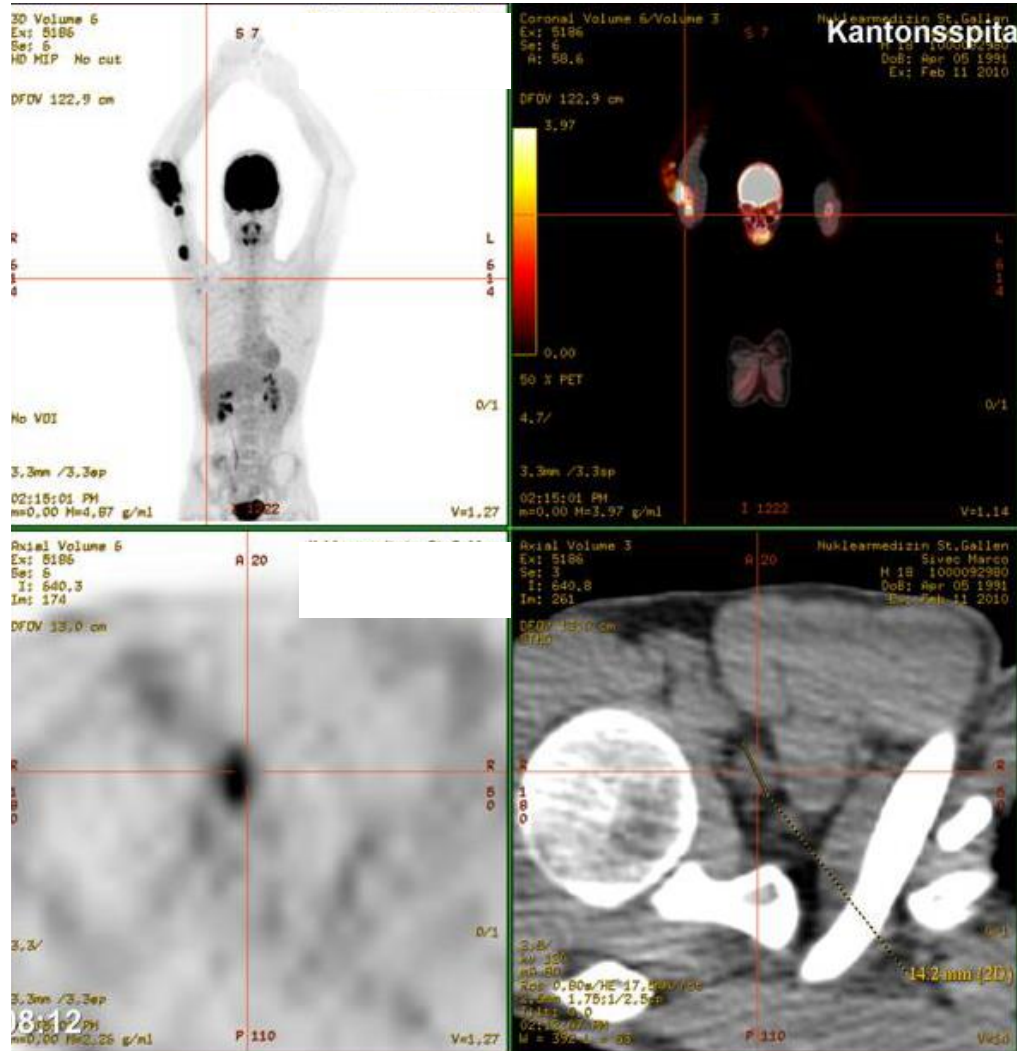
## PET CT: February 11th, 2010





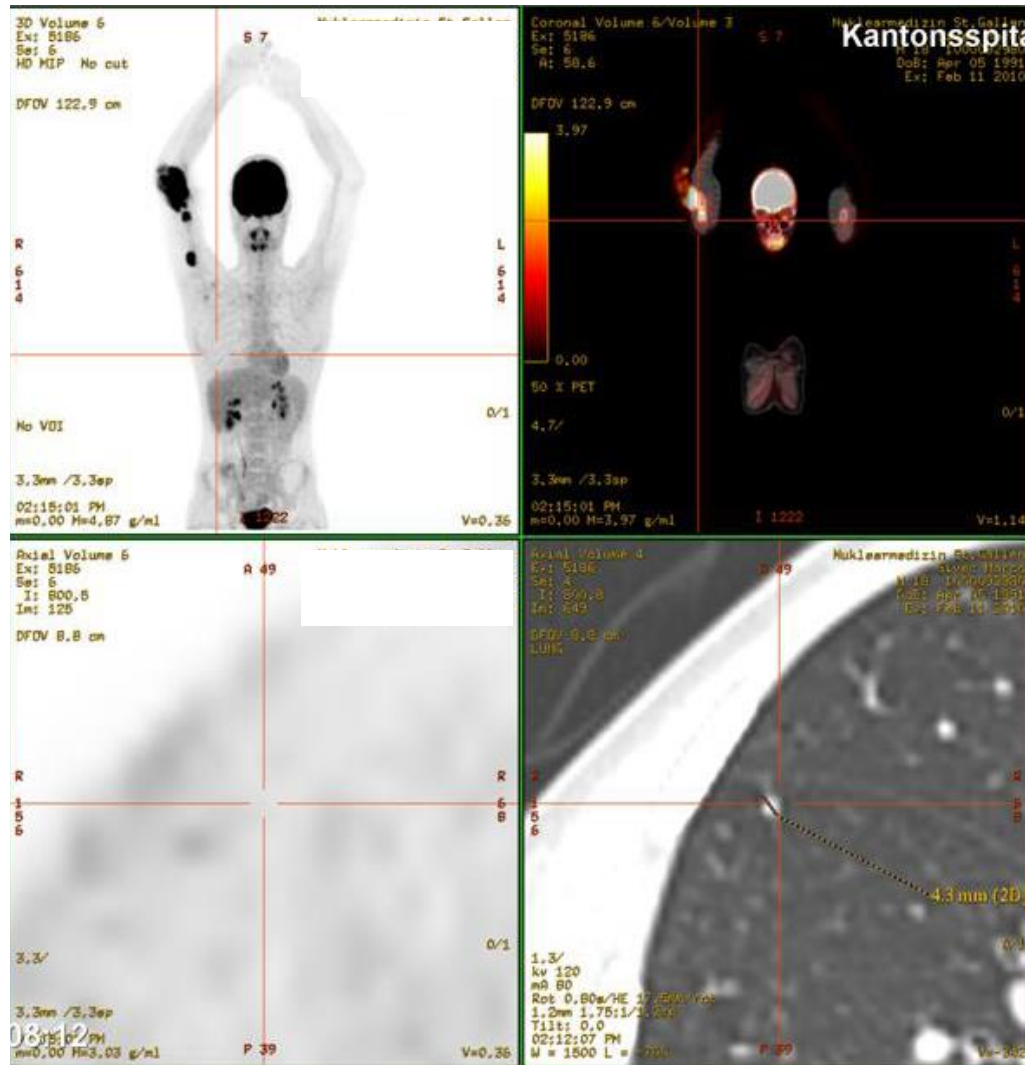
# elbow; intercalary resection replantation

## PET CT: February 11th, 2010



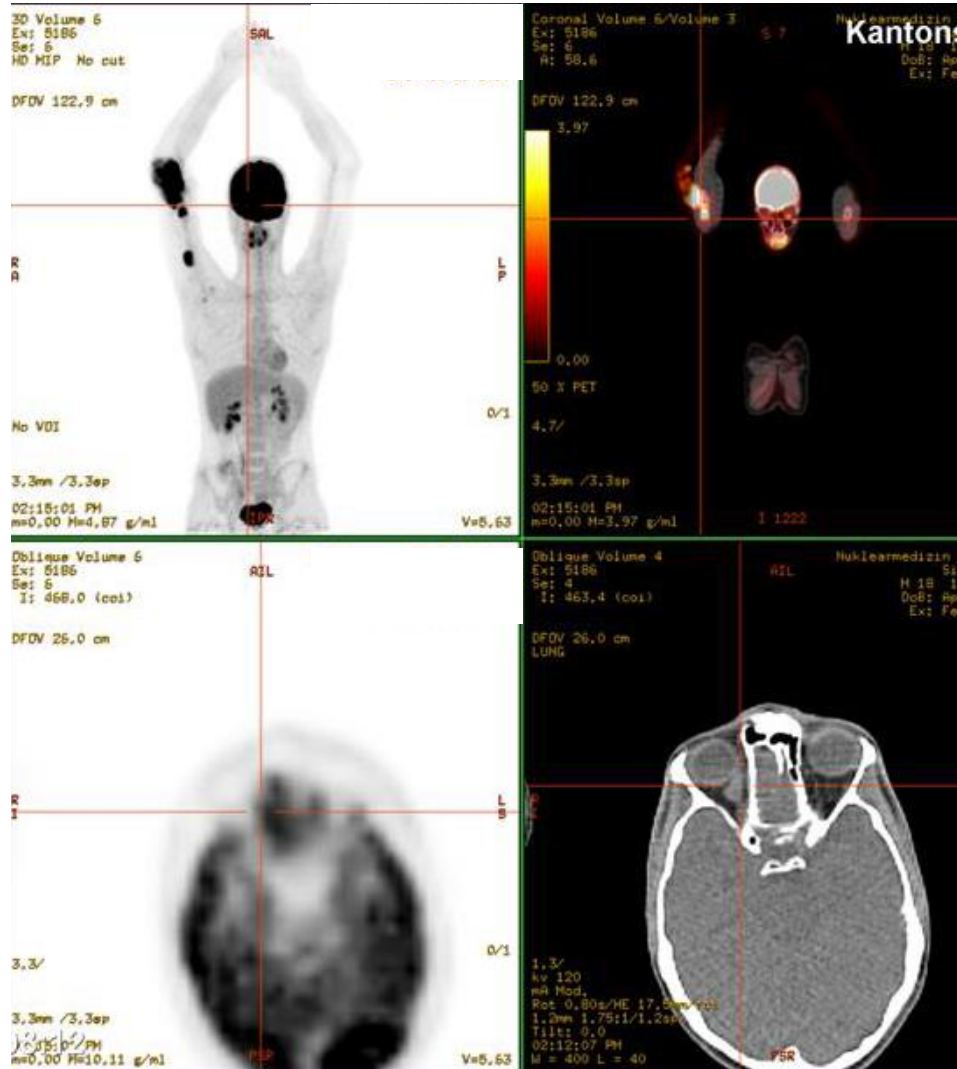# elbow; intercalary resection replantation

## PET CT: February 11th, 2010



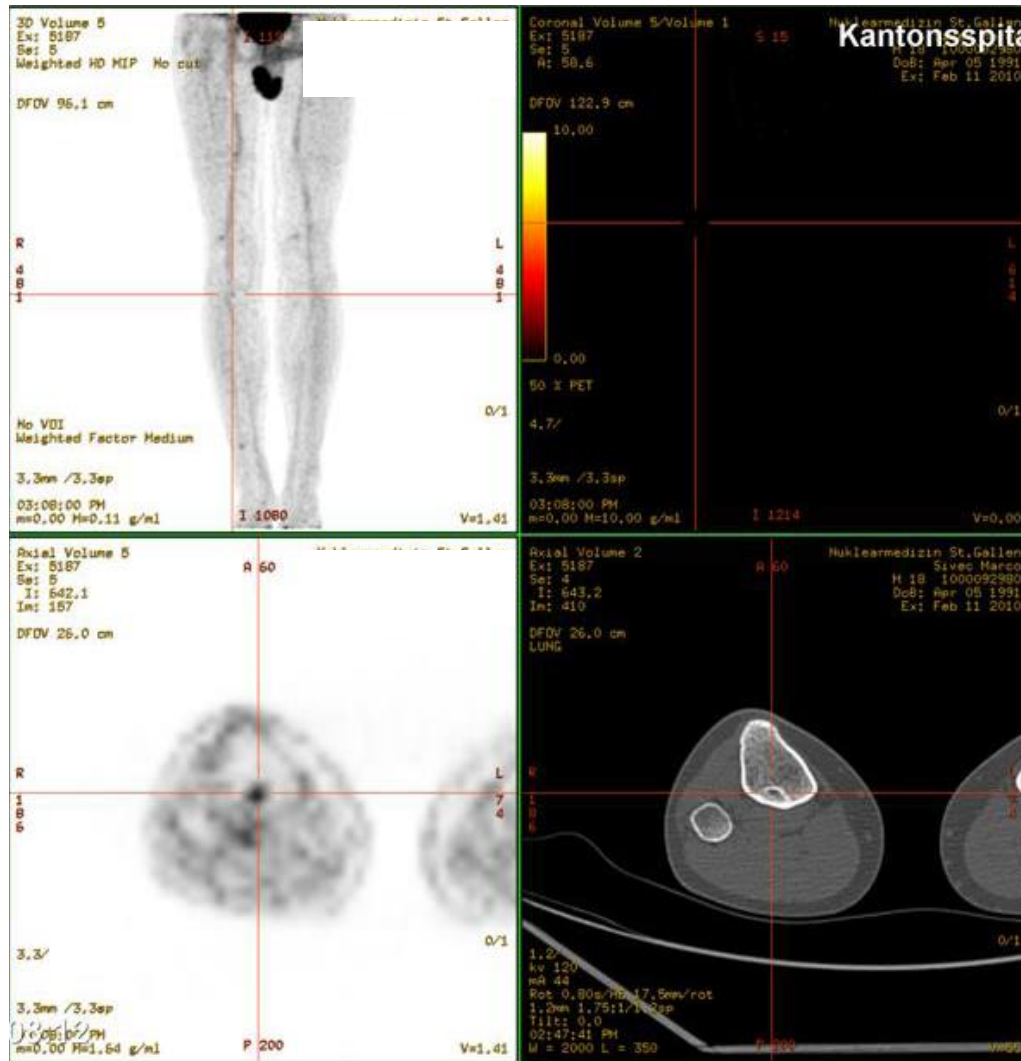
# elbow; intercalary resection replantation

## PET CT: February 11th, 2010



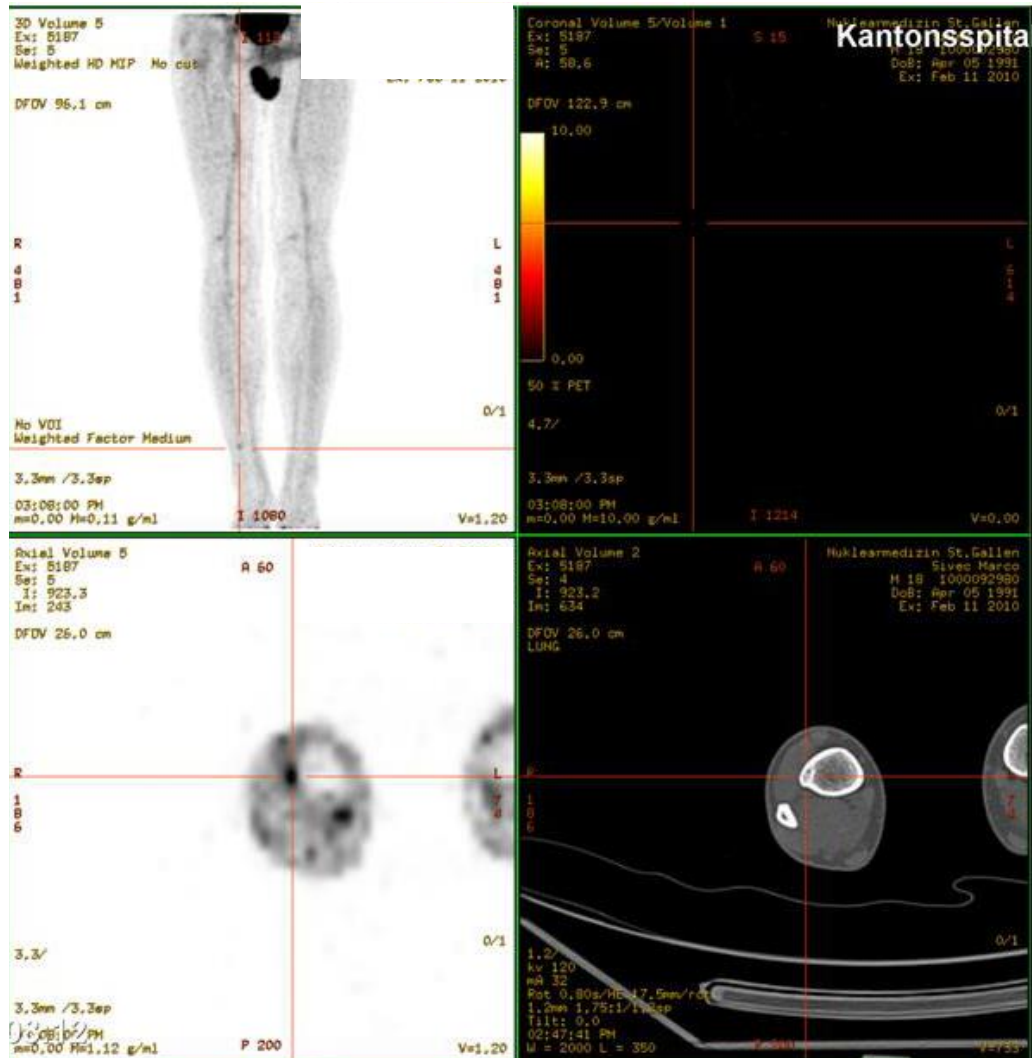
# elbow; intercalary resection replantation

## PET CT: February 11th, 2010



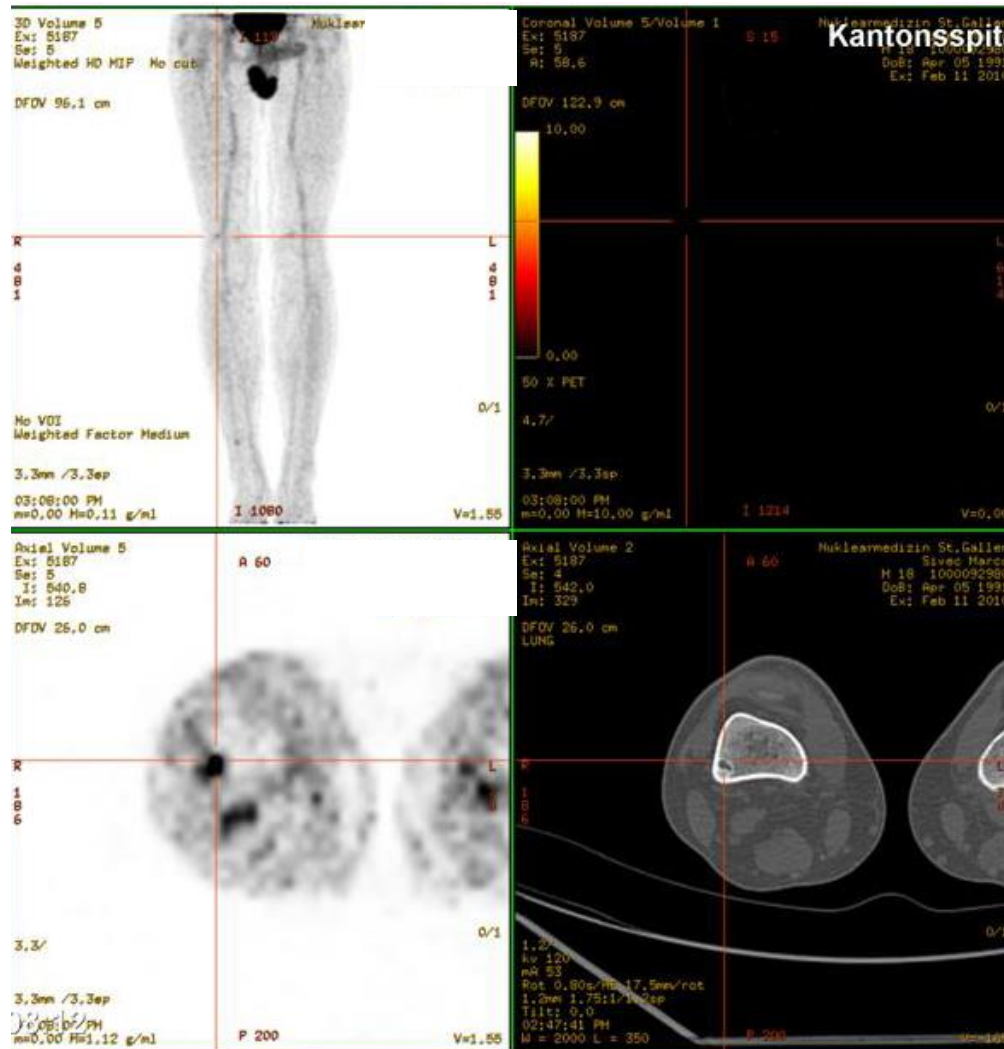
# elbow; intercalary resection replantation

## PET CT: February 11th, 2010



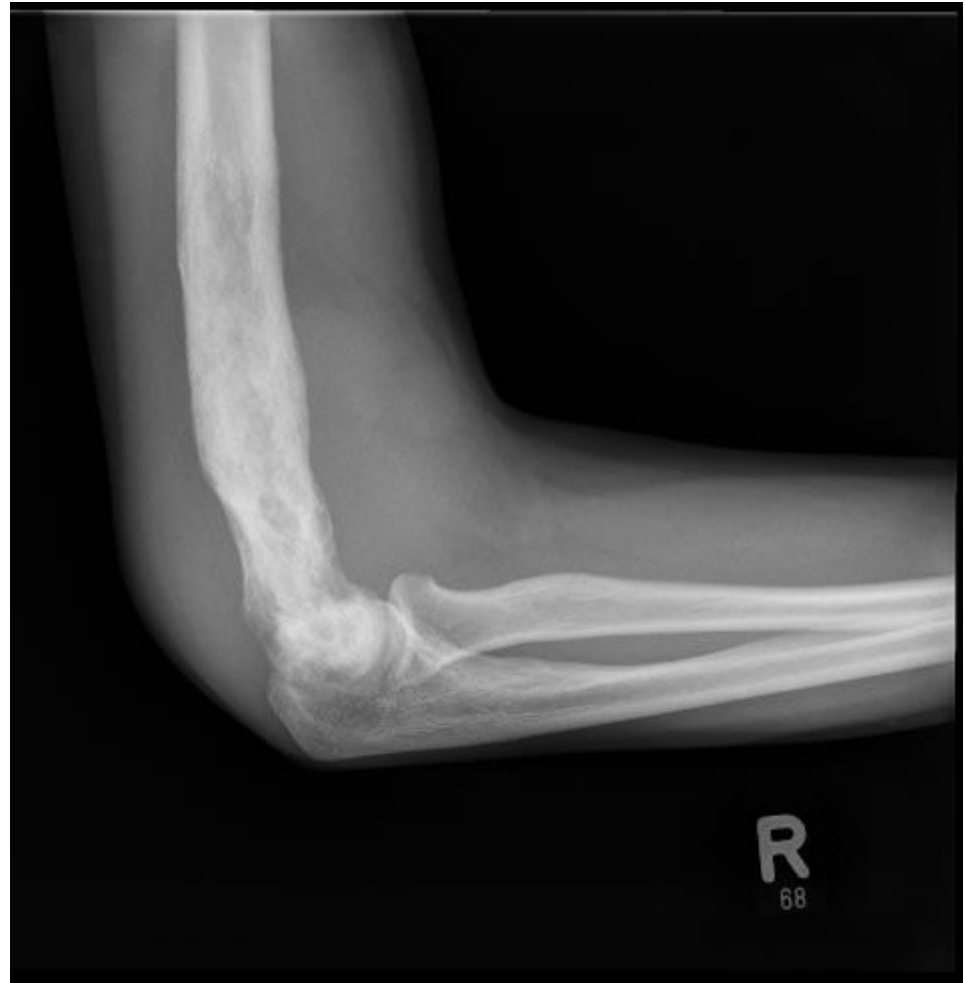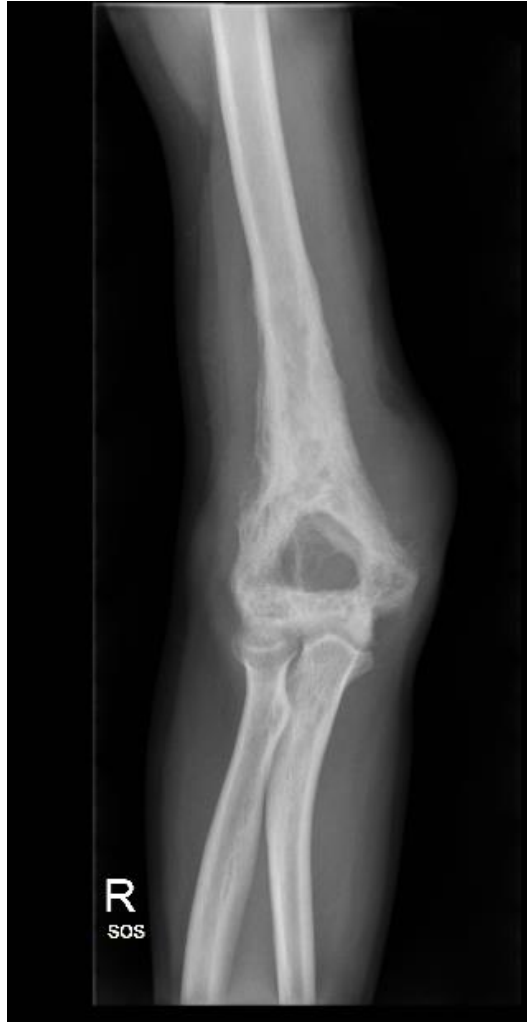# elbow; intercalary resection replantation

## PET CT: February 11th, 2010

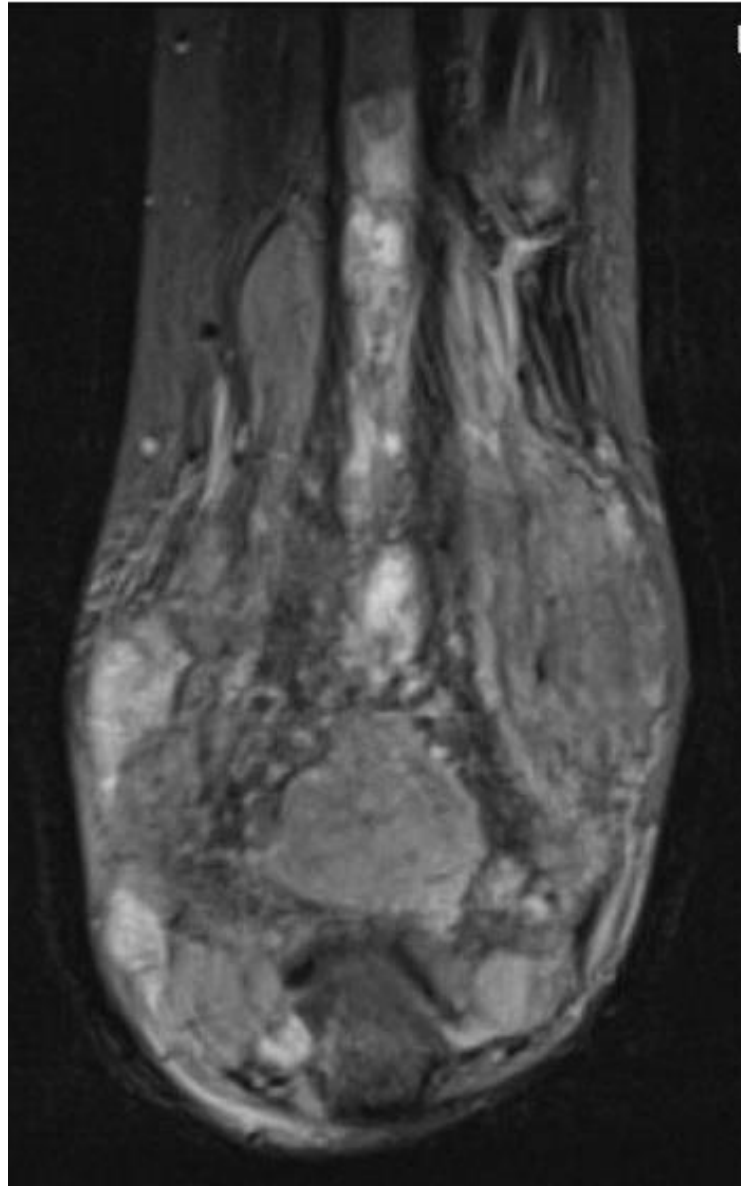


# elbow; intercalary resection replantation

Xray elbow: May 26th, 2011

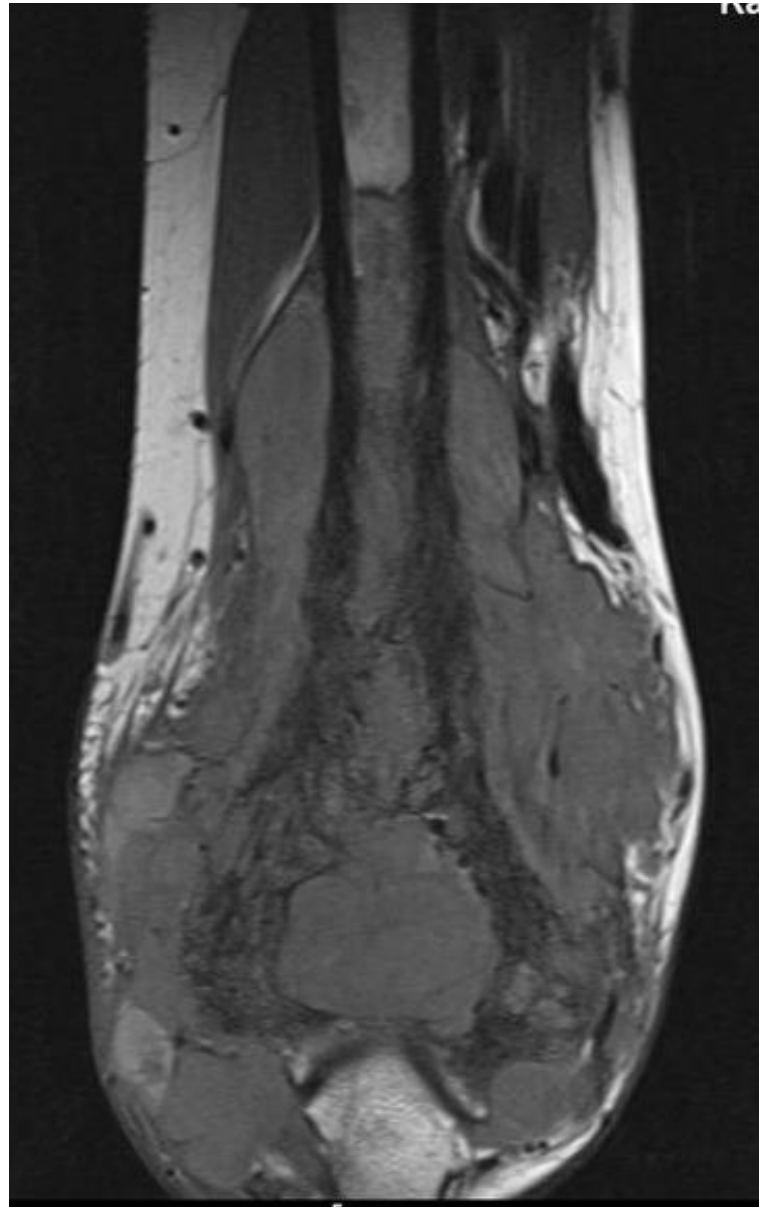


# elbow; intercalary resection replantation MRI elbow: December 19th, 2011



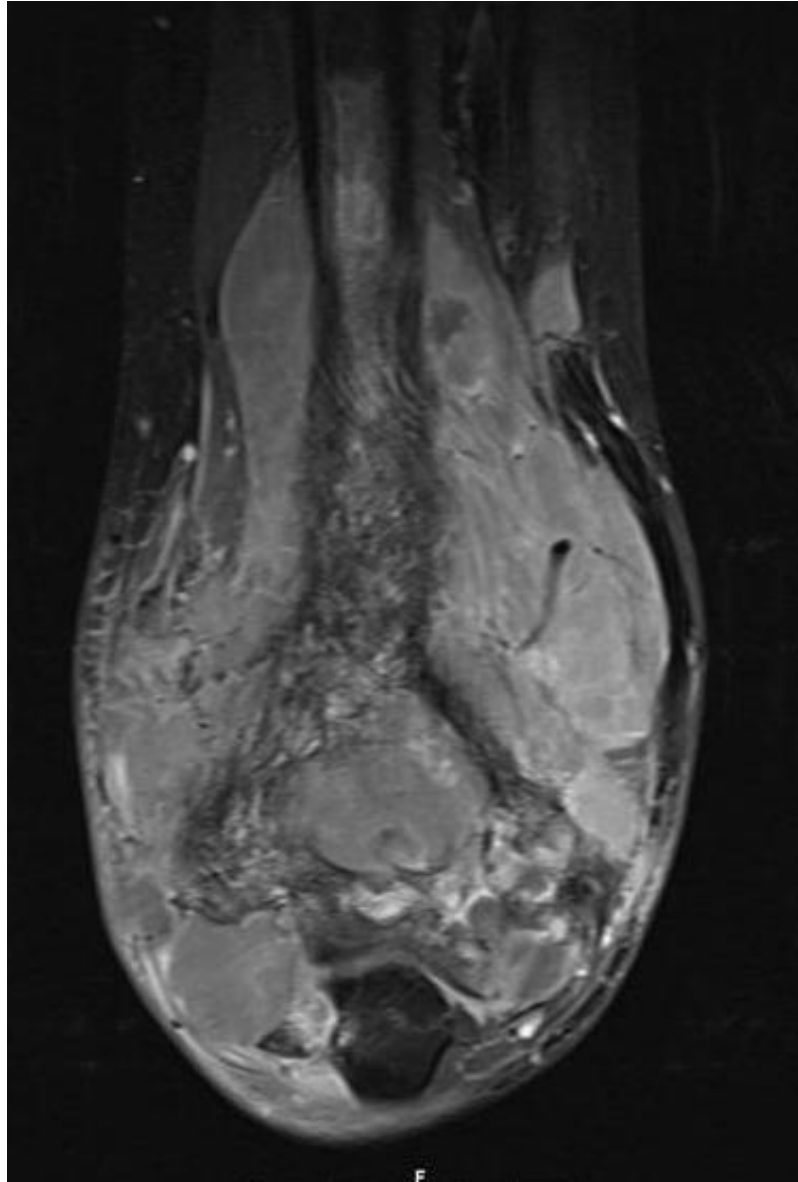


# elbow; intercalary resection replantation MRI elbow: December 19th, 2011



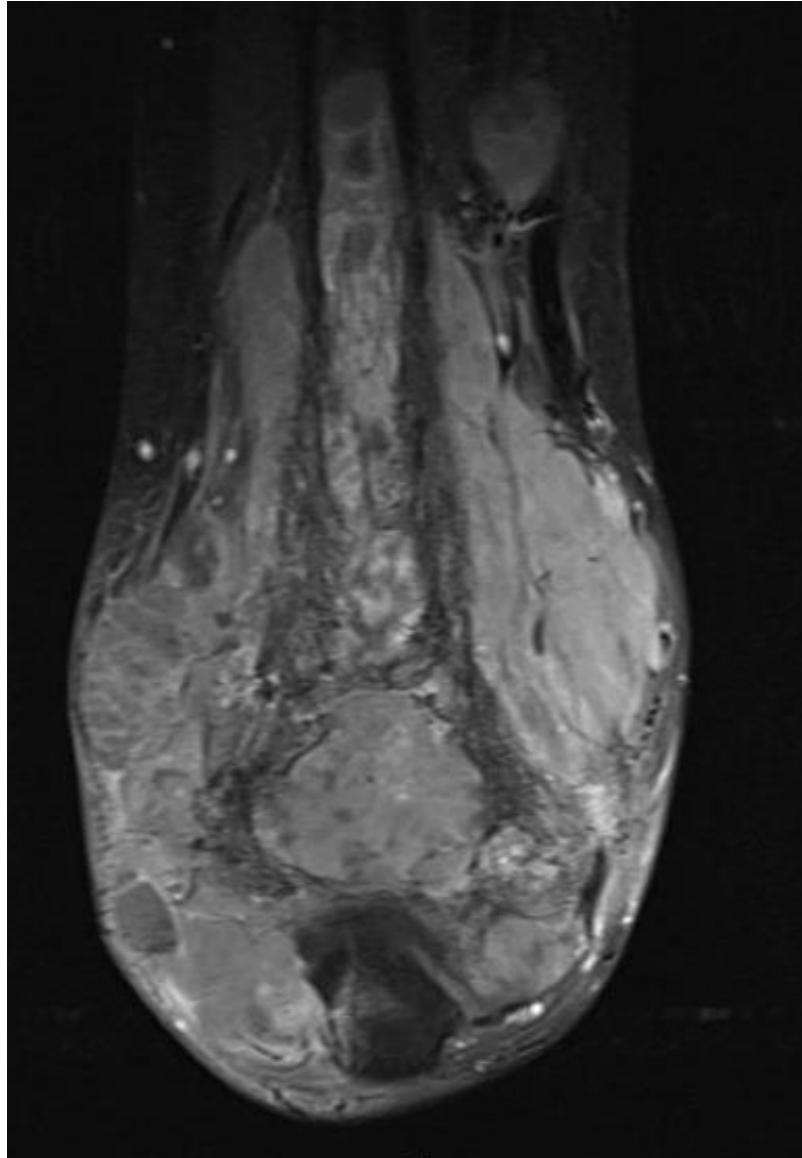
# elbow; intercalary resection replantation

**MRI elbow: December 19th, 2011**



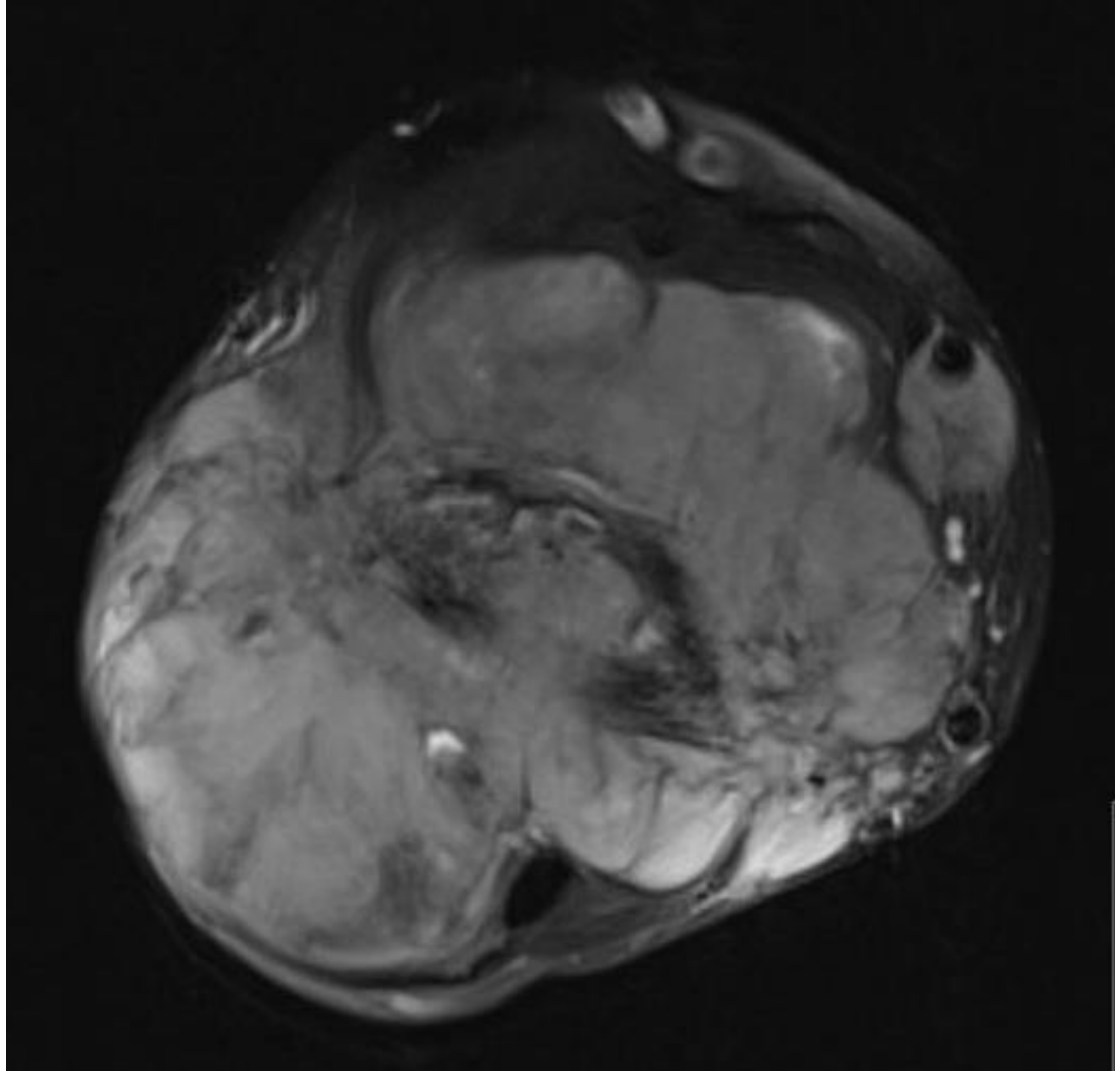
# elbow; intercalary resection replantation

## MRI elbow: December 19th, 2011



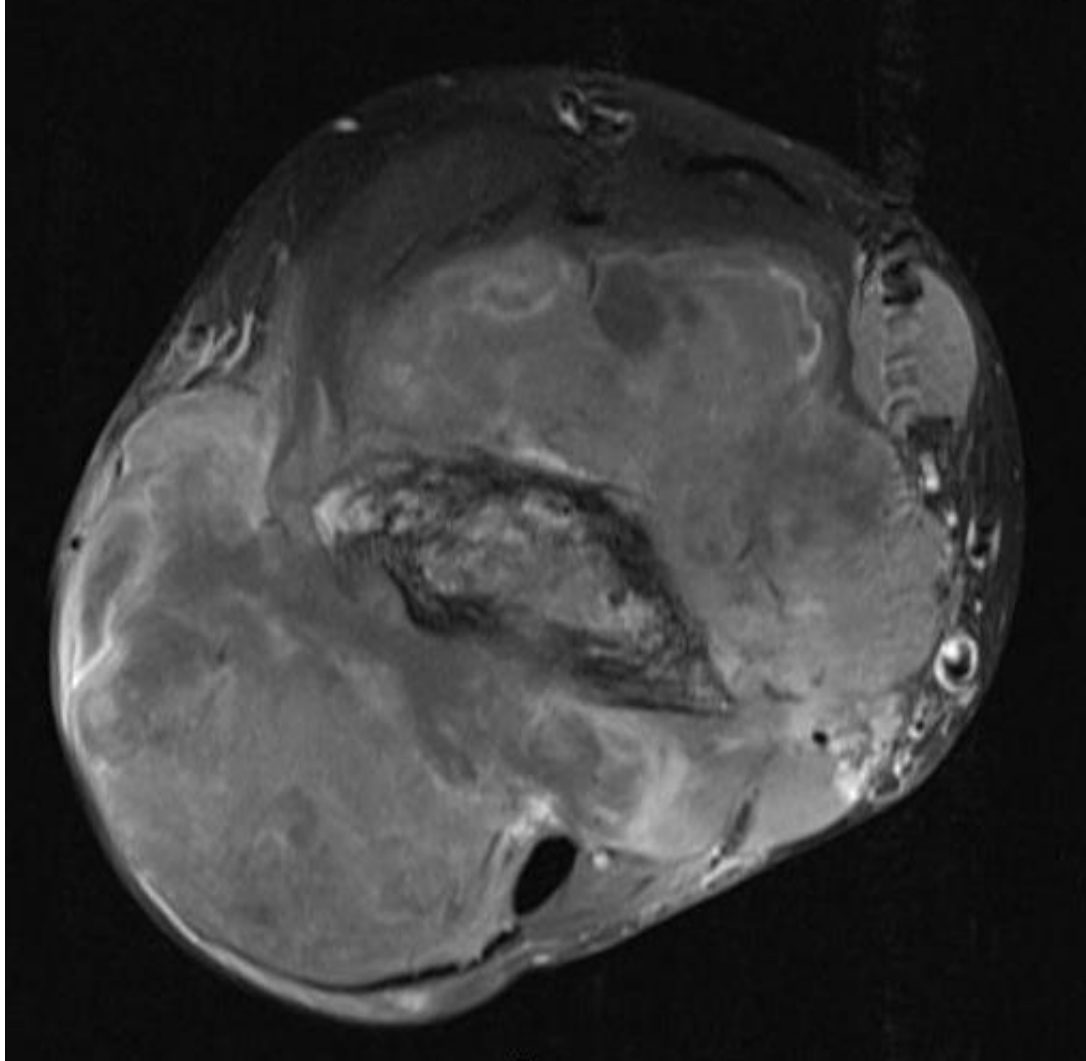
# elbow; intercalary resection replantation

## MRI elbow: December 19th, 2011



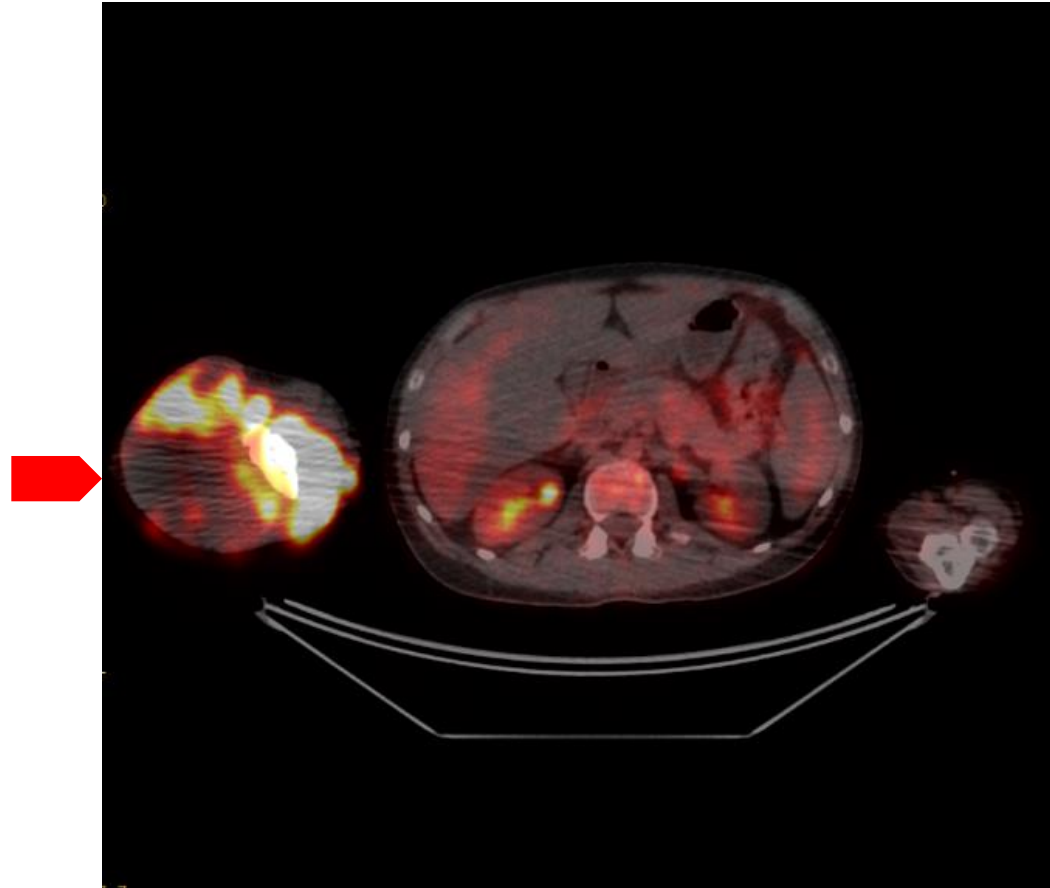
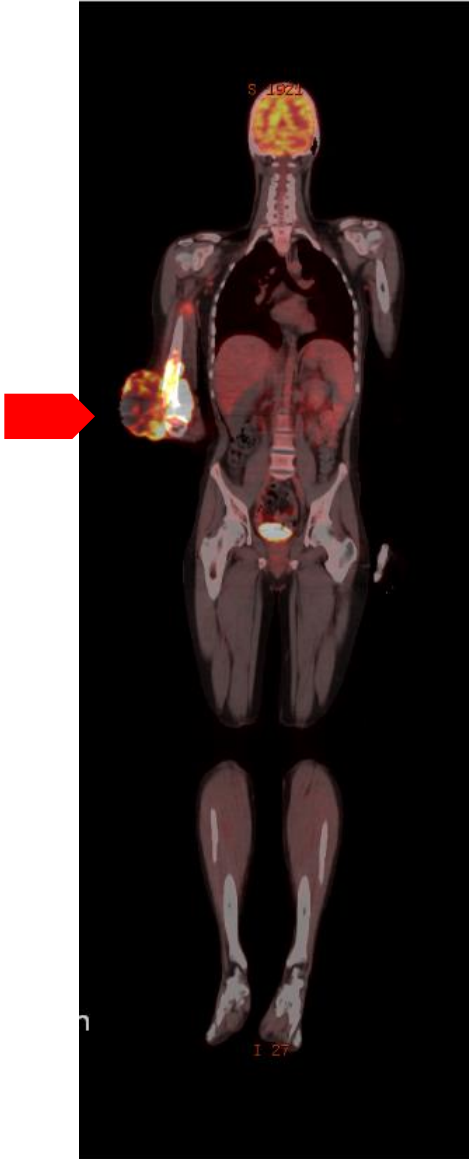# elbow; intercalary resection replantation

## MRI elbow: December 19th, 2011



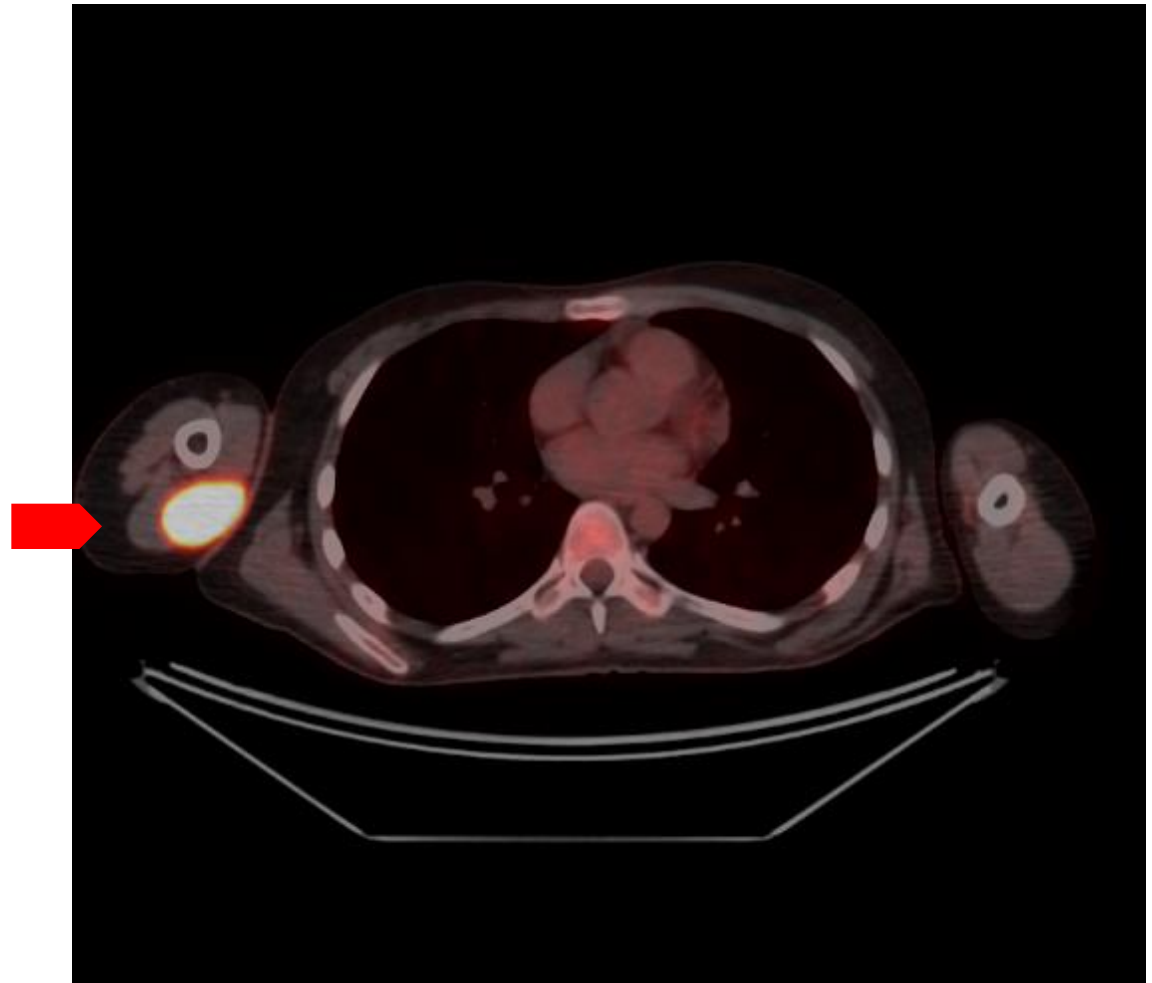
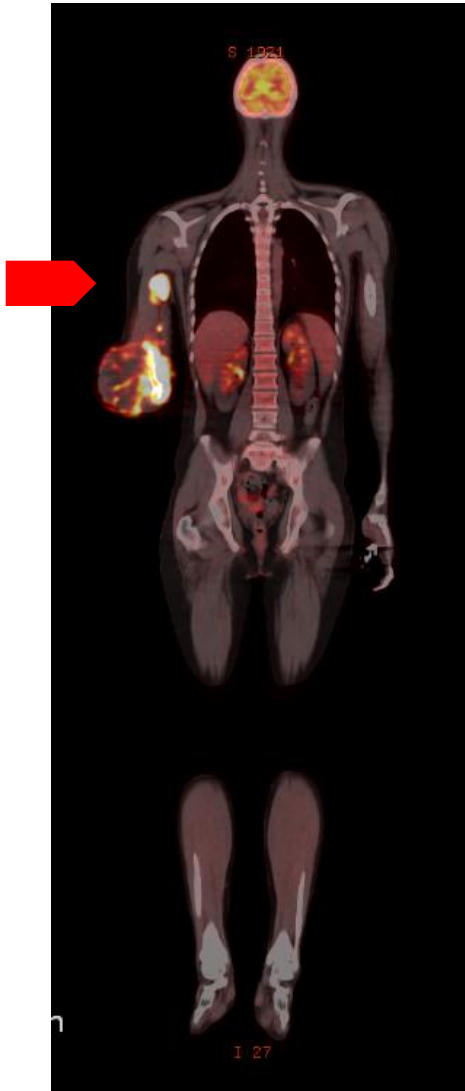
# elbow; intercalary resection replantation

## PET CT: February 24th, 2012

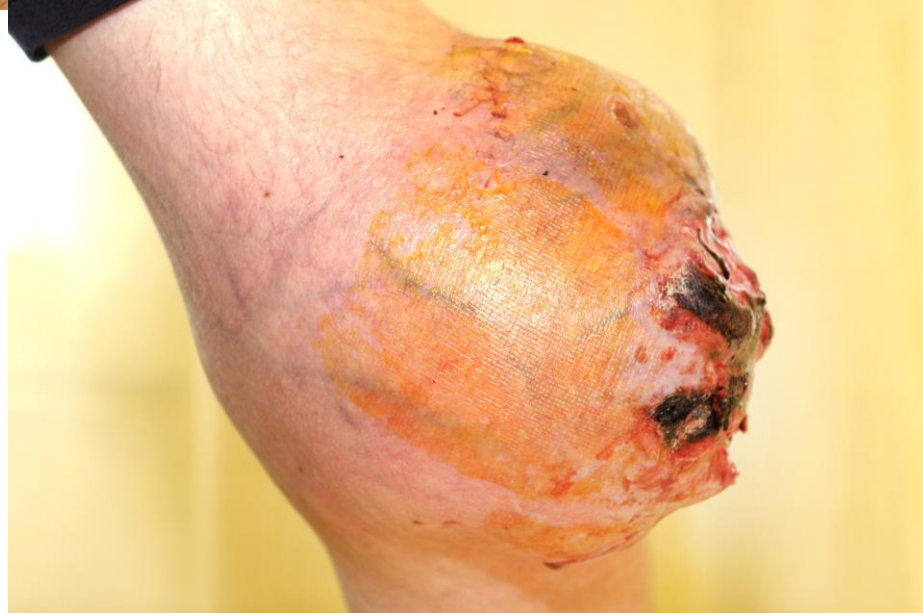
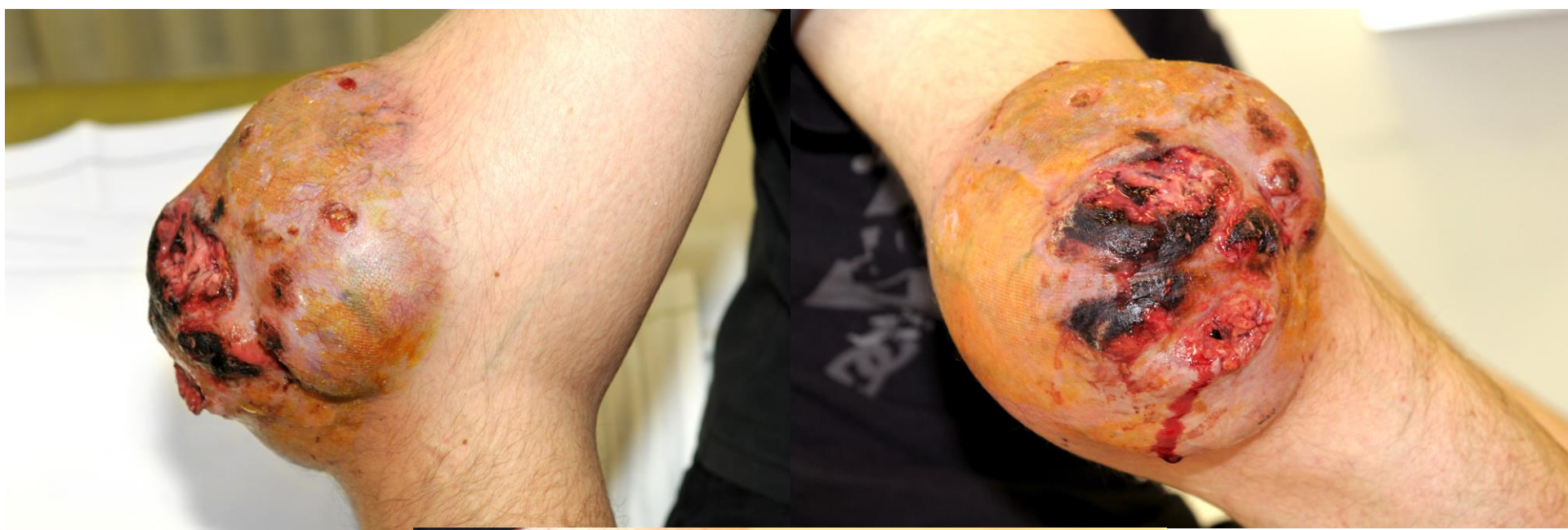
# elbow; intercalary resection replantation

## PET CT: February 24th, 2012

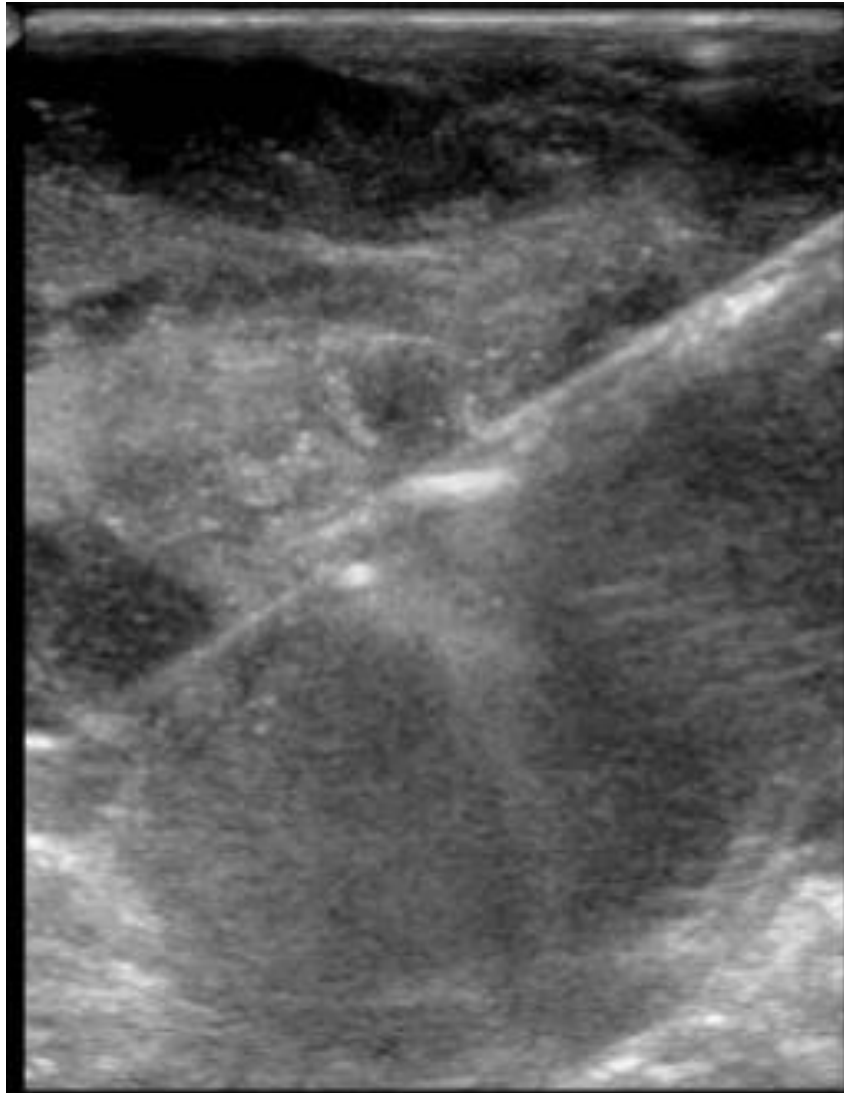


# elbow; intercalary resection replantation





# elbow; intercalary resection replantation Sonographic biopsy: February 27th, 2012



# elbow; intercalary resection replantation

## Sonographic biopsy: February 27th, 2012

Eingang: 27.02.2012

### *Klinische Angaben*

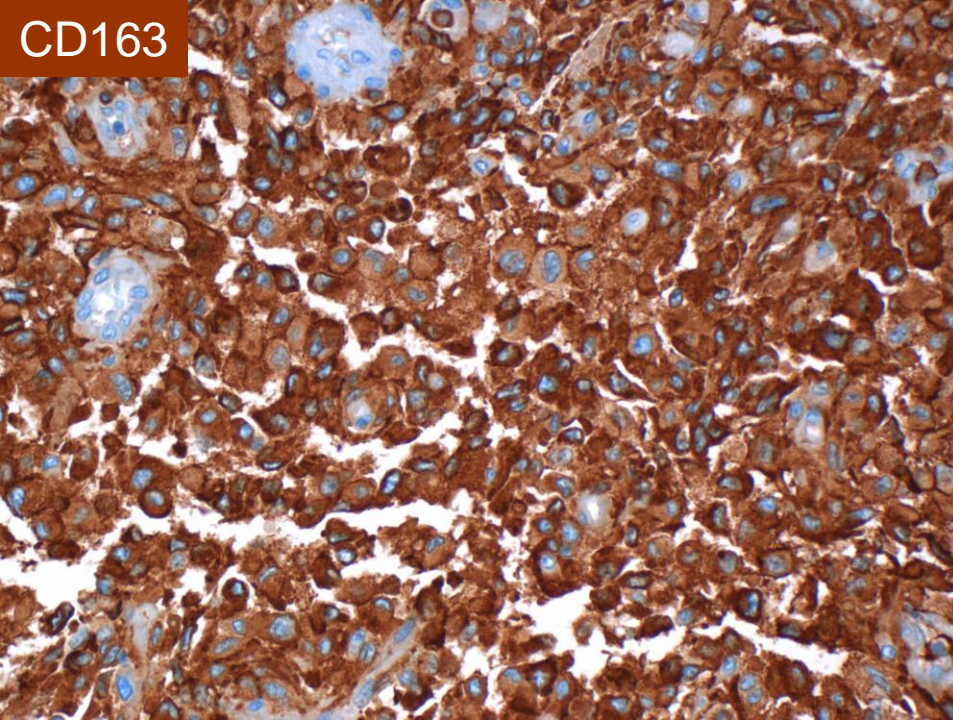
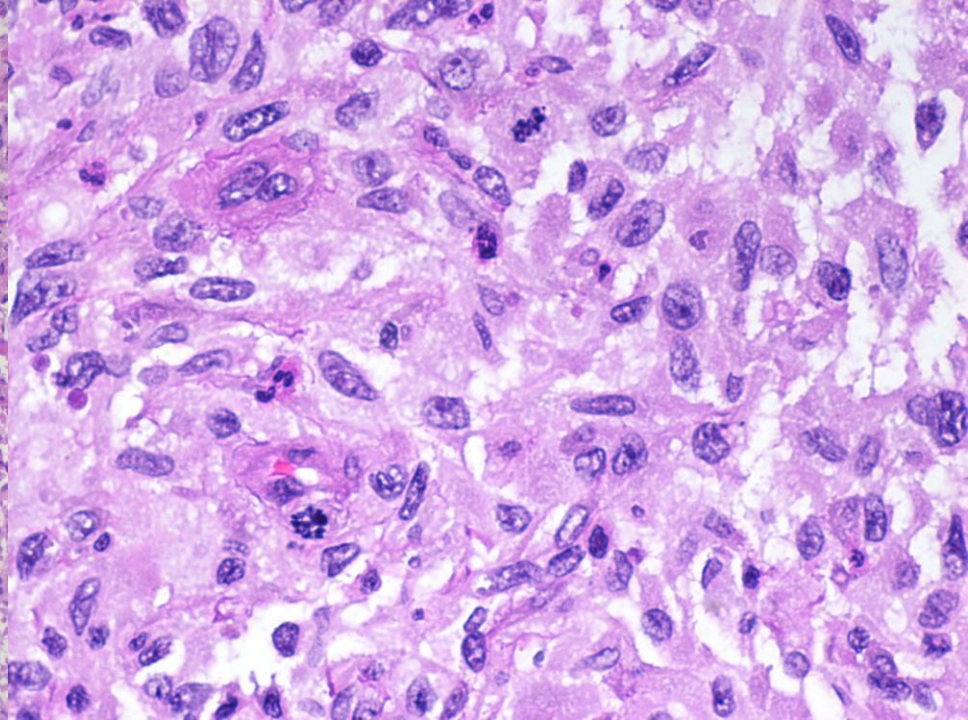
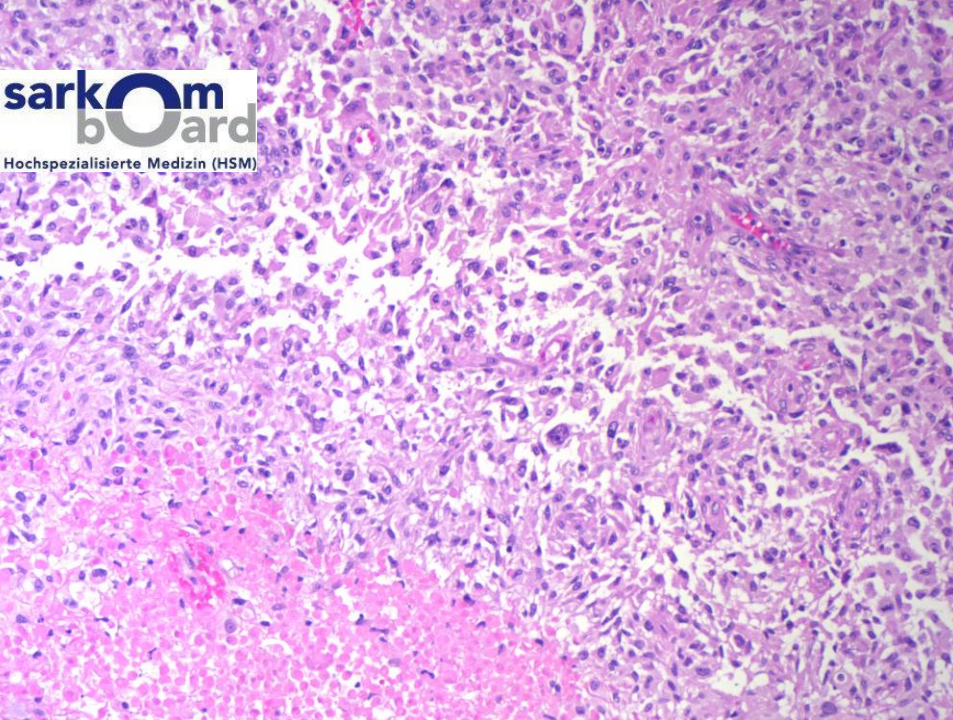
Exulzierender Tumor Ellbogen rechts. St. n. Radiotherapie 2008, St. n. Chemotherapie 2010.  
Externe Diagnose 2008: Sinushistiozytose. Diagnose? Malignität?

### *Angaben zur Probe*

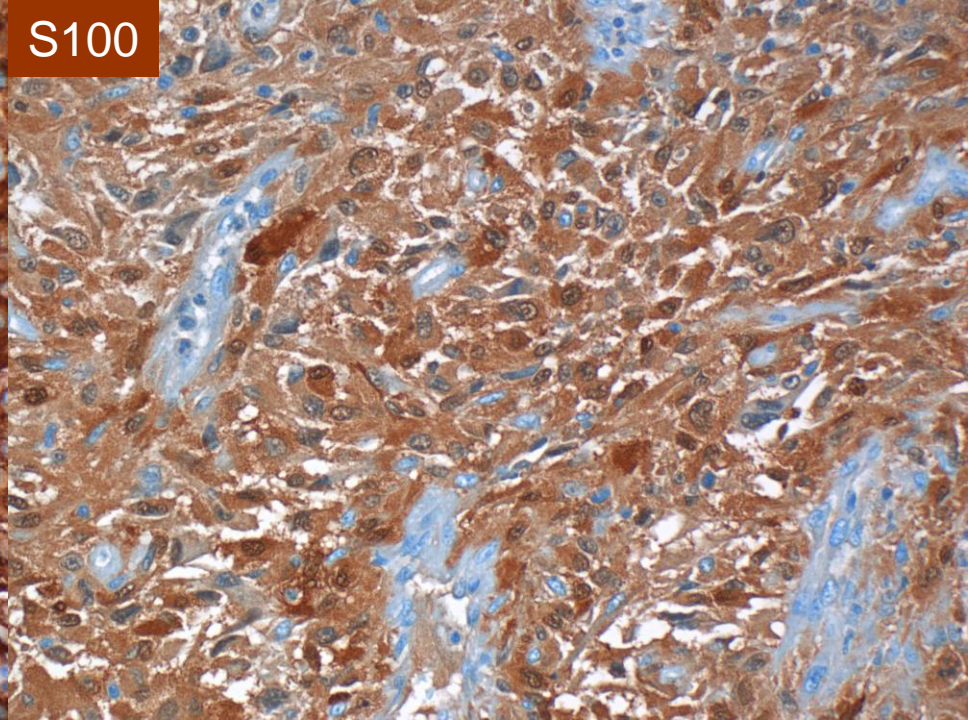
Ellbogen rechts

### *Makroskopischer Befund*

3 Stanzen bis 1,5 cm, weiss-rötlich sowie mehrere kleine Gewebefragmente, < 1 mm. sre

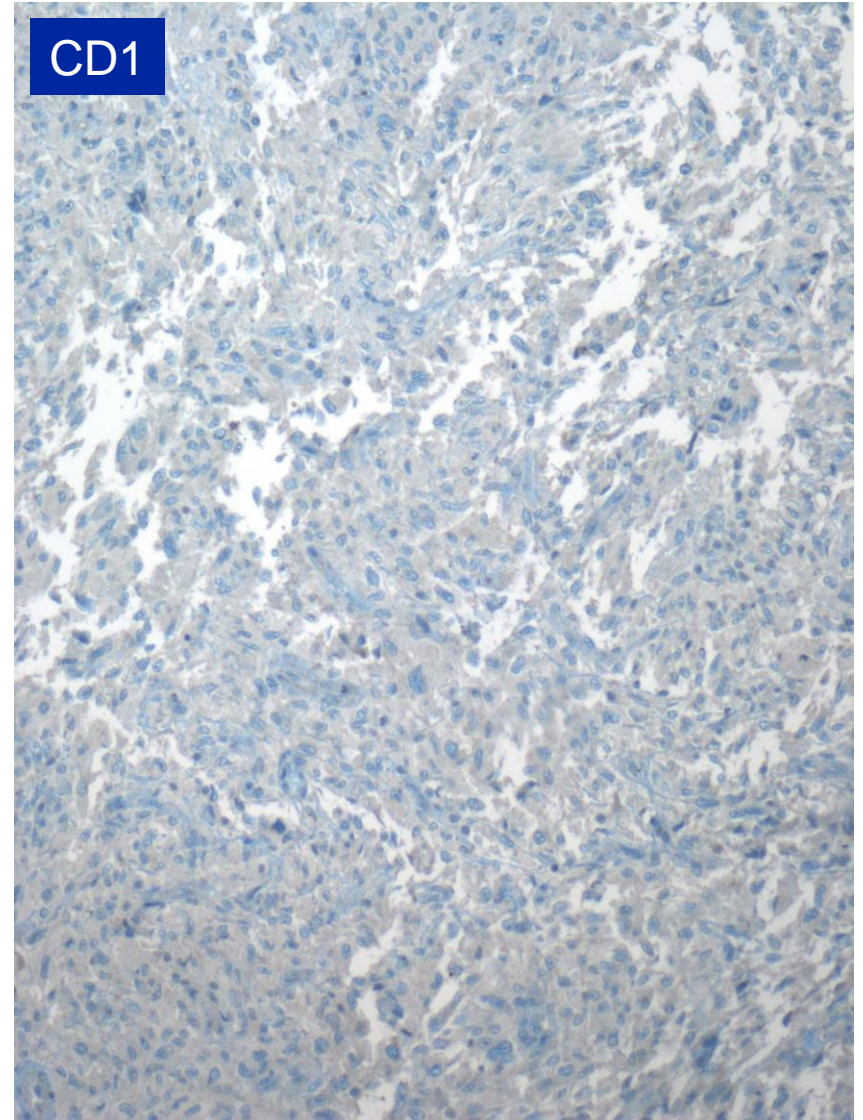
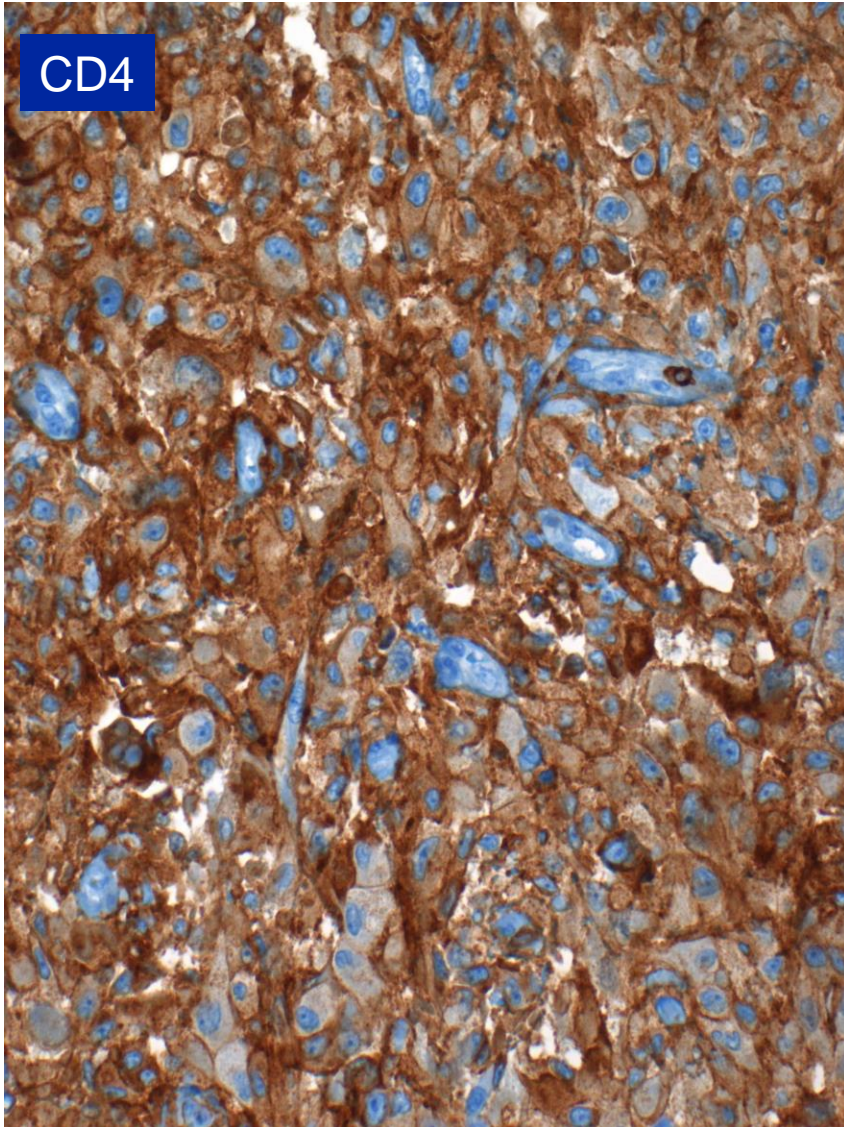


CD163

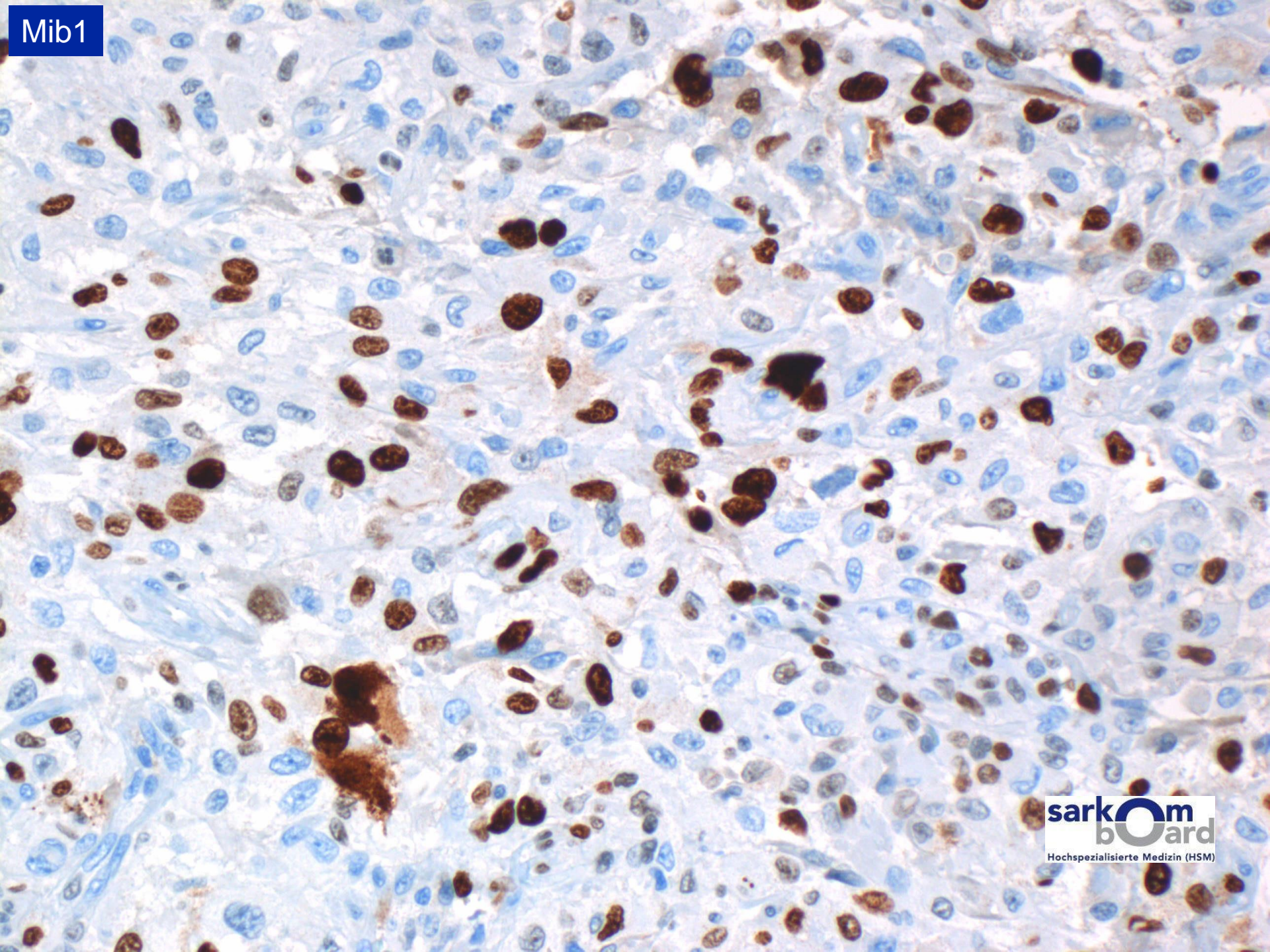


S100

# elbow; intercalary resection replantation



Mib1



# elbow; intercalary resection replantation

## Result biopsy: February 27th, 2012

Eingang: 27.02.2012

### *Klinische Angaben*

Exulzerierender Tumor Ellbogen rechts. St. n. Radiotherapie 2008, St. n. Chemotherapie 2010.  
Externe Diagnose 2008: Sinushistiozytose. Diagnose? Malignität?

### *Angaben zur Probe*

Ellbogen rechts

### *Makroskopischer Befund*

3 Stenzen bis 1,5 cm, weiss-rötlich sowie mehrere kleine Gewebefragmente, < 1 mm. sre

# elbow; intercalary resection replantation

## Result biopsy: February 27th, 2012

### Provisorischer Bericht

#### *Diagnose*

Anteile einer hochgradig malignen, wenig differenzierten, spindel- und pleomorphzelligen Neoplasie (Ellbogen rechts; vgl. Kommentar).

### **Histiocytic sarcoma after acute lymphoblastic leukaemia: a common clonal origin**

Andrew L Feldman, Caterina Minniti, Mariarita Santi, James R Downing, Mark Raffeld, and Elaine S Jaffe

---

*Lancet Oncol* 2004; 5: 248–50

# elbow; intercalary resection replantation

## Result biopsy: February 27th, 2012

[Display Settings:](#)  Abstract

[Send to:](#)

[Pediatr Dev Pathol.](#) 2010 May-Jun;13(3):225-37.

### **Clinicopathologic features of histiocytic lesions following ALL, with a review of the literature.**

[Castro EC](#), [Blazquez C](#), [Boyd J](#), [Correa H](#), [de Chadarevian JP](#), [Felgar RE](#), [Graf N](#), [Lew N](#), [Lowe EJ](#), [Manning JT Jr](#), [Proytcheva MA](#), [Senger C](#), [Shavan K](#), [Sterba J](#), [Werner A](#), [Surti U](#), [Jaffe R](#).

Department of Pathology, Children's Hospital of Pittsburgh, Pittsburgh, PA, USA.

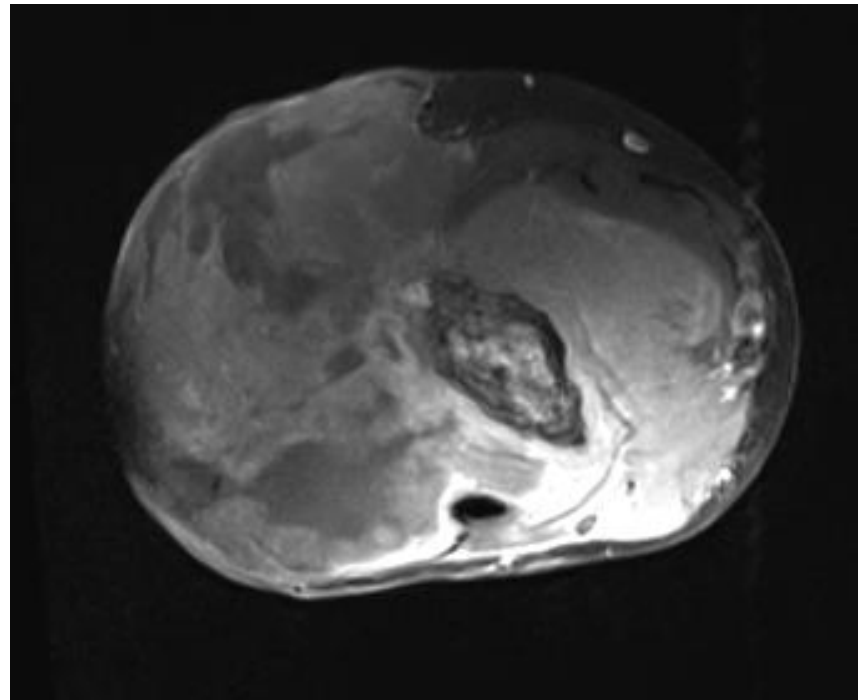
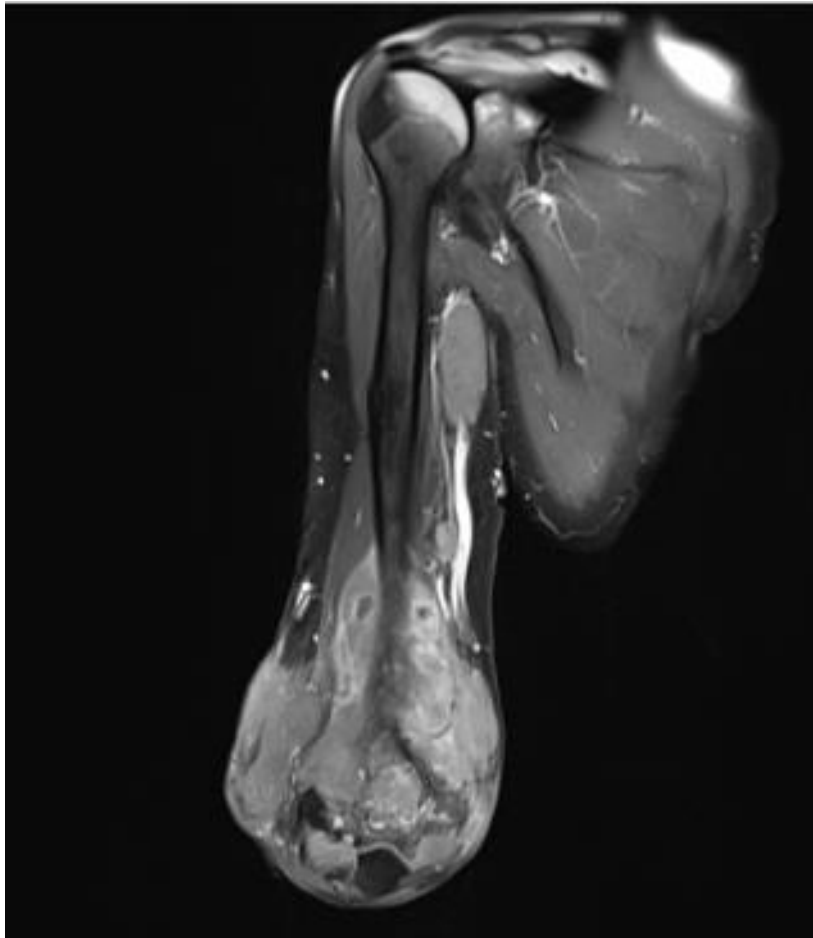#### **Abstract**

We describe the clinicopathologic features of 15 patients who had histiocytic lesions that followed acute lymphoblastic leukemia (ALL). Twenty-one separate histiocytic lesions were evaluated that covered a wide spectrum, some conforming to the usual categories of juvenile xanthogranulomas (5), Langerhans' cell histiocytosis (1), Langerhans' cell sarcoma (4), Rosai-Dorfman disease (1), and histiocytic sarcoma (4). Most were atypical for the category by histology, phenotype, or abnormally high turnover rate. Seven low-grade lesions defied easy categorization and were characterized only as "atypical histiocytic lesion" following ALL. For those evaluated, the molecular signature of the prior leukemia was present in the histiocytic lesion. In 3 of 15 patients, the leukemia and histiocytic lesion shared immunoglobulin H or monoclonal TCR gene rearrangements and, in 4 of 15 patients, clonal identity was documented by fluorescence in situ hybridization. Four patients died of progressive disease, 3 of whom had histiocytic sarcoma and 1 who had an atypical lesion. One patient died of recurrent ALL. The other 10 patients are alive, 7 after recurrences and treatment with surgery and/or chemotherapy. The post-ALL lesions are more aggressive than their native counterparts, but despite the demonstration of the presence of the leukemia signature in 7 of 15 patients, the prognosis is generally favorable, except for patients with histiocytic sarcoma. It remains unclear whether the histiocytic lesions arise as a line from the original ALL or whether transdifferentiation is involved.



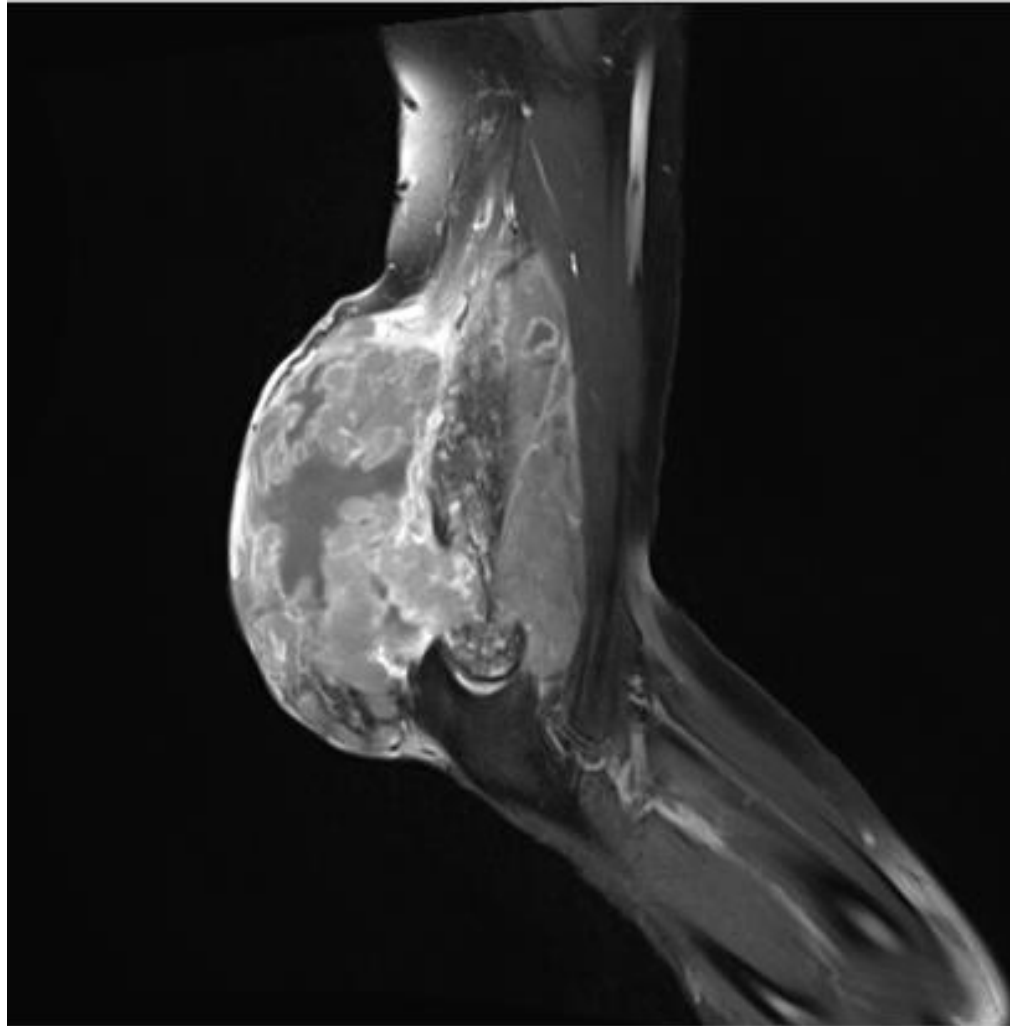
# elbow; intercalary resection replantation

## MRI: March 7th, 2012



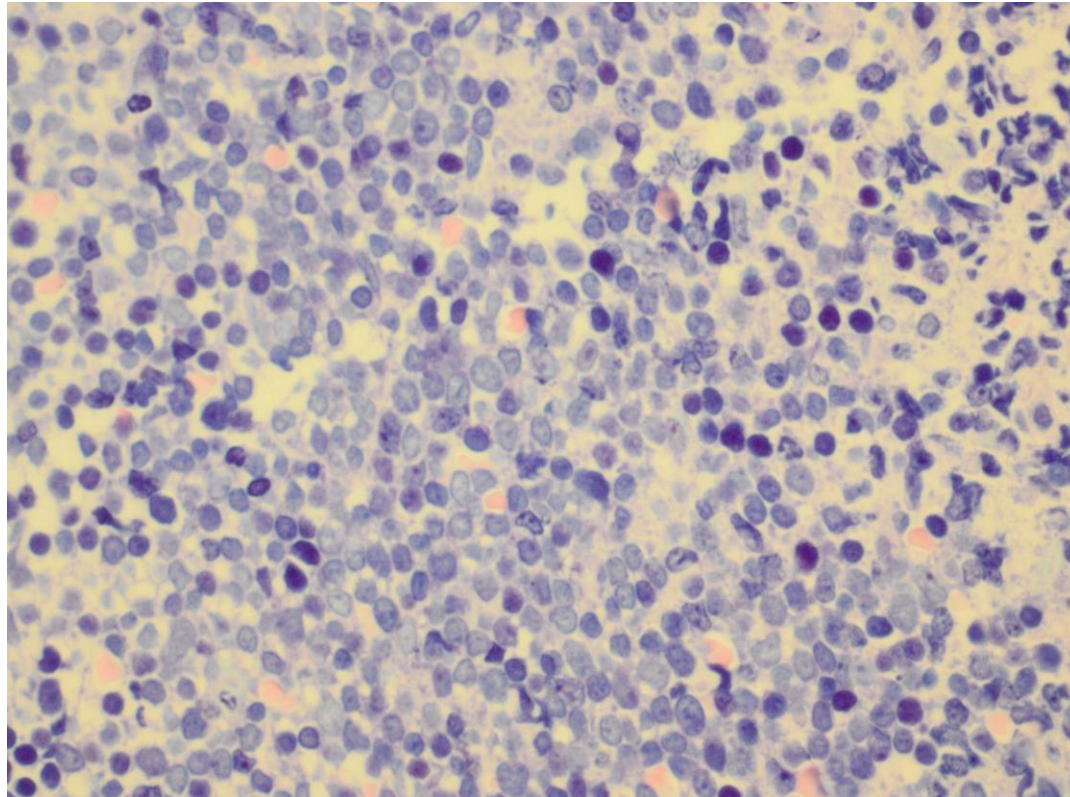
# elbow; intercalary resection replantation

## MRI: March 7th, 2012



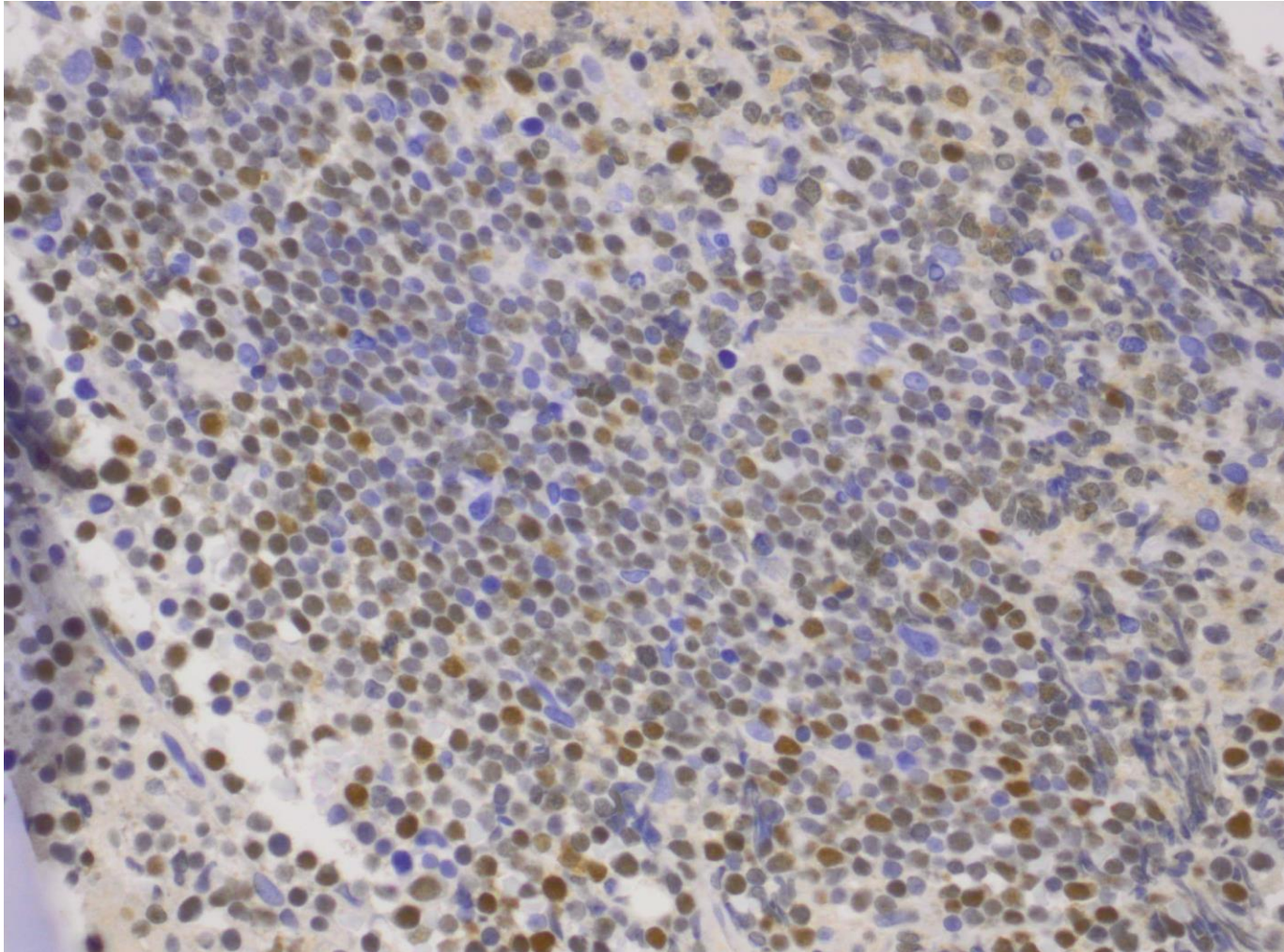
# elbow; intercalary resection replantation

ALL 1992



# elbow; intercalary resection replantation

ALL 1992  
TdT



# elbow; intercalary resection replantation

Entnahme: . . .

Eingang: 13.03.2012

## *Diagnose*

Achtung: Nachuntersuchung an einer Knochenmarkbiopsie aus dem Jahre 1992

Genotypisierung mittels PCR und Fragmentanalyse:

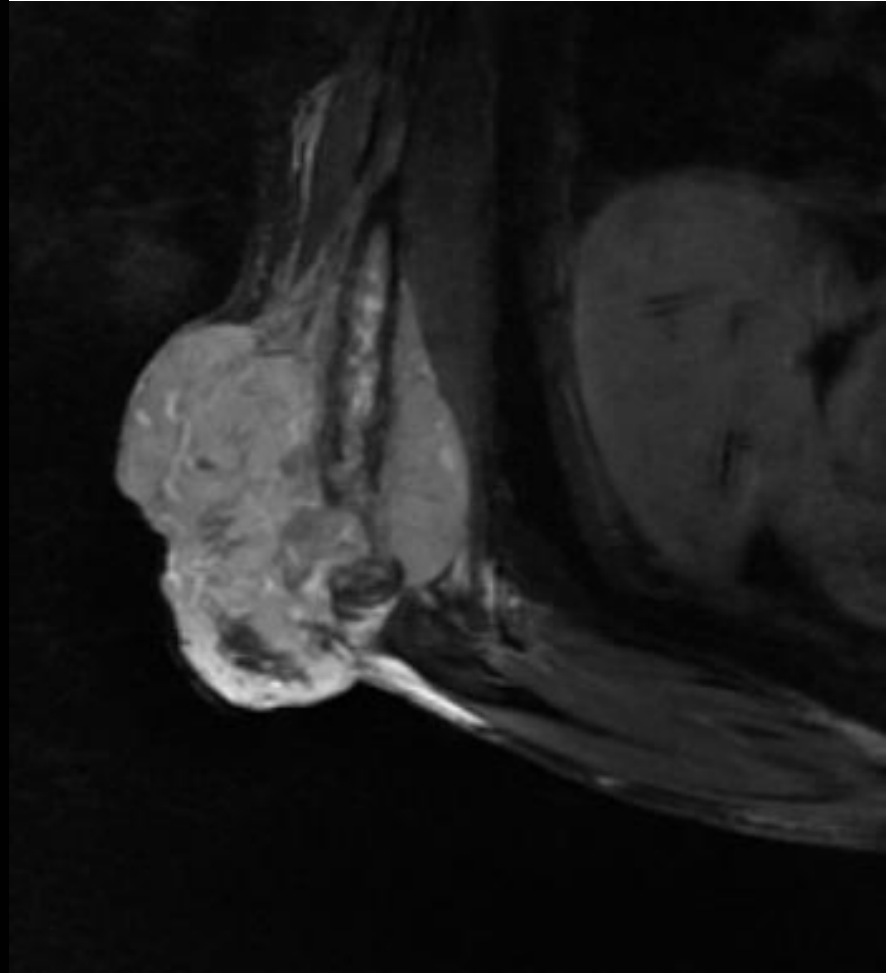
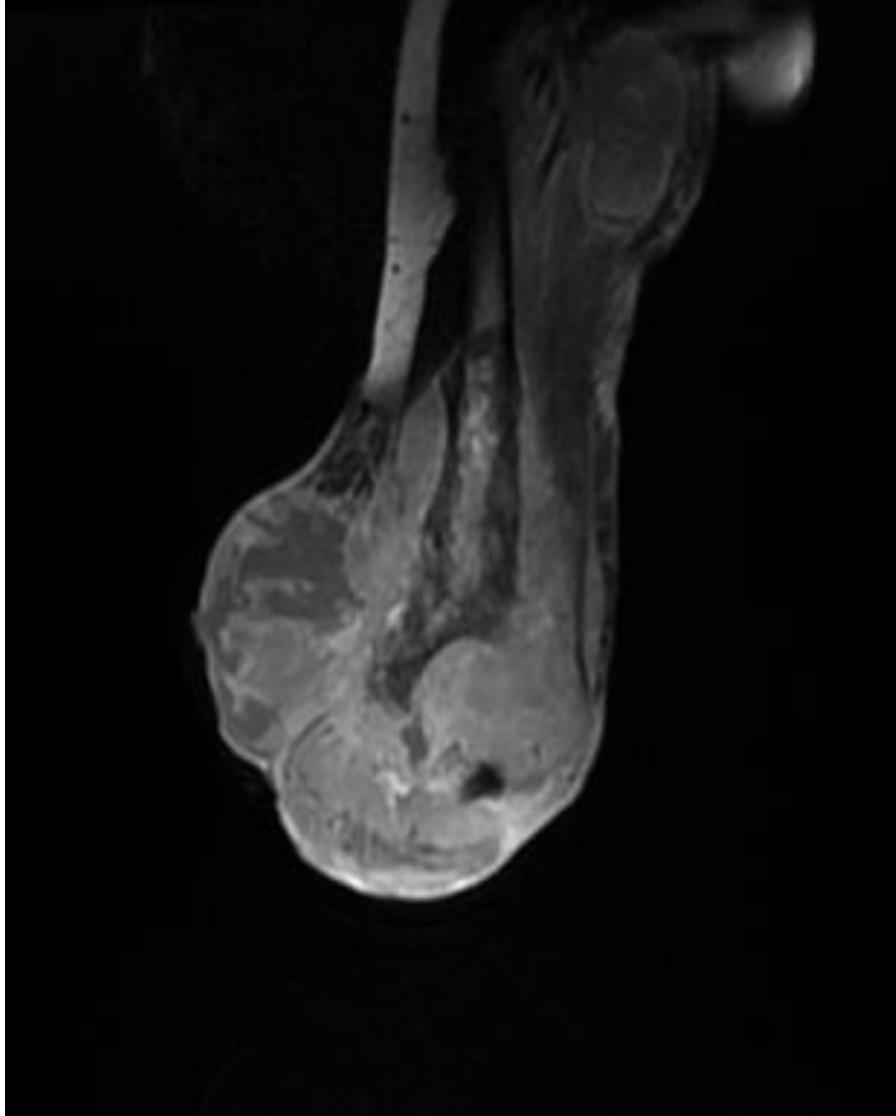
IgH Genlokus -> monoklonale Rearrangierung.

Identisches Rearrangierungsmuster wie histiozytäres Sarkom von 2012

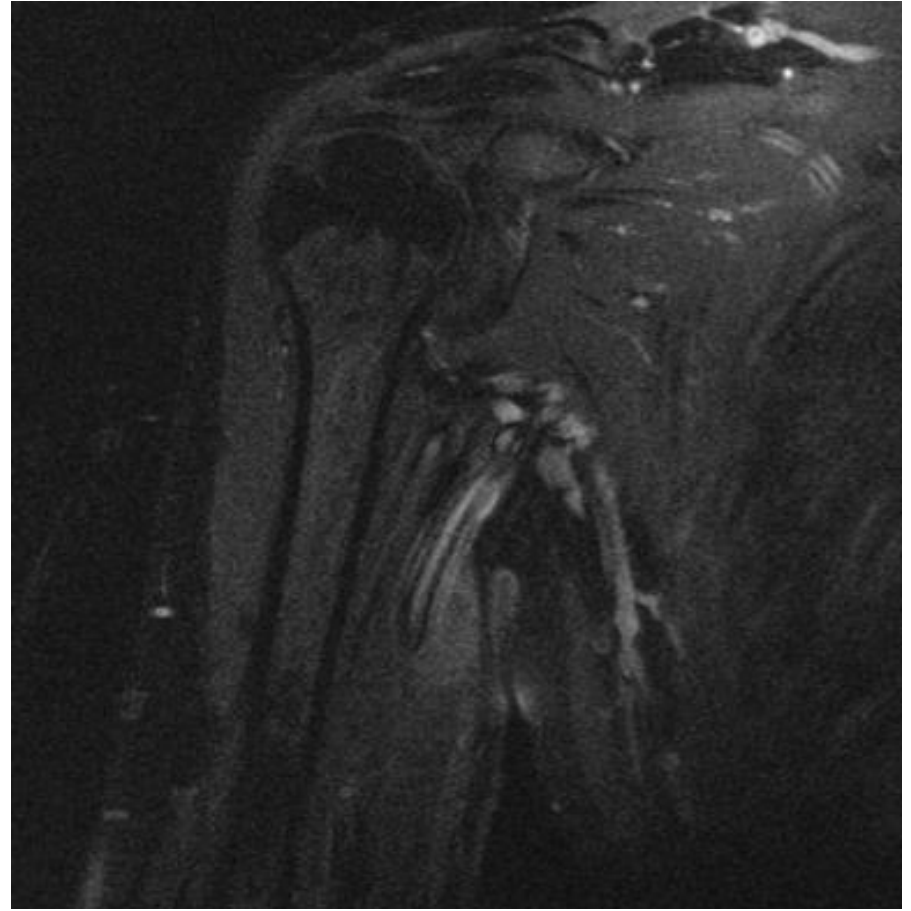
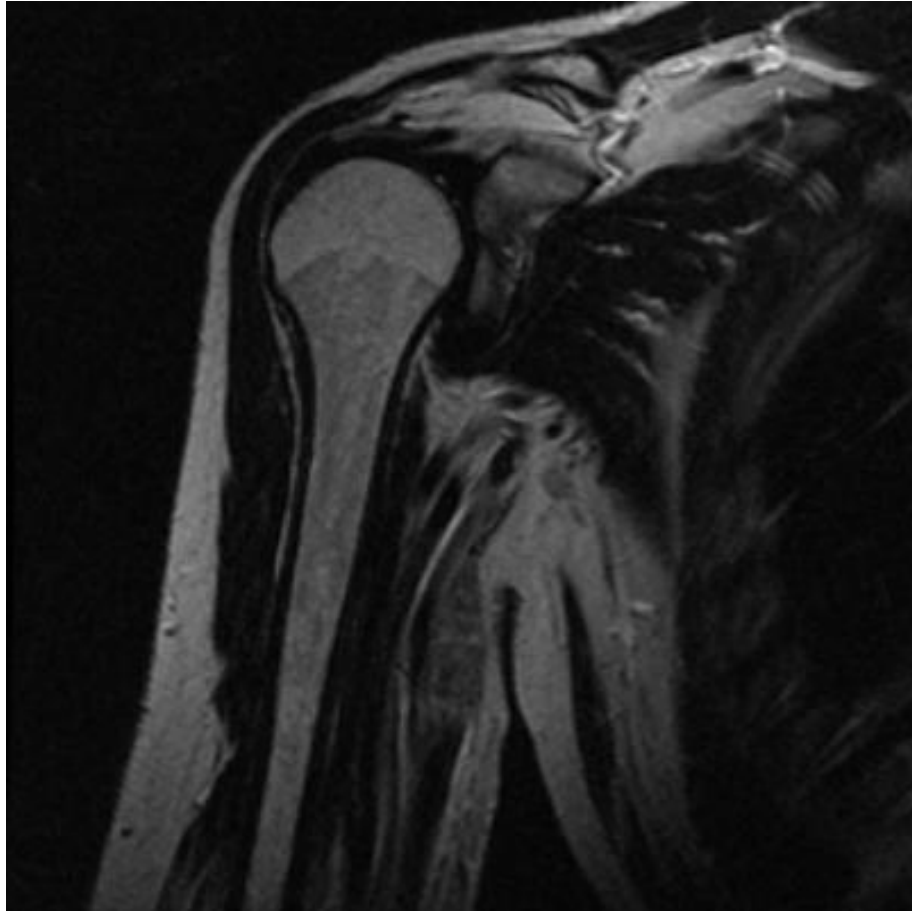
(siehe Kommentar und M2012.324)

# elbow; intercalary resection replantation

## MRI: March 20th, 2012

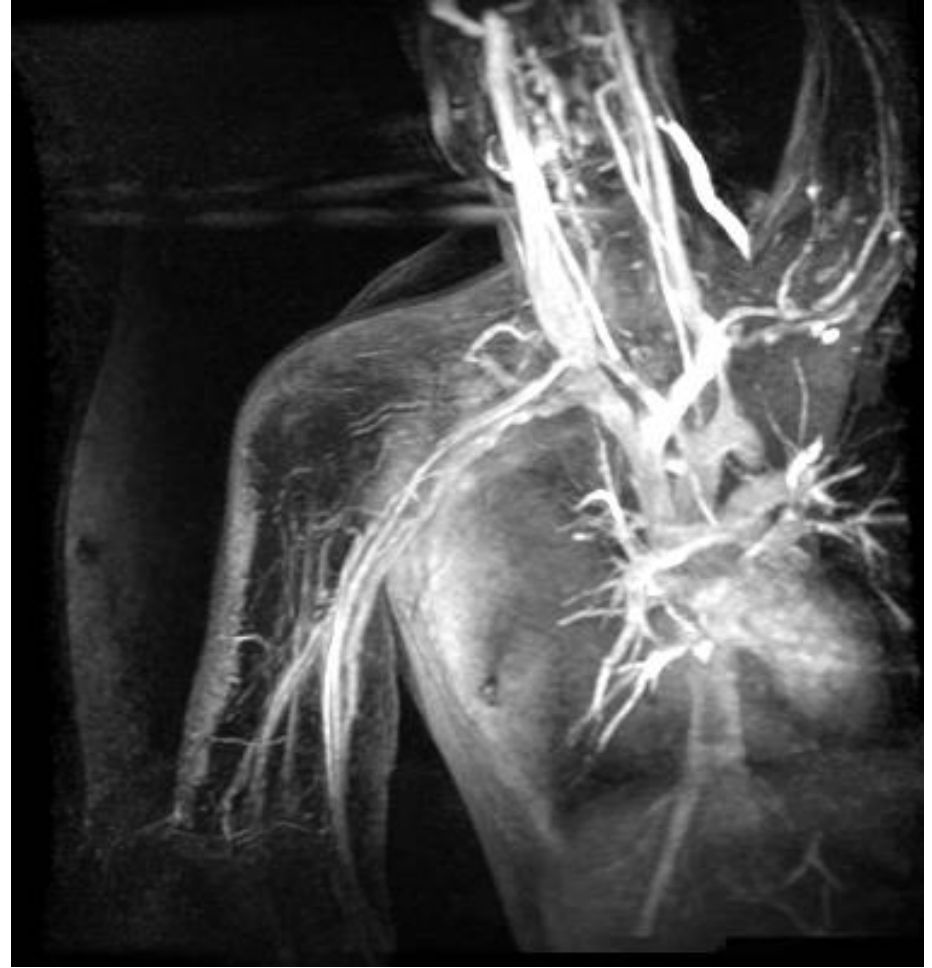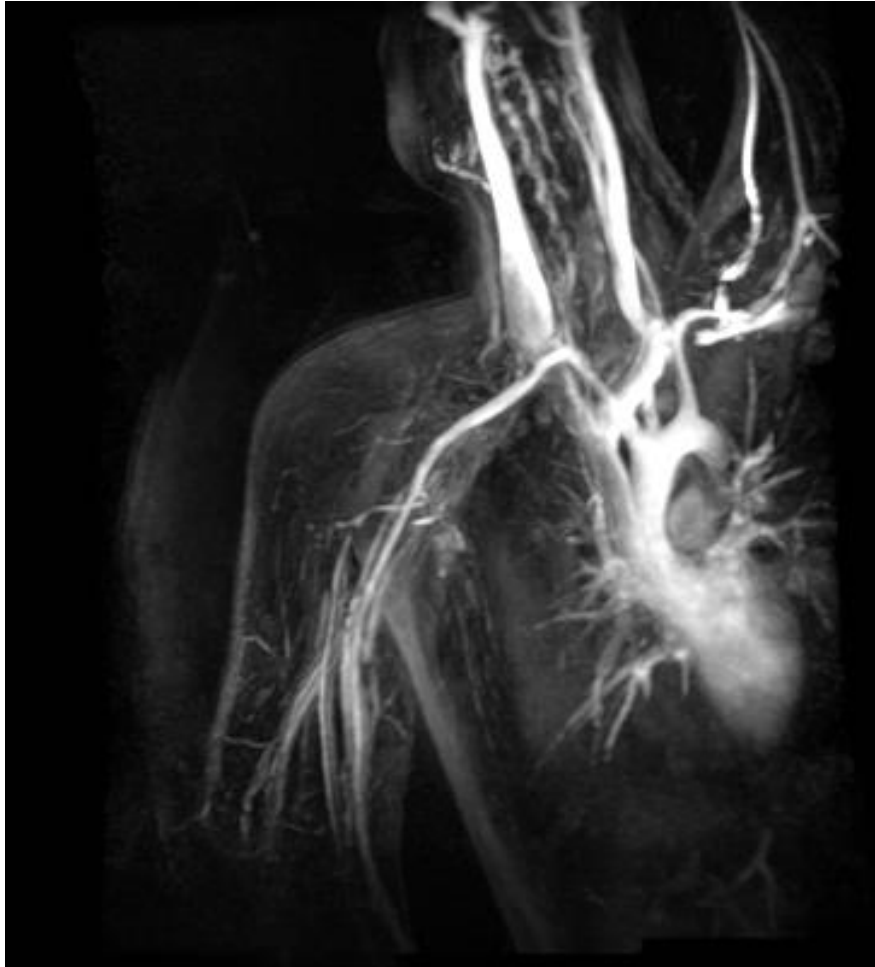


# elbow; intercalary resection replantation MRI: March 20th, 2012



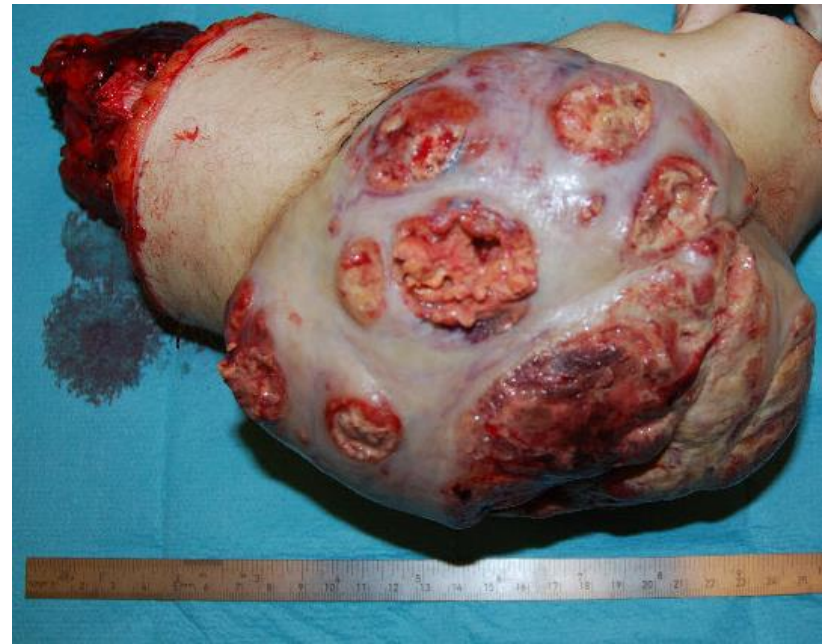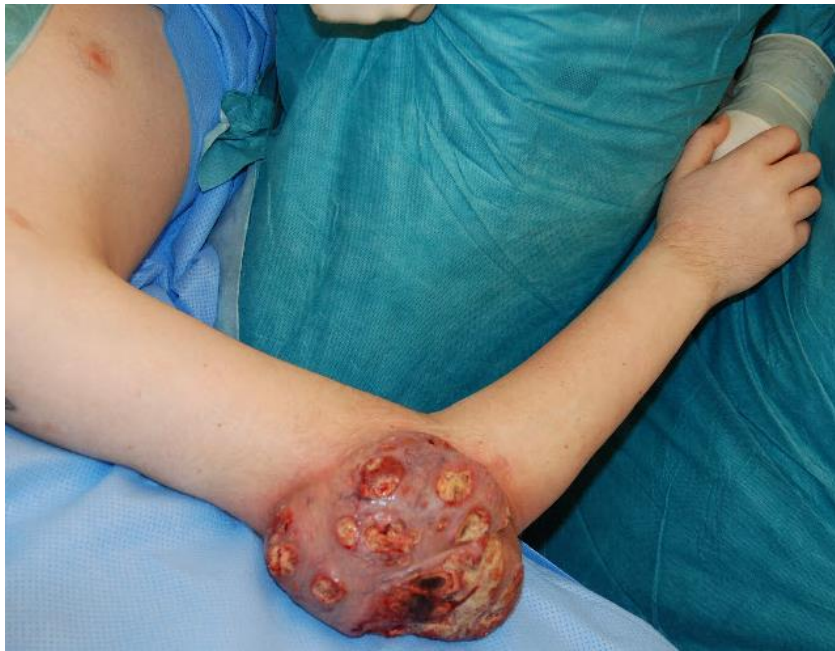# elbow; intercalary resection replantation

## MRI: March 20th, 2012

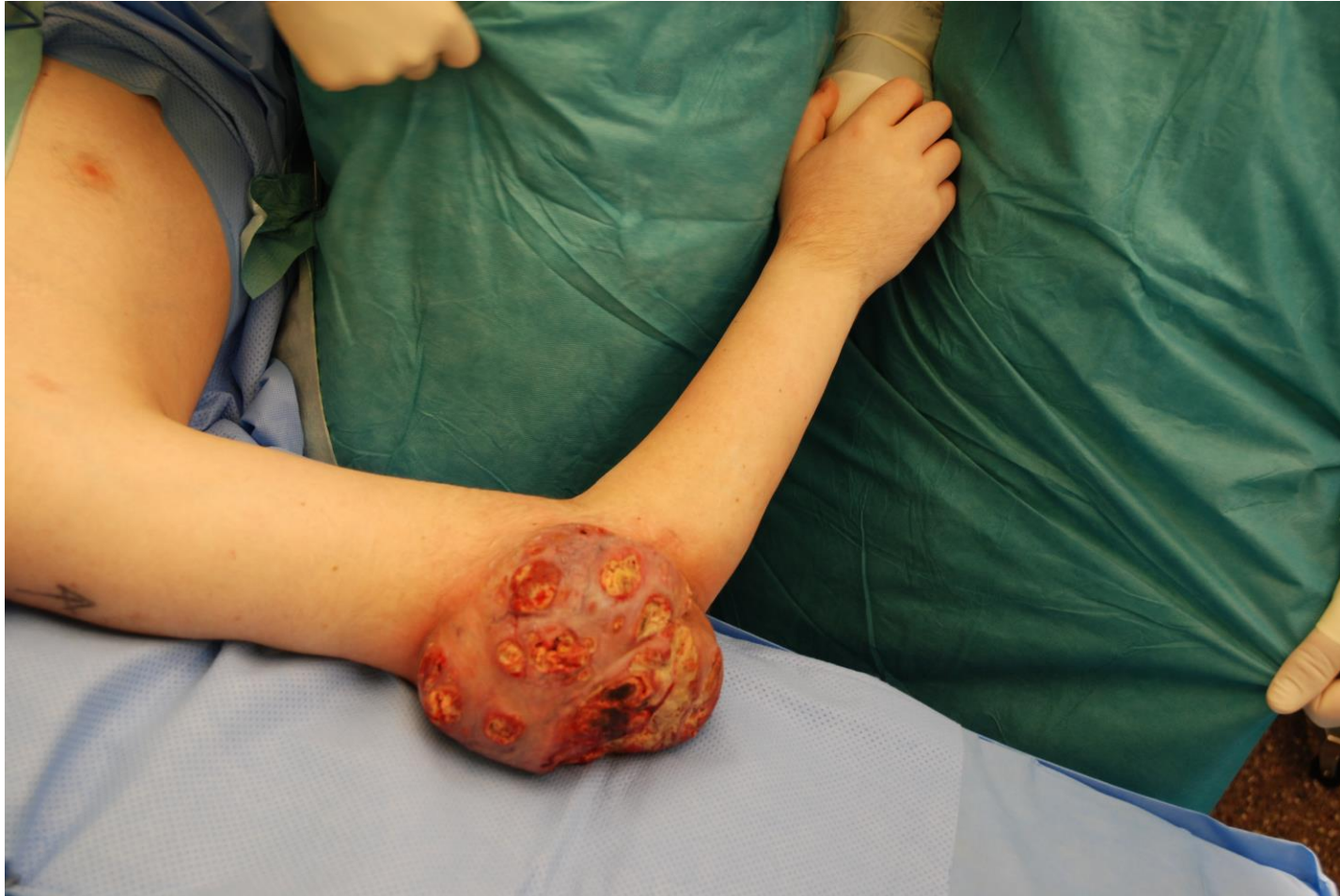



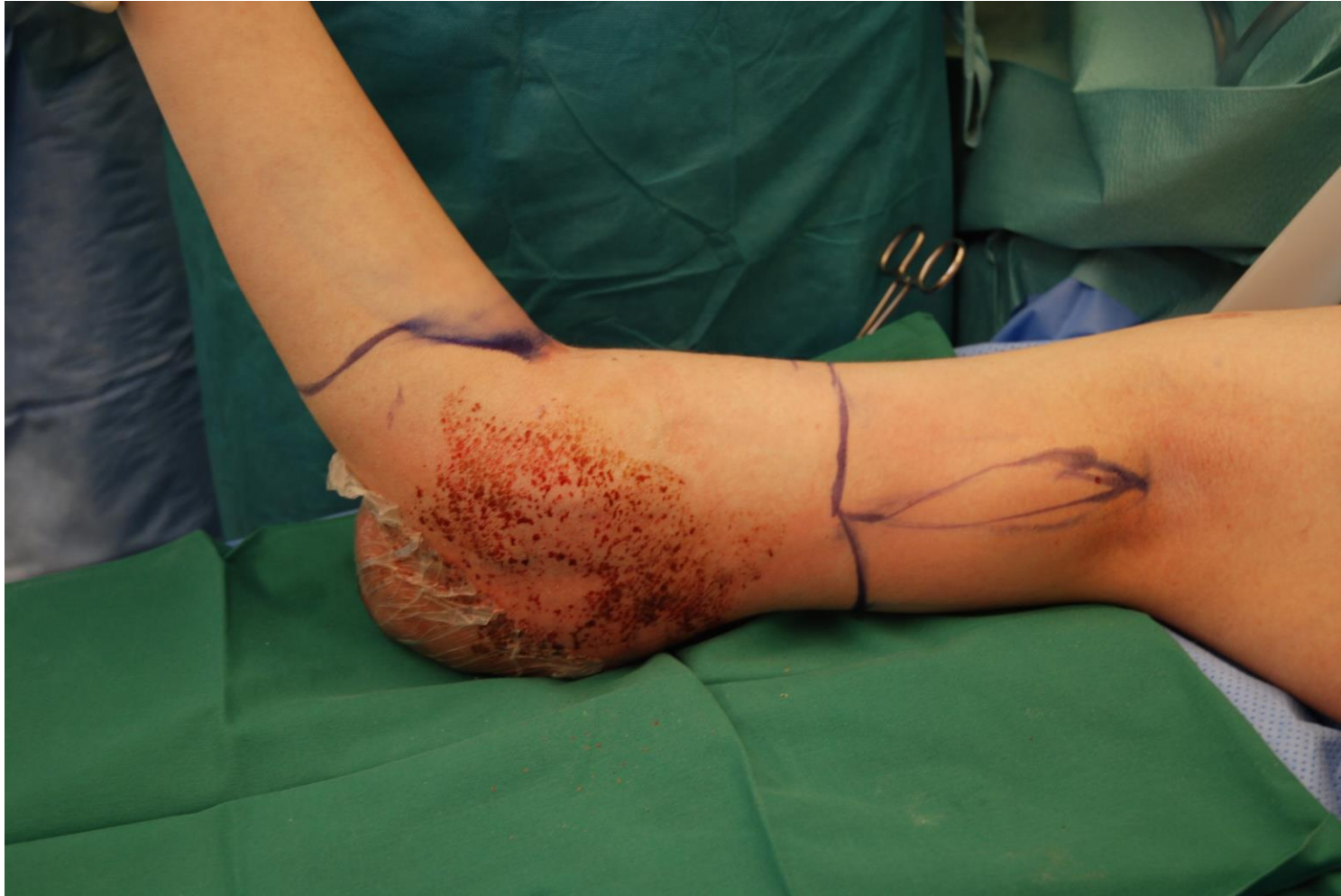# elbow; intercalary resection replantation Surgery: March 21th, 2012



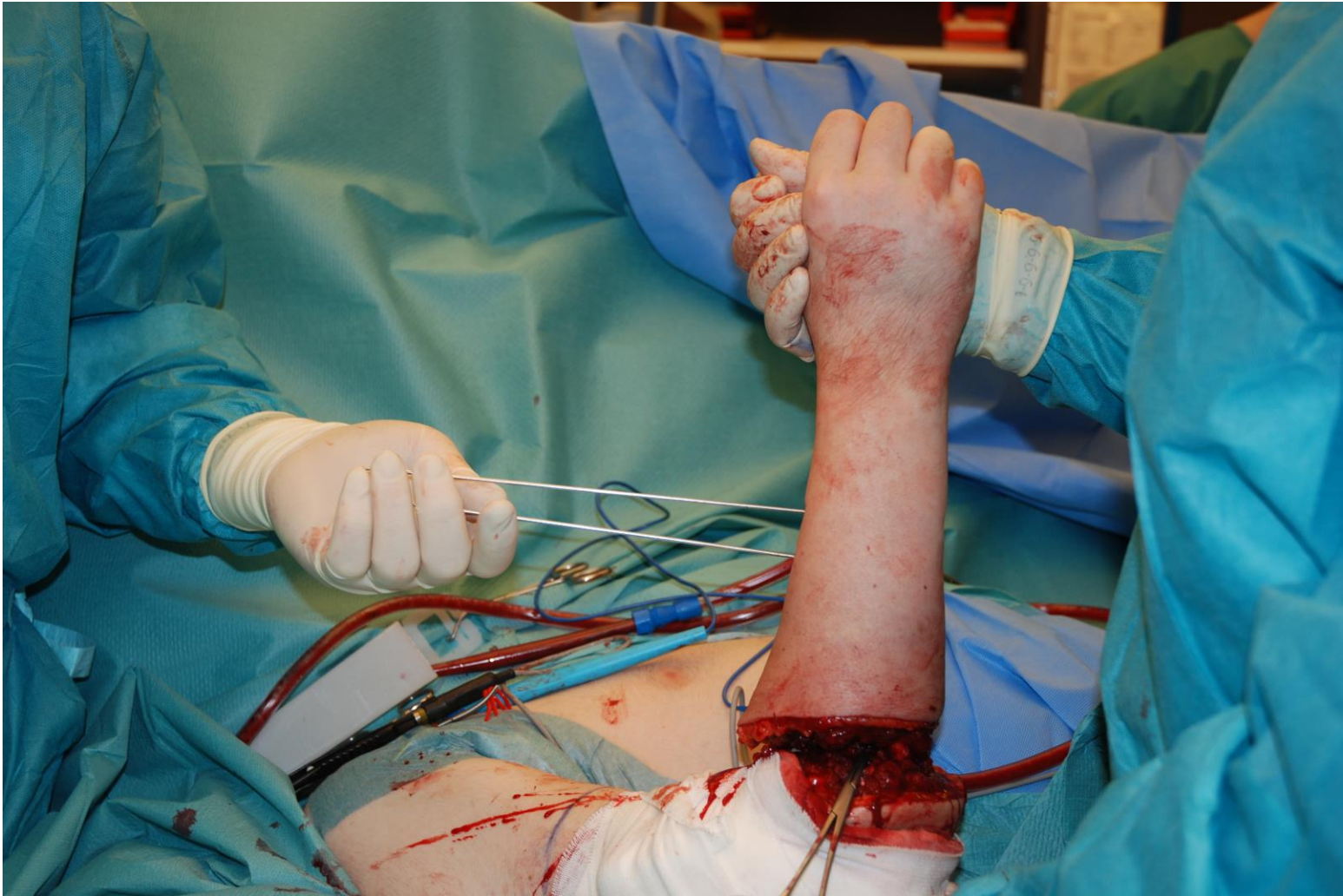# elbow; intercalary resection replantation Surgery: March 21th, 2012



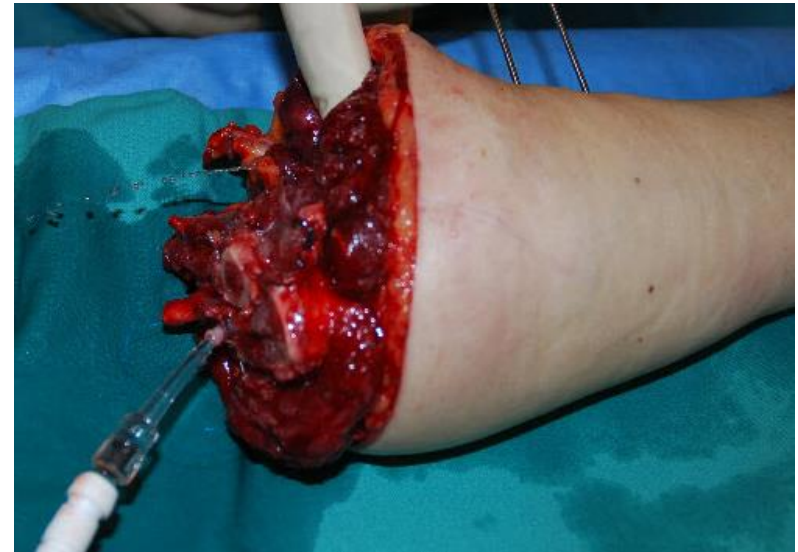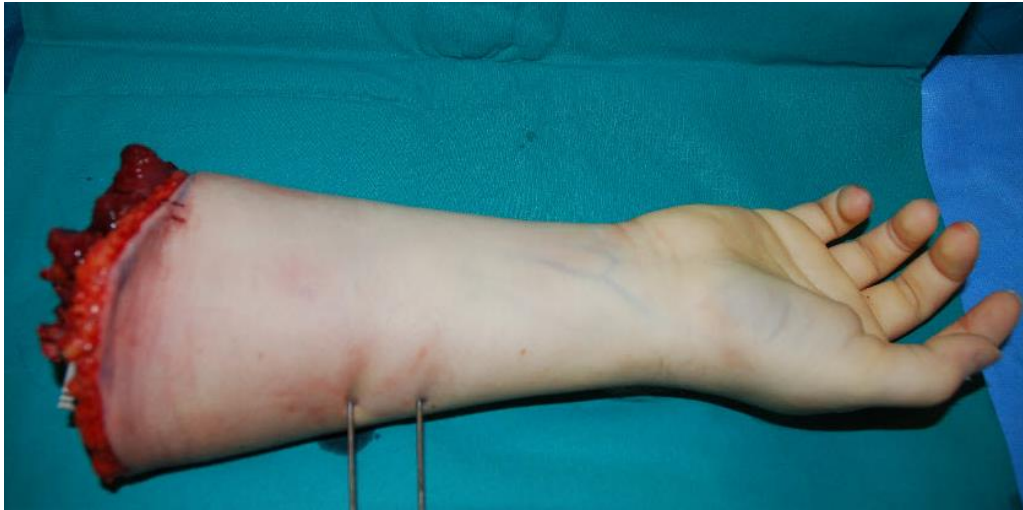# elbow; intercalary resection replantation Surgery: March 21th, 2012



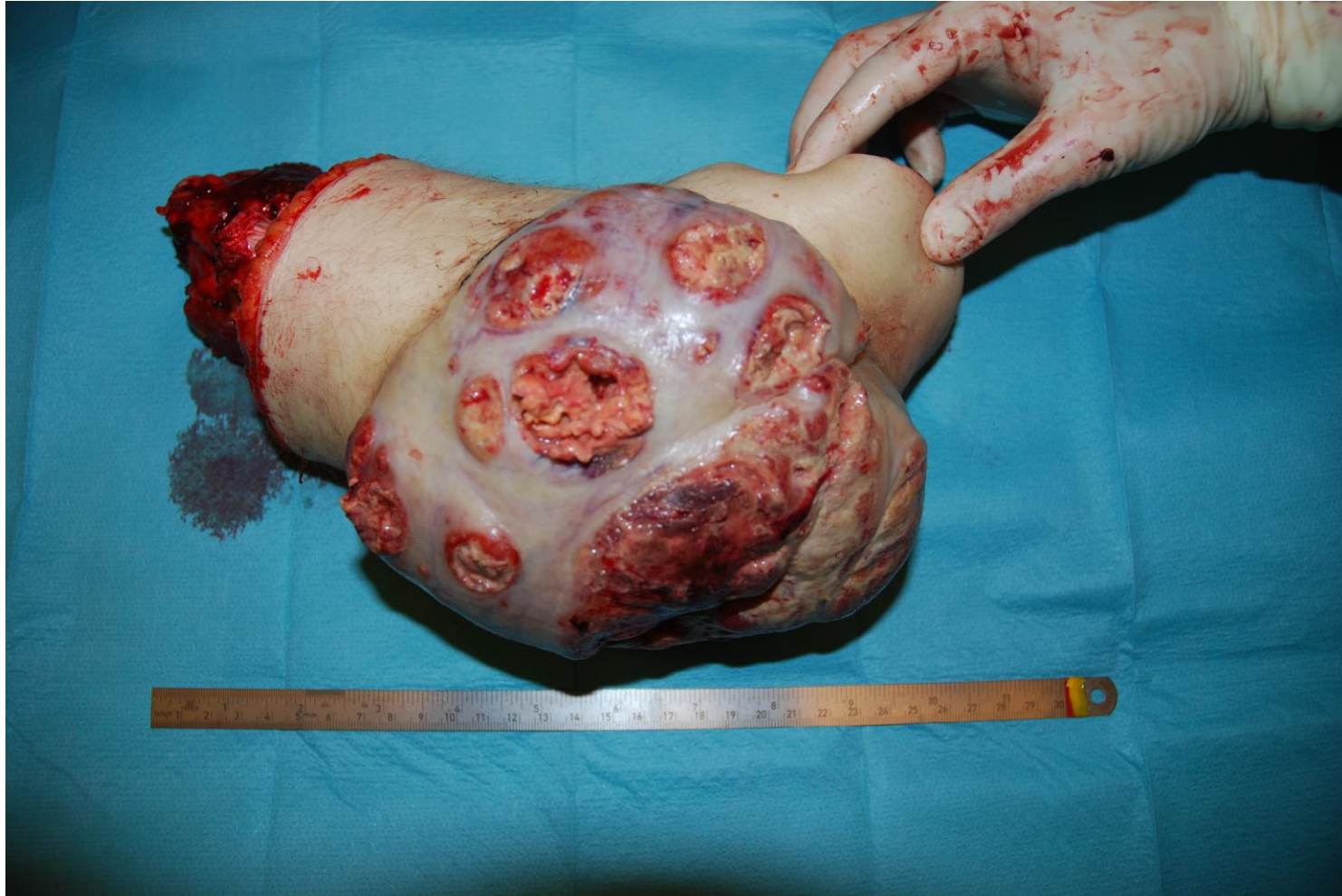# elbow; intercalary resection replantation Surgery: March 21th, 2012



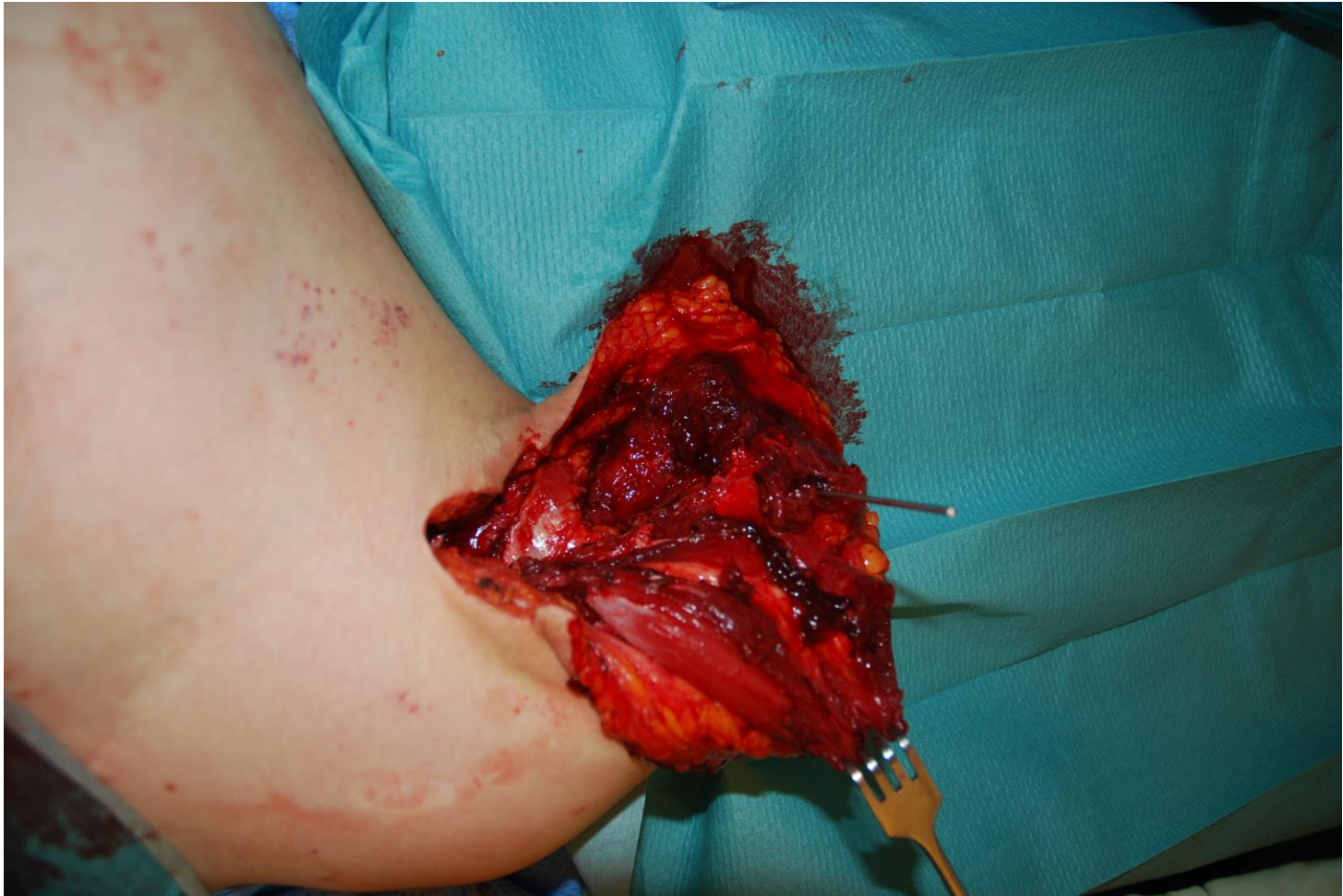# elbow; intercalary resection replantation Surgery: March 21th, 2012



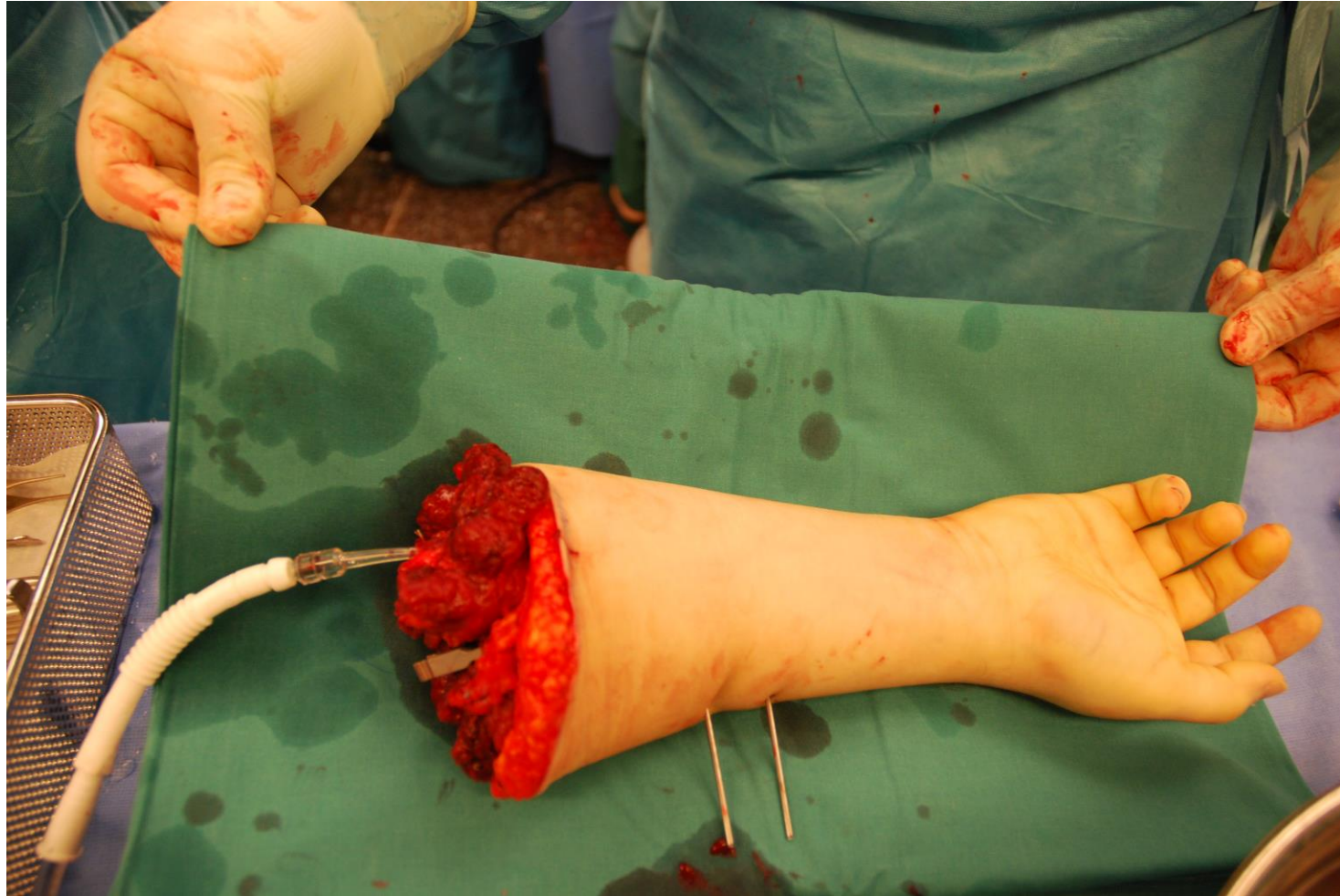# elbow; intercalary resection replantation Surgery: March 21th, 2012



# elbow; intercalary resection replantation Surgery: March 21th, 2012

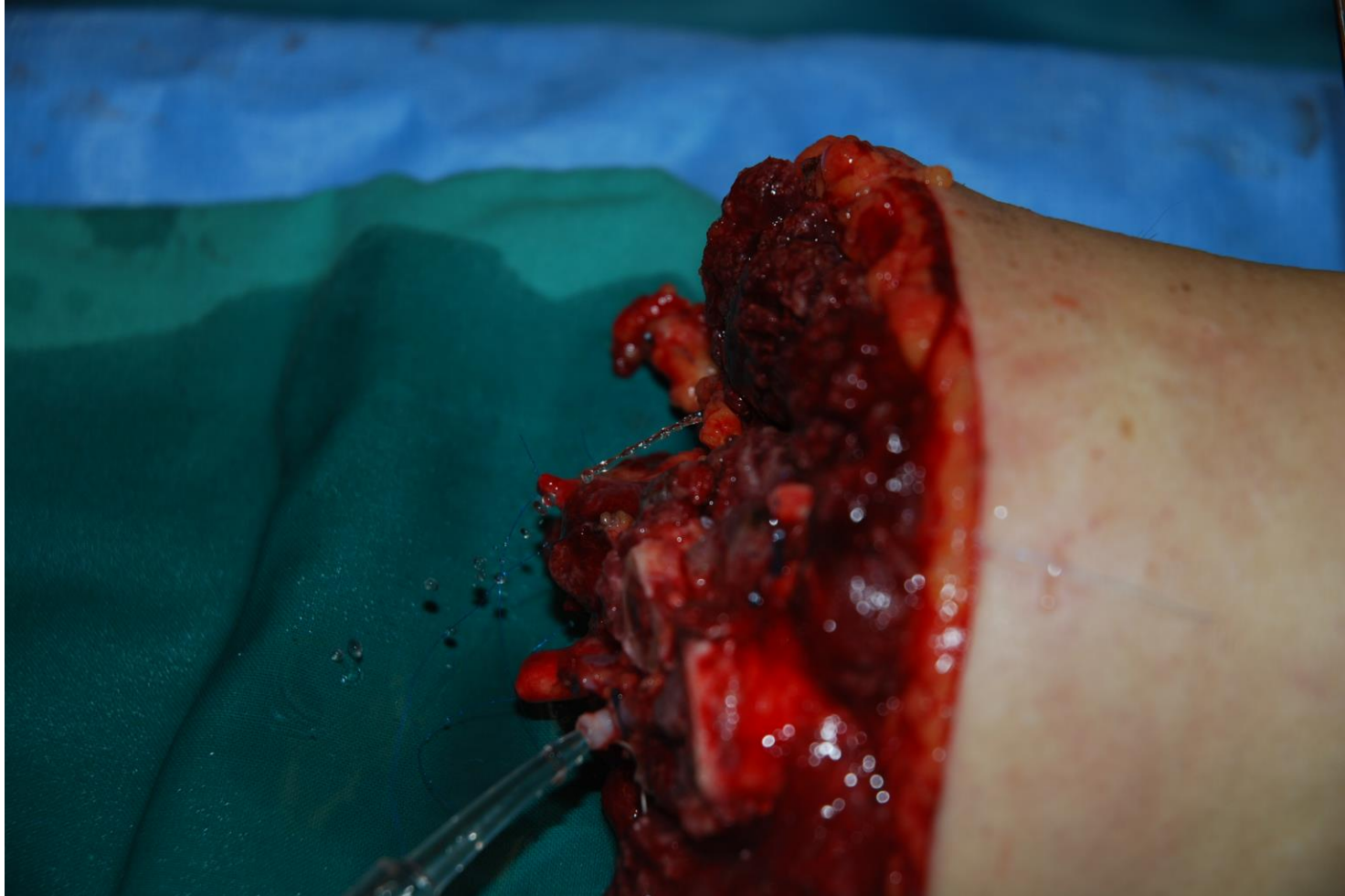

# elbow; intercalary resection replantation Surgery: March 21th, 2012

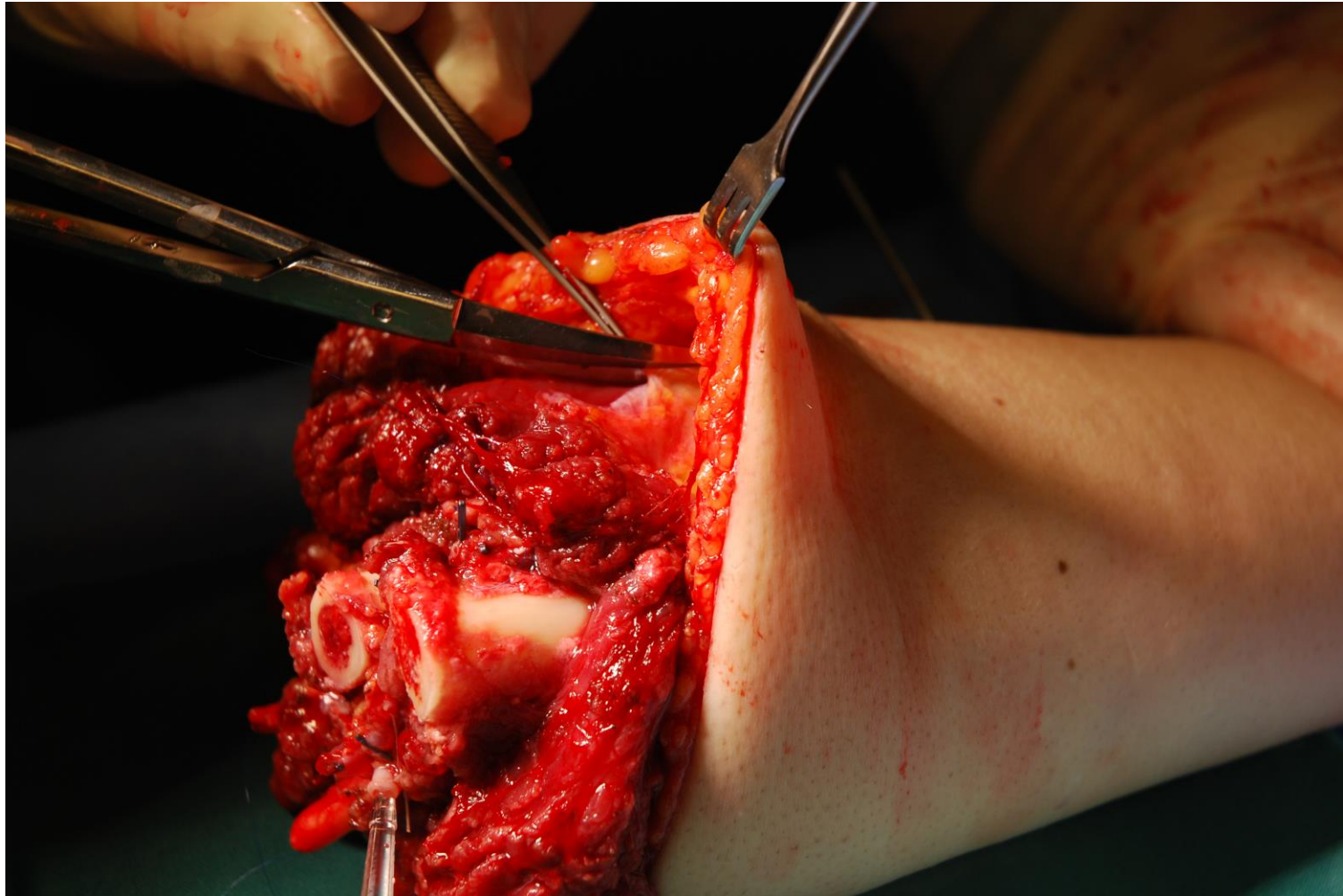




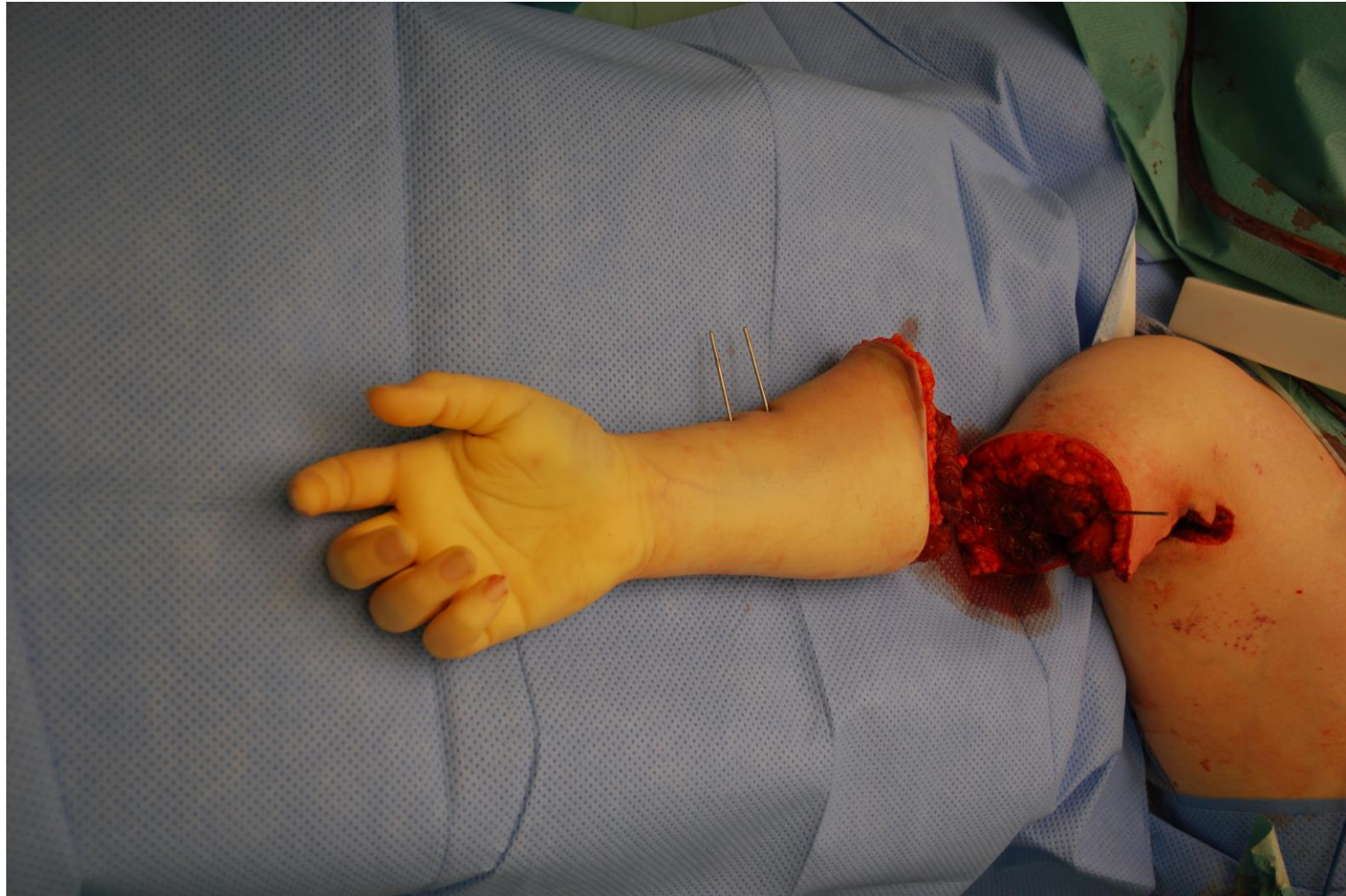# elbow; intercalary resection replantation Surgery: March 21th, 2012



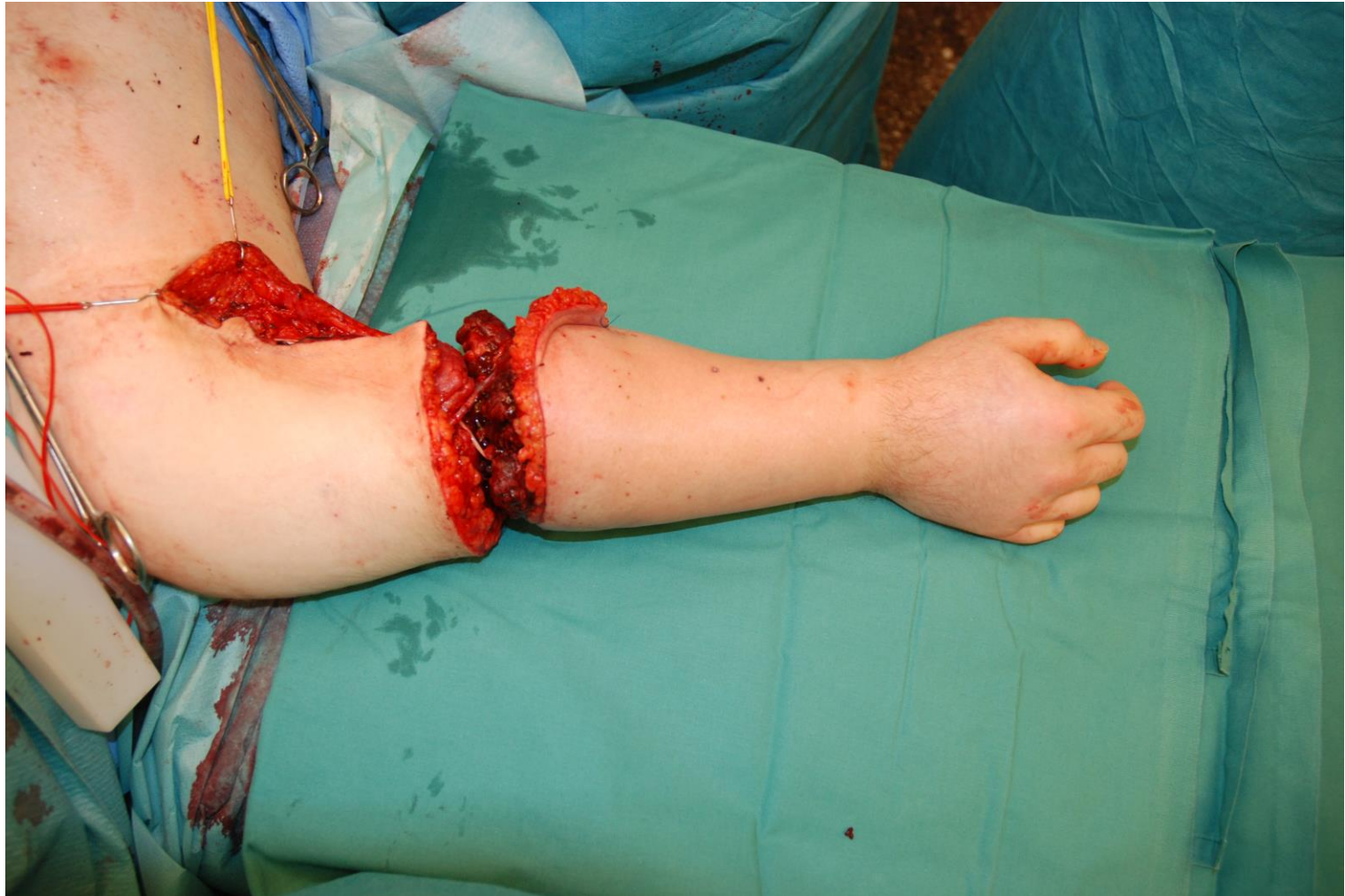# elbow; intercalary resection replantation Surgery: March 21th, 2012



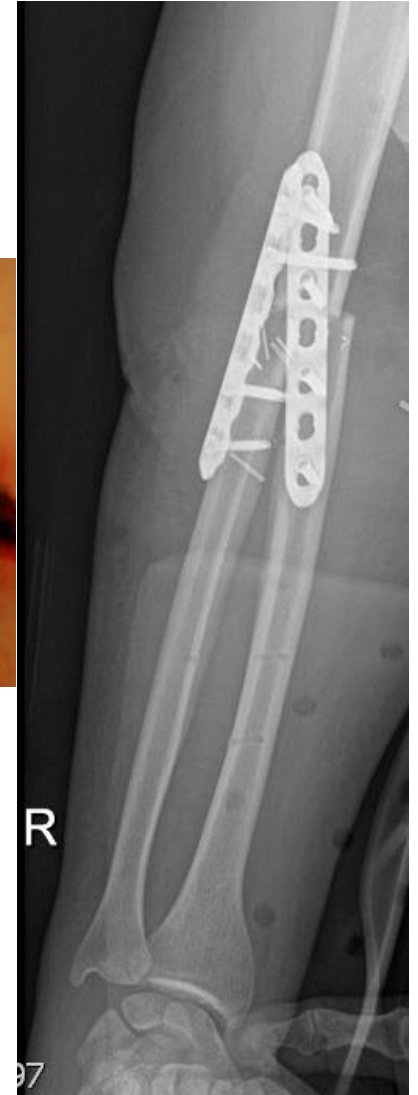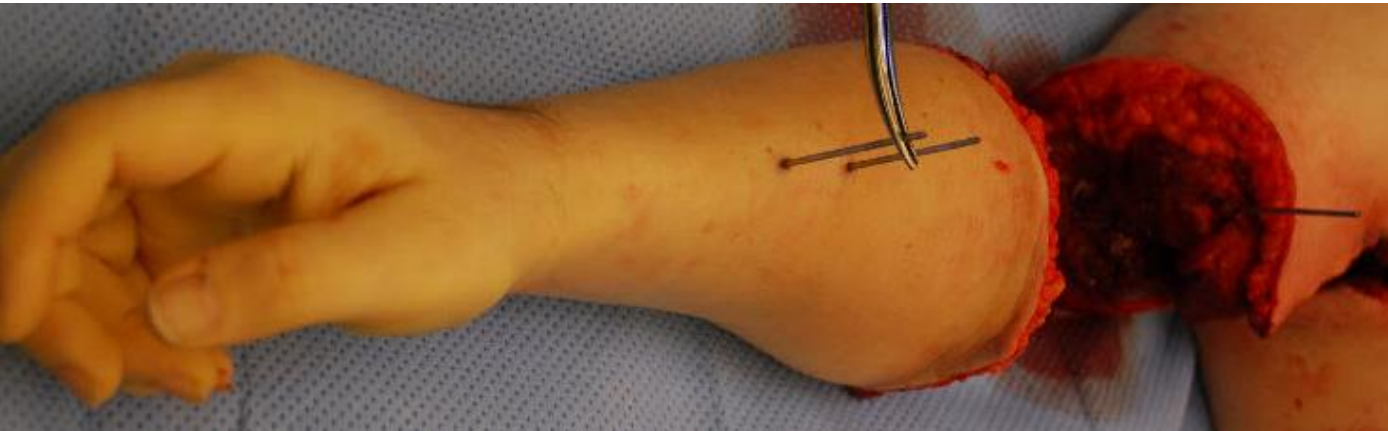# elbow; intercalary resection replantation Surgery: March 21th, 2012



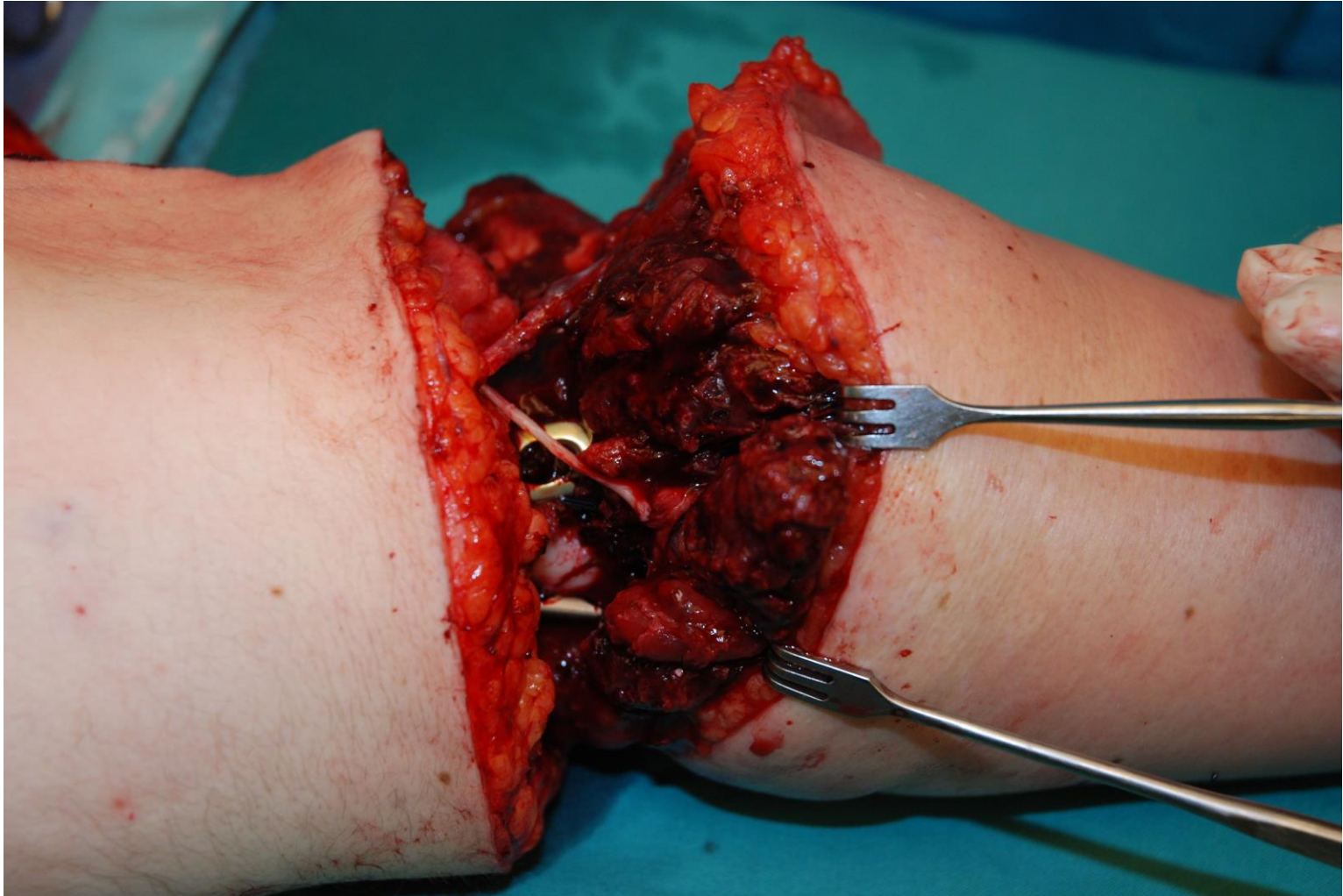
# elbow; intercalary resection replantation Surgery: March 21th, 2012



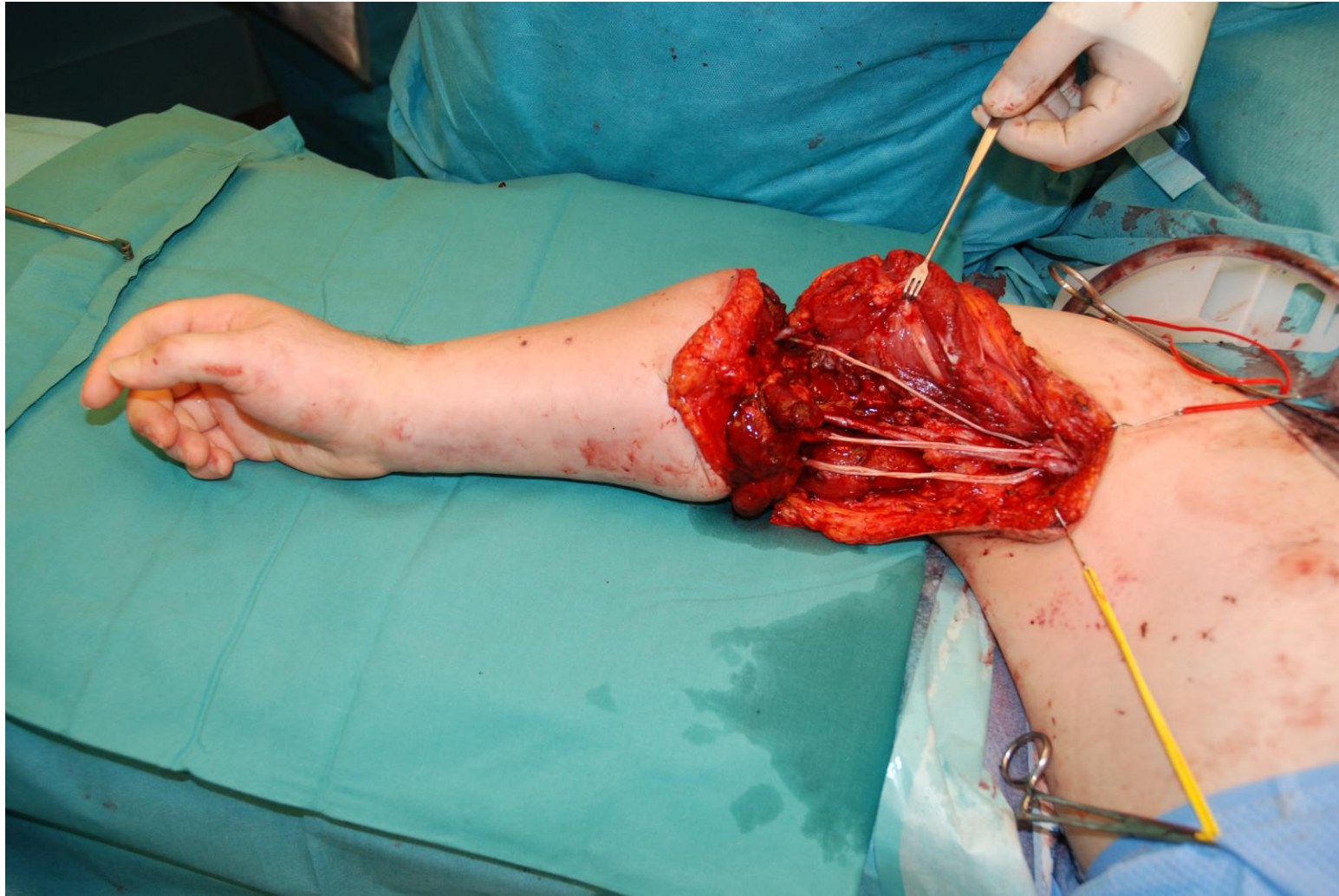# elbow; intercalary resection replantation Surgery: March 21th, 2012



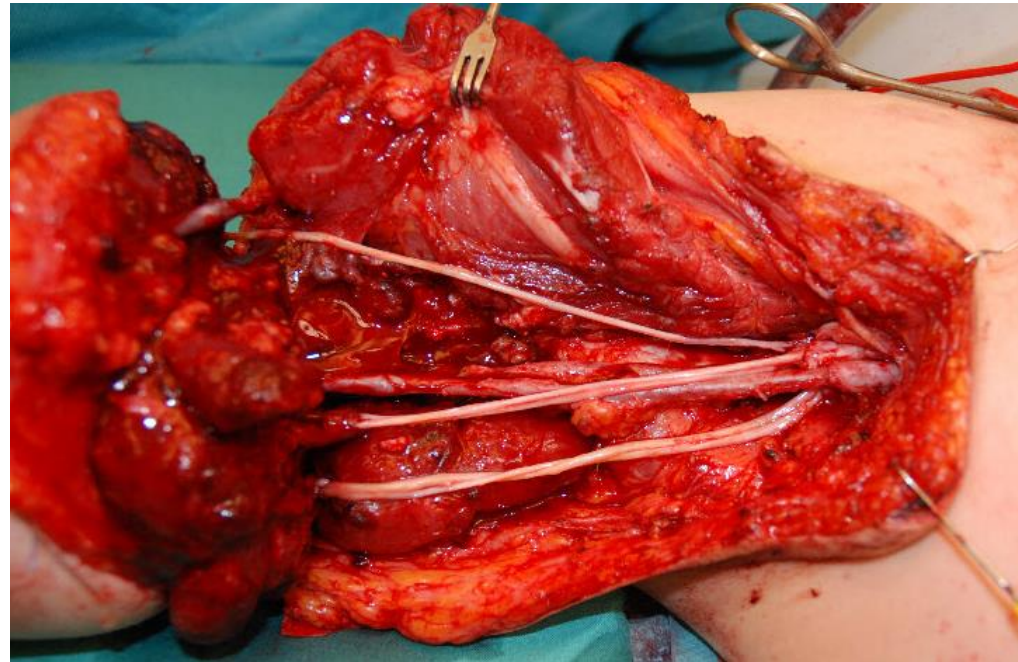
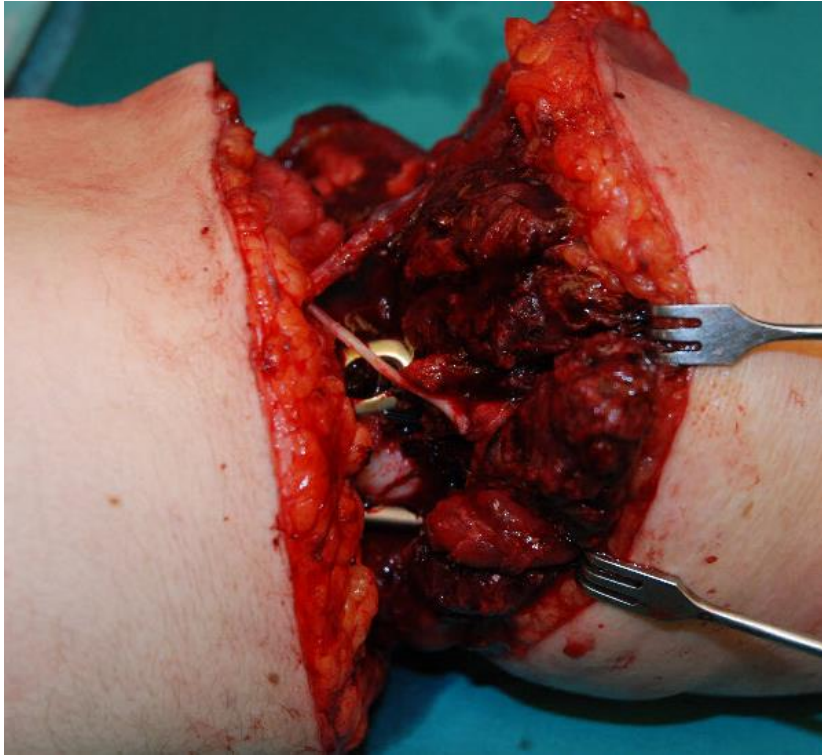
# elbow; intercalary resection replantation Surgery: March 21th, 2012



# elbow; intercalary resection replantation Surgery: March 21th, 2012



# elbow; intercalary resection replantation Surgery: March 21th, 2012





# **elbow; intercalary resection replantation**

## **Surgery: March 21th, 2012**

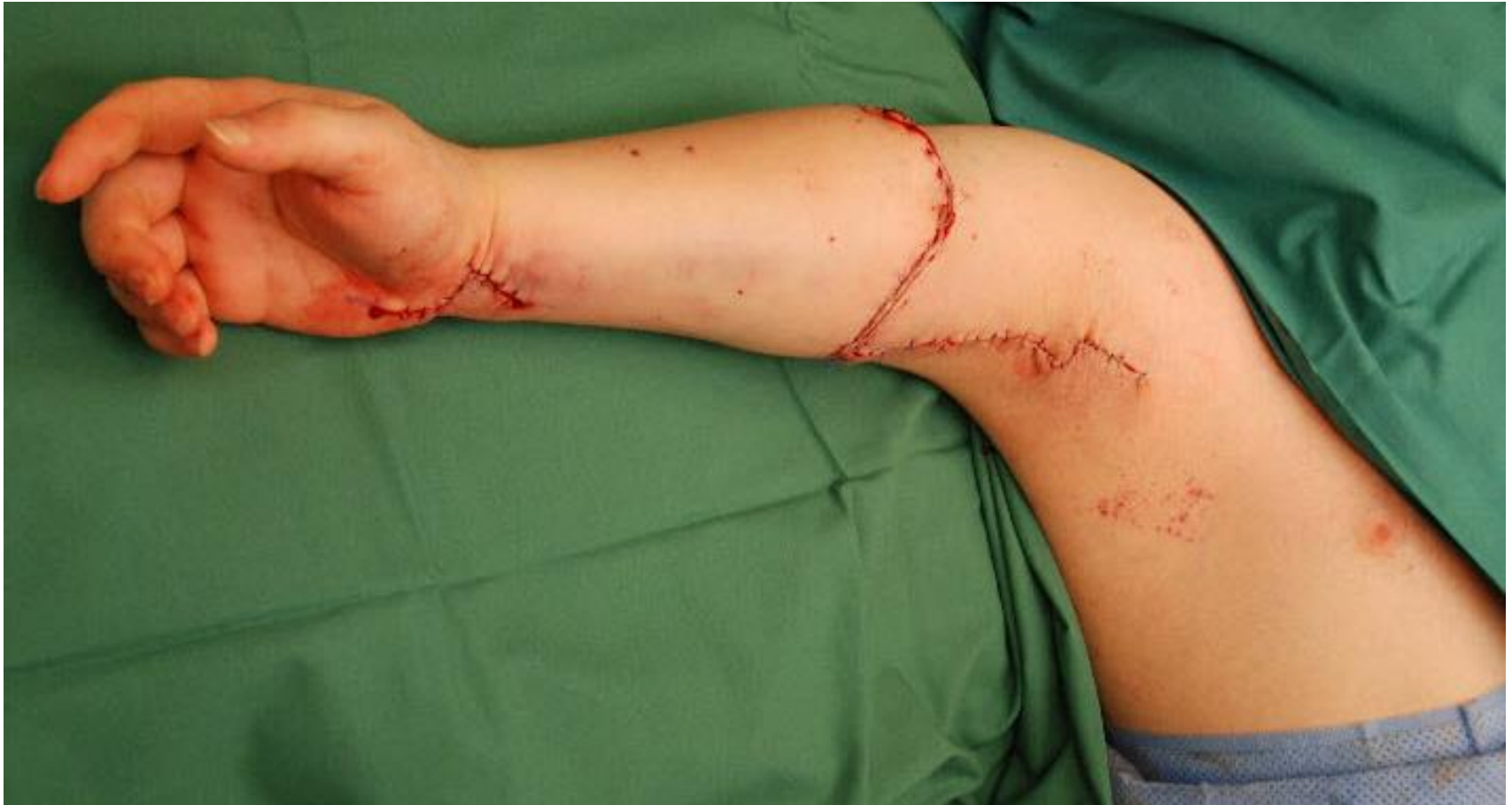# **elbow; intercalary resection replantation**

## **Surgery: March 21th, 2012**

# **elbow; intercalary resection replantation**

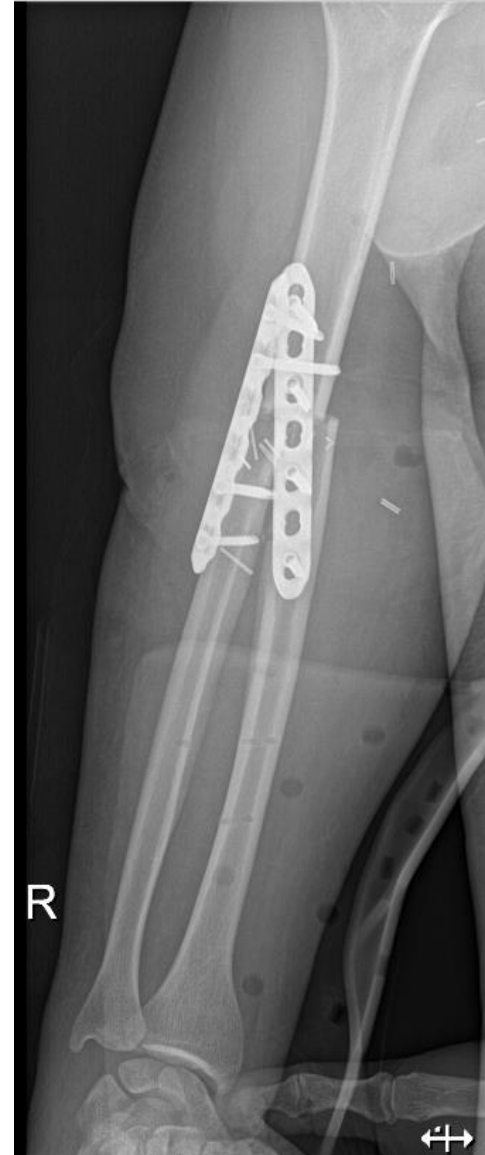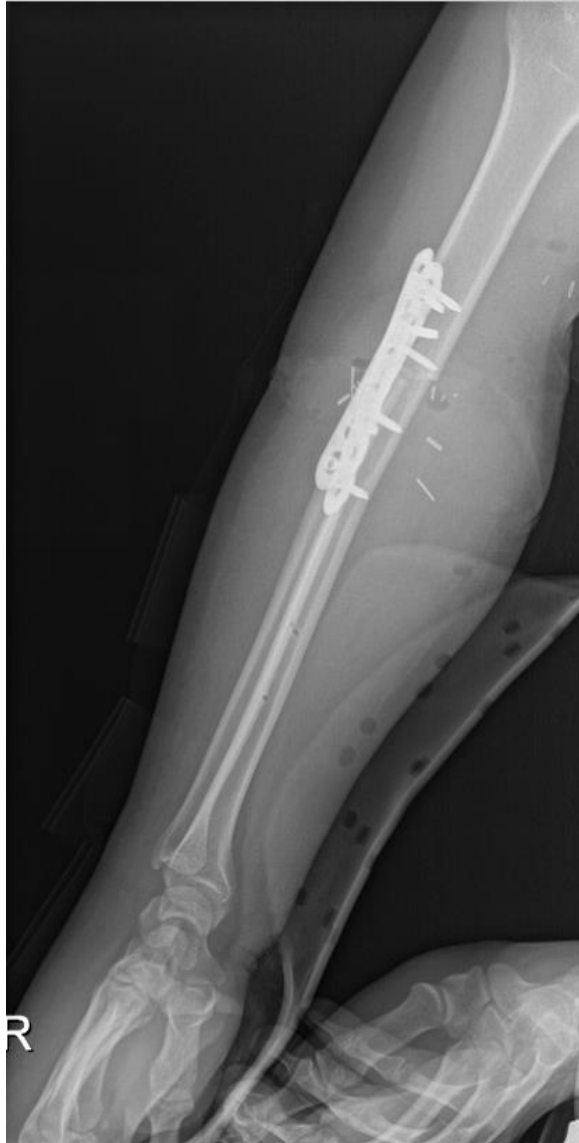## **Surgery: March 21th, 2012**

# elbow; intercalary resection replantation Surgery: March 21th, 2012



# elbow; intercalary resection replantation

## Xray: March 25th, 2012



# elbow; intercalary resection replantation Surgery: March 21th, 2012

Entnahme: 21.03.2012

Eingang: 21.03.2012

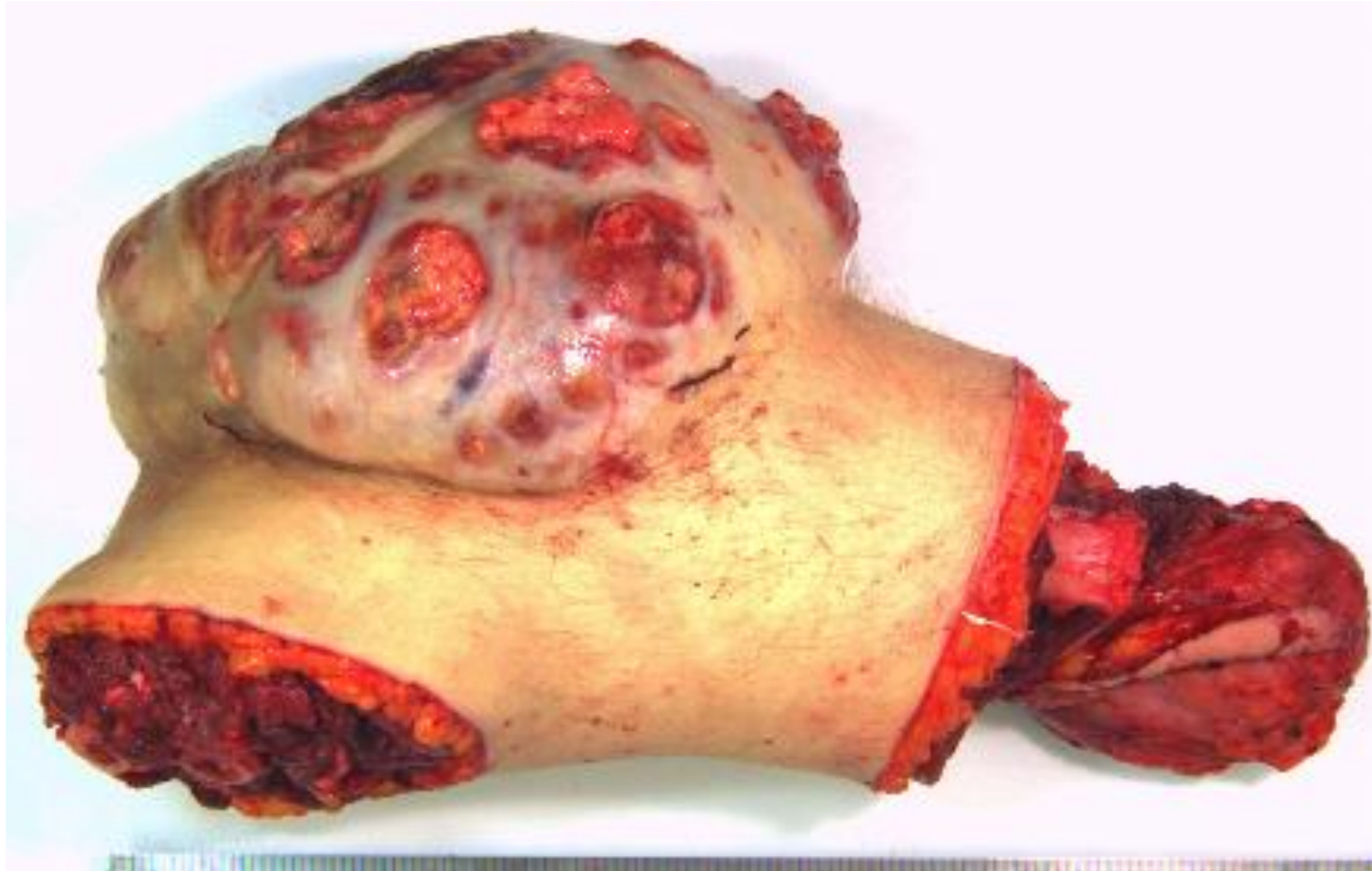## *Klinische Angaben*

Histiozytäres Sarkom nach akut lymphatischer Leukämie. St. .n. Radiotherapie 30 Gy (2008).  
Histologie, in toto , Randbildung.

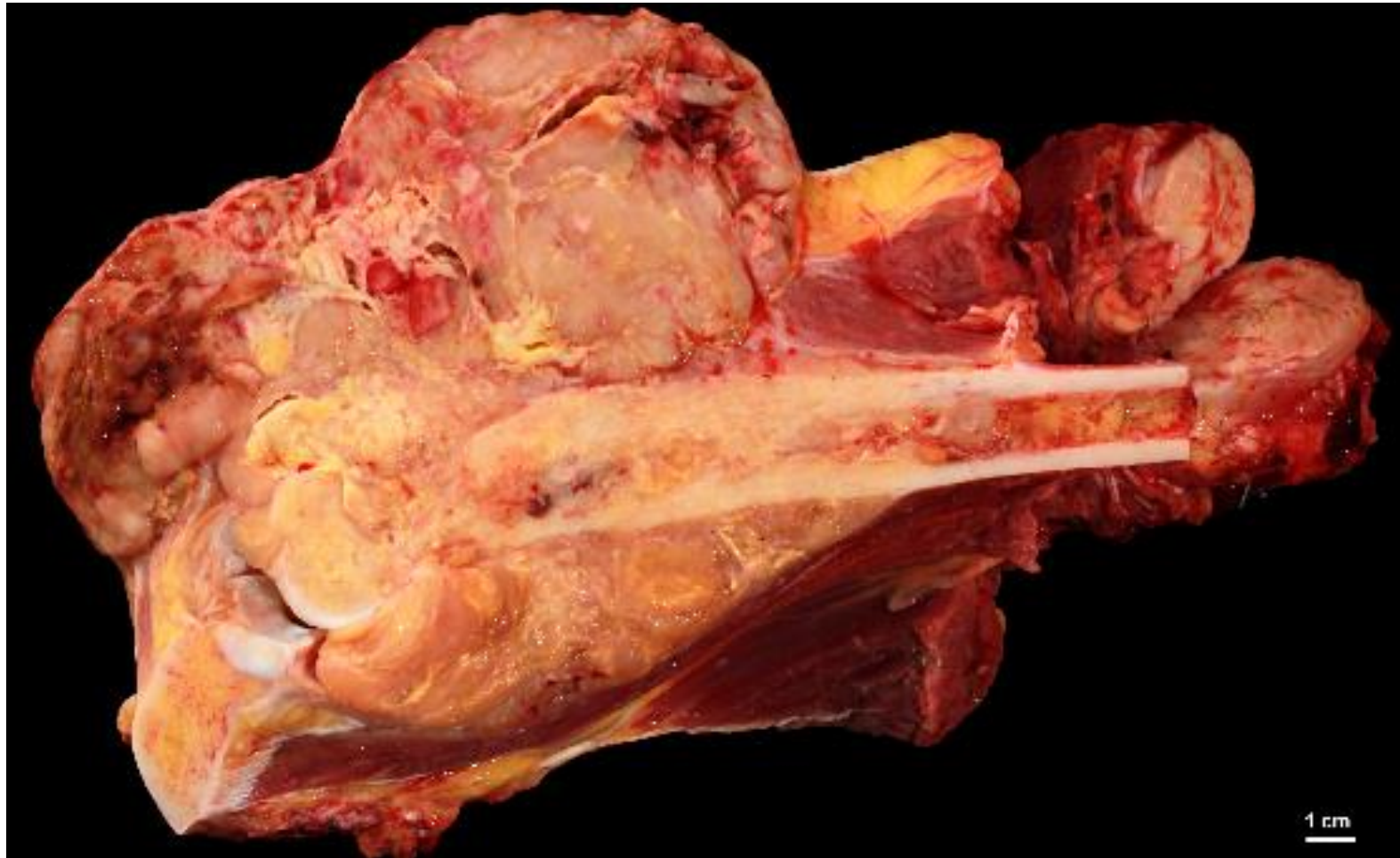## *Angaben zur Probe*

Resektat Oberarm/Ellbogen/prox. Unterarm rechts

# elbow; intercalary resection replantation Surgery: March 21th, 2012



# elbow; intercalary resection replantation Surgery: March 21th, 2012





# elbow; intercalary resection replantation Surgery: March 21th, 2012

Entnahme: 21.03.2012

Eingang: 21.03.2012

## ***Diagnose***

Teilamputat des rechten Oberarmes/Ellbogen/Unterarmes mit ausgedehntem, teils nekrotischem (ca 30% Nekrose), grossflächig exulzeriertem histiozytärem Sarkom, high grade (18,0 cm gross) im Bereiche des distalen Humerus und der Oberarm-/Ellbogen-Weichteile mit Einbruch ins Gelenk. Weiterer 6.5 cm grosser Tumorherd in den proximalen, en bloc mitresezierten Weichteilen.

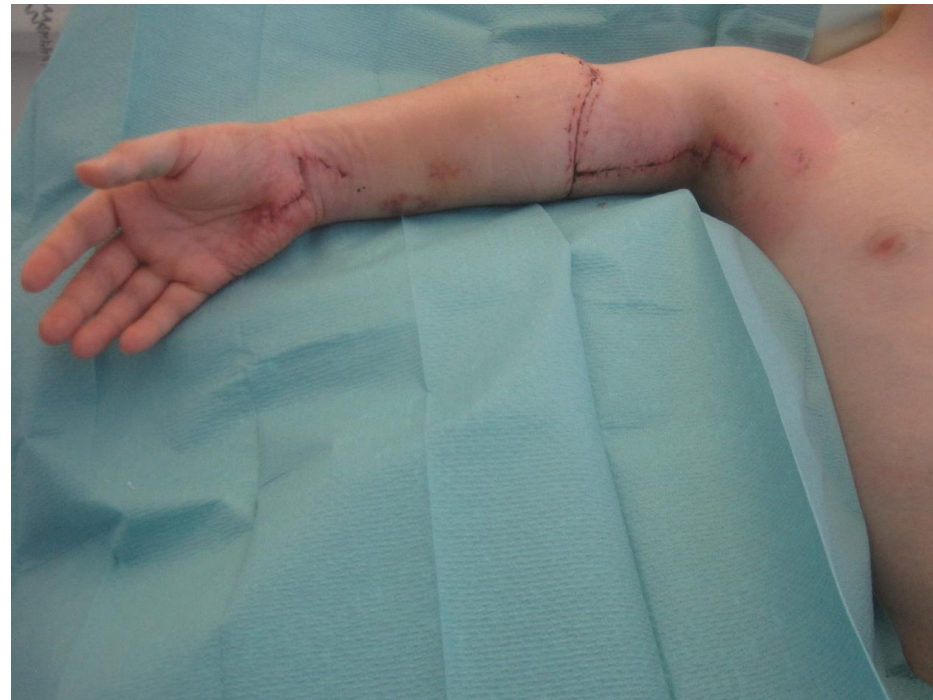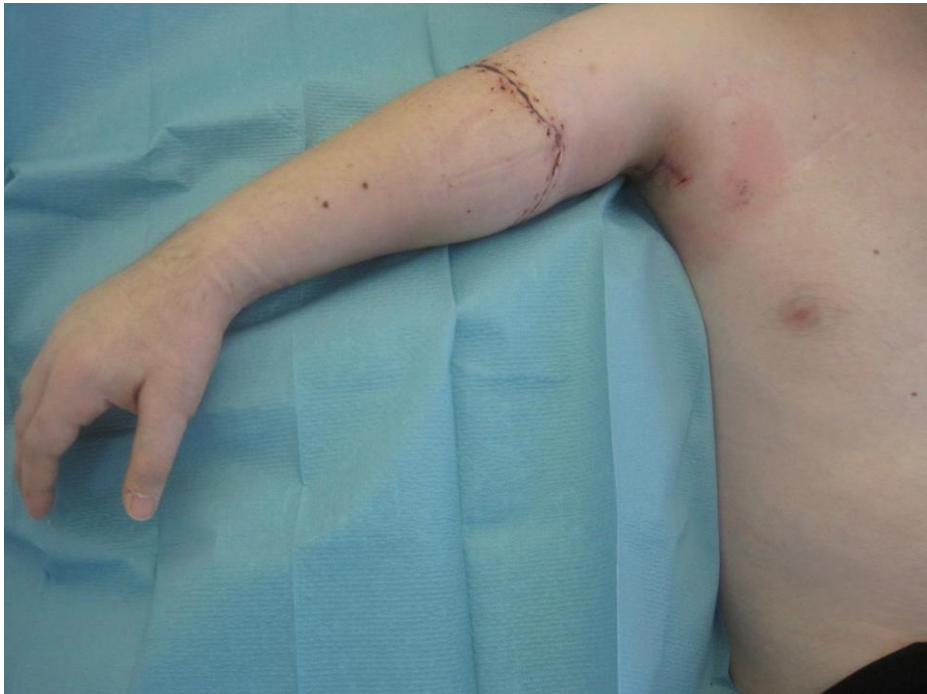Tumorfreier proximaler und distaler Knochen/Haut/Weichgewebs- und Gefässabsetzungsrand. Der minimale Abstand zum proximalen Resektatrand 3,5cm (Haut 4,2 cm) und zum distalen Resektatrand 4,5 cm. Miterfasst zwei tumorfremie Lymphknoten (0/2).

## **vgl. Kommentar**

### *Kommentar*

Die histogenetische Einteilung dieses ungewöhnlichen, hochgradig malignen Tumors wurde ausführlich mit der auf dem Gebiet der Hämatopathologie in unserem Institut spezialisierte Kollegin, Frau Dr. E. Haralambieva diskutiert. In ihrer Beurteilung muss man angesichts der Anamnese der ALL auf das Vorliegen einer ALL-assoziierten, genetisch verwanten histiozytären Neoplasie schliessen (vgl. Castro *et al.*, *Pediatr Dev Pathol*, 2010; 13:225-37). Diese Vermutung ist durch den zwischenzeitlichen Nachweis im vorliegenden Tumorgewebe der gleichen genetischen Rearrangierung wie bereits in der beim Patienten vor 20 Jahrendiagnostizierten ALL bestätigt - vgl. Sie dazu den separaten molekulargenetischen Bericht M12.390.

# elbow; intercalary resection replantation April 5th 2012; 2 weeks postop



# elbow; intercalary resection replantation

## April 5th 2012; 2 weeks postop

