

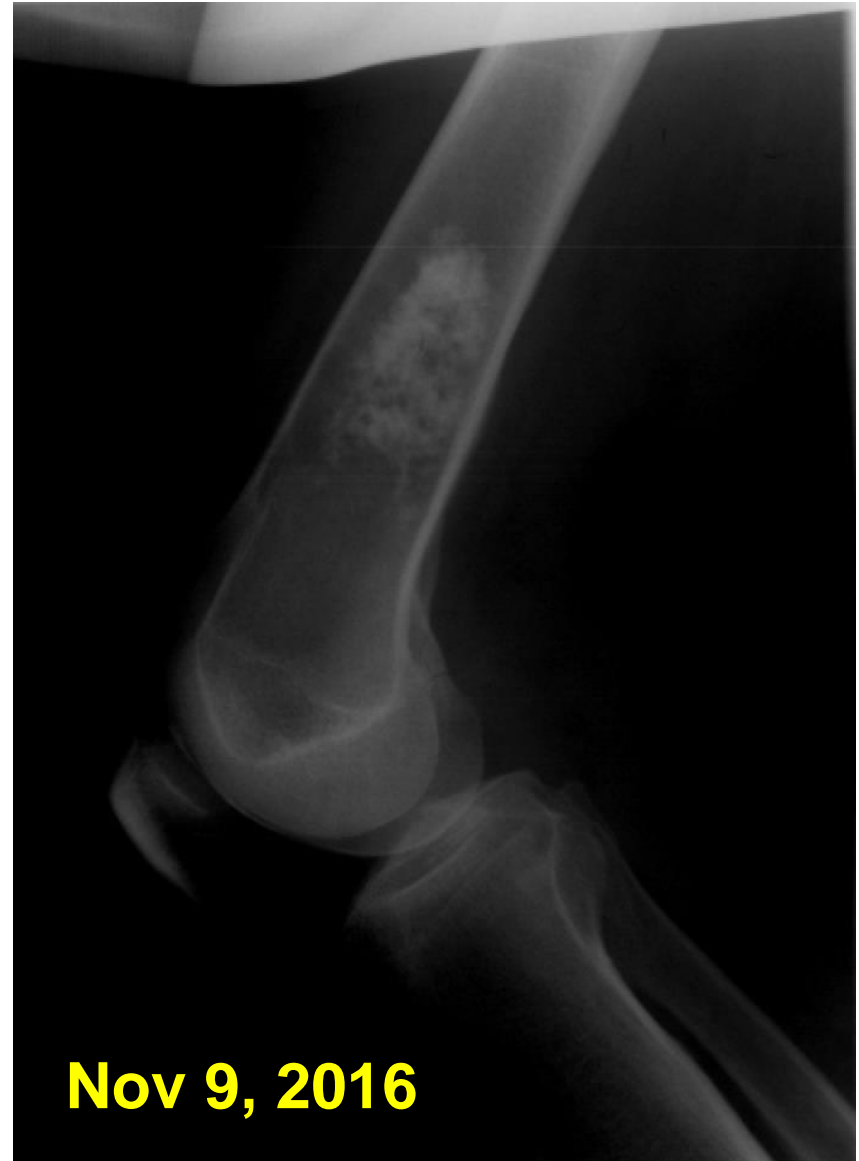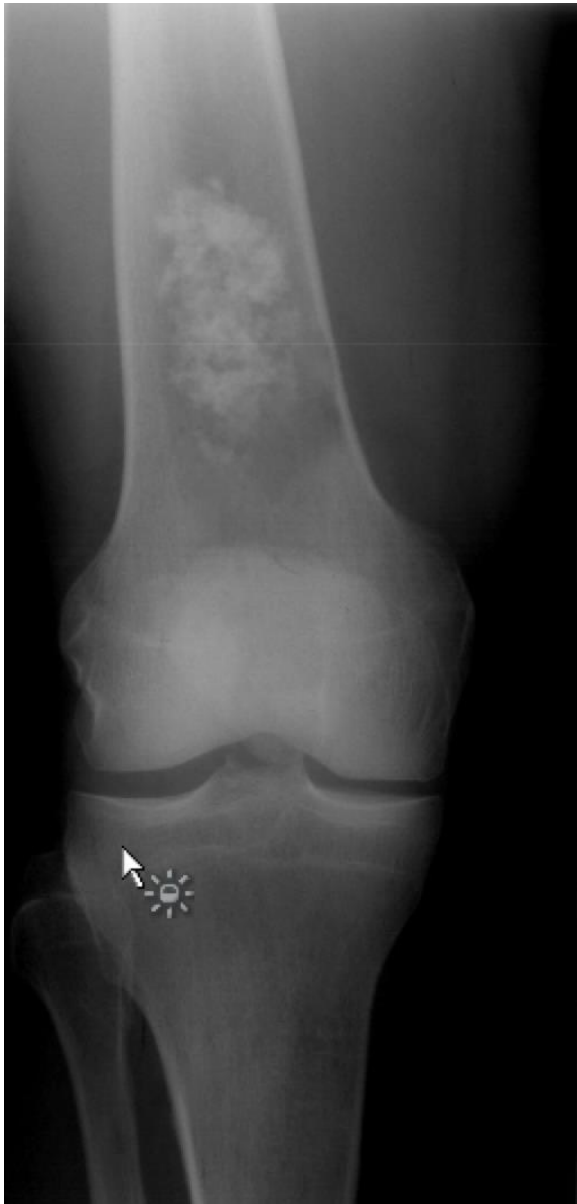distal femur resection / 79yo / m

CC: lump of 15cm for last 6 months
since summer increasing pain while biking
initially.

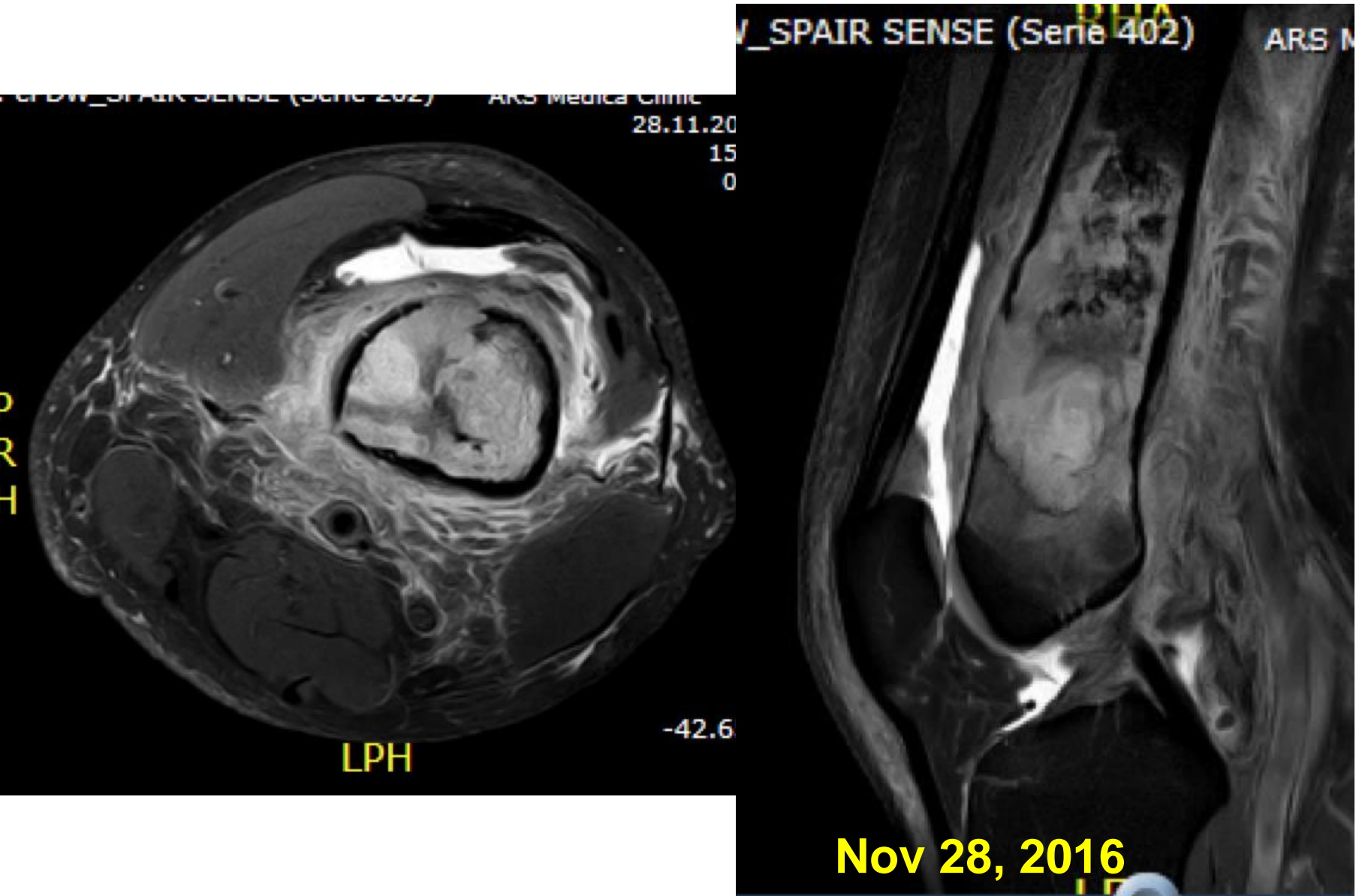
PMH: uneventful

-

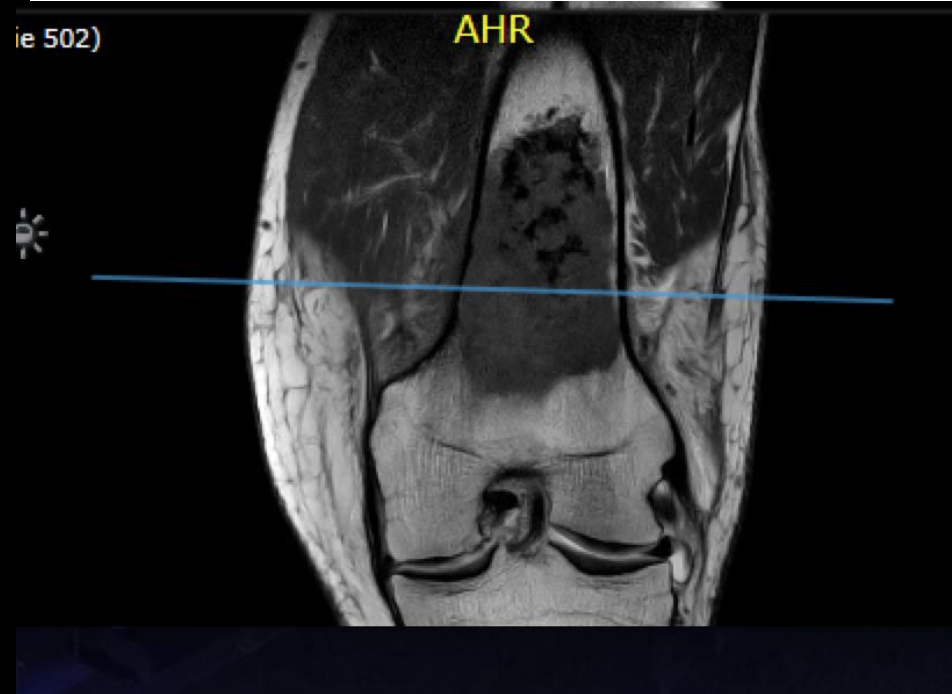
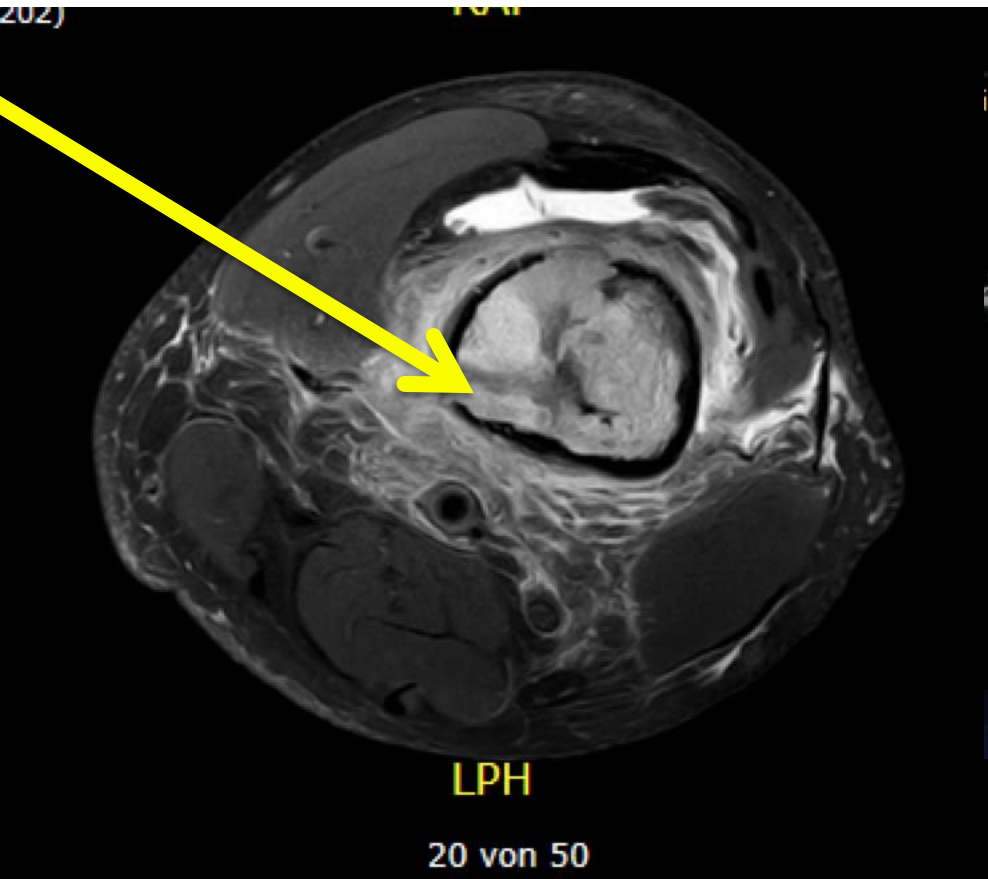
distal femur resection / 79yo / m



distal femur resection / 79yo / m

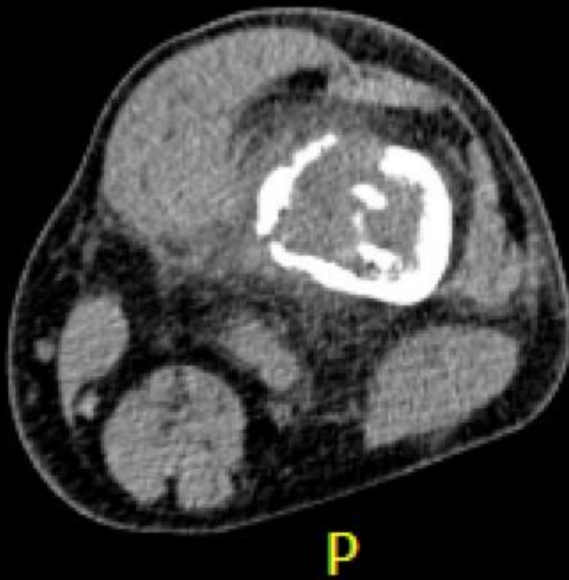

distal femur resection / 79yo / m

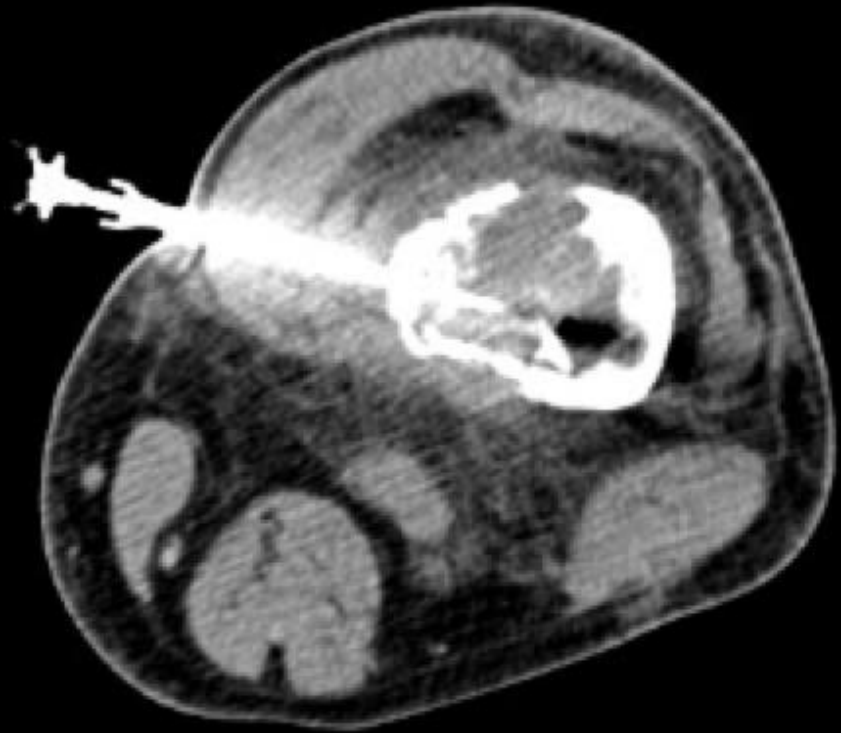


distal femur resection / 79yo / m

- Bx on Dec 22, 2016



R



distal femur resection / 79yo / m

Nachtrag vom 03.01.2017

Das nun entkalkt vorliegendes Gewebe der ersten Fraktion B16.81677 enthält weitere vollständig avitale / nekrotische Infiltrate einer aggressiven, hochgradig malignen Neoplasie, diesmal in der Nachbarschaft zu kleinen Inseln vom Knorpelgewebe. Das nekrotische Gewebe der high grade Neoplasie lässt sich schlecht morphologisch beurteilen (evtl. whs. spindelzellig).

Der Versuch einer Immunhistochemie bleibt angesichts der vollständig nekrotischen Neoplasie inkonklusiv - es findet sich keine offensichtliche Expression von CD45, CD20, PanCK.

Trotz der avitalen Tumorarealen ist die Gesamt-Situation (histologisches Bild / Bildgebung / Klinik) vereinbar mit einem **dedifferenzierten Chondrosarkom**.

Prof. Dr. med. Beata Bode
Leit. Ärztin Tel.: 044 2554051

distal femur resection / 79yo / m

CHAPTER 15

Chondrogenic tumours

Osteochondroma

Chondromas: enchondroma, periosteal chondroma

Chondromyxoid fibroma

Osteochondromyxoma

Subungual exostosis and bizarre parosteal osteochondromatous proliferation

Synovial chondromatosis

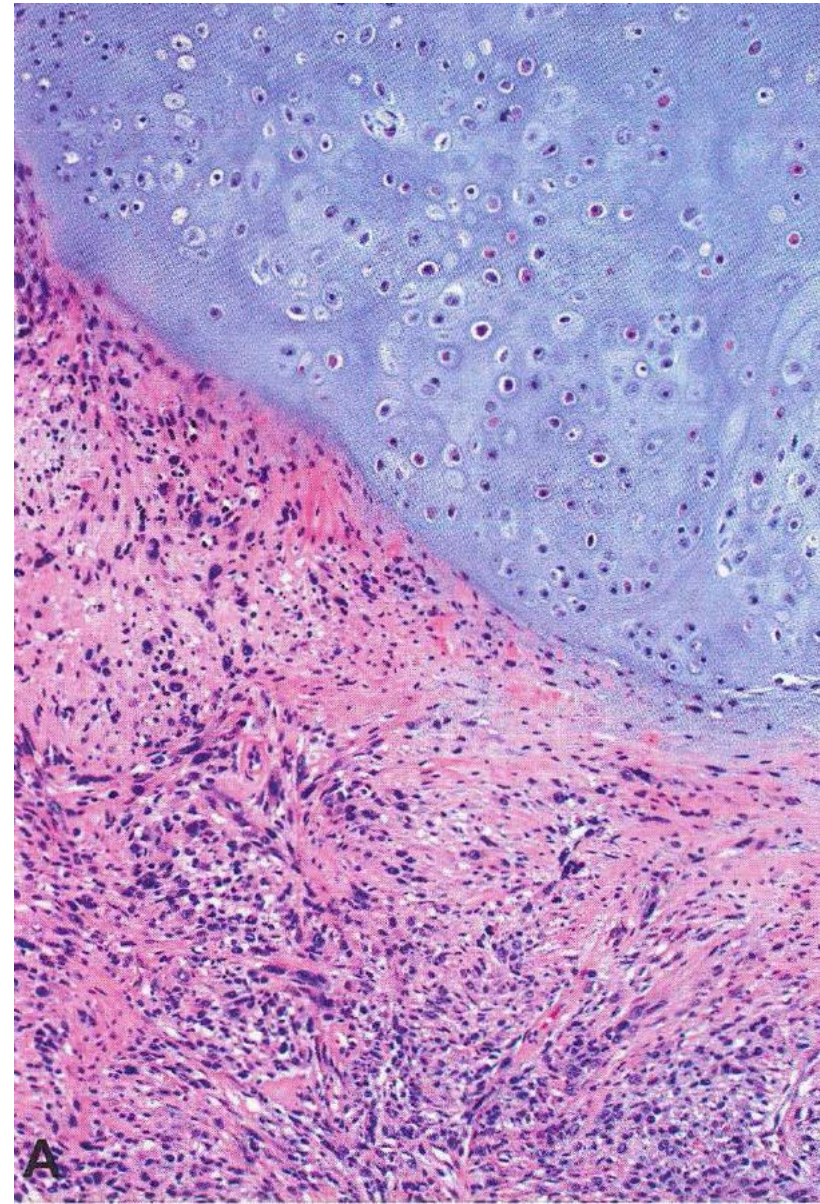
Chondroblastoma

Chondrosarcoma (grades I–III) including primary and secondary variants, and periosteal chondrosarcoma

Dedifferentiated chondrosarcoma

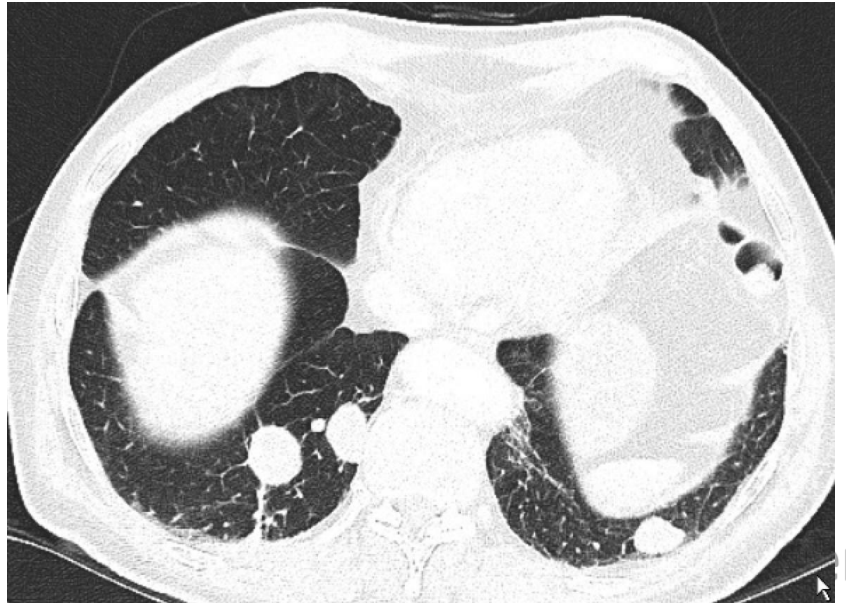
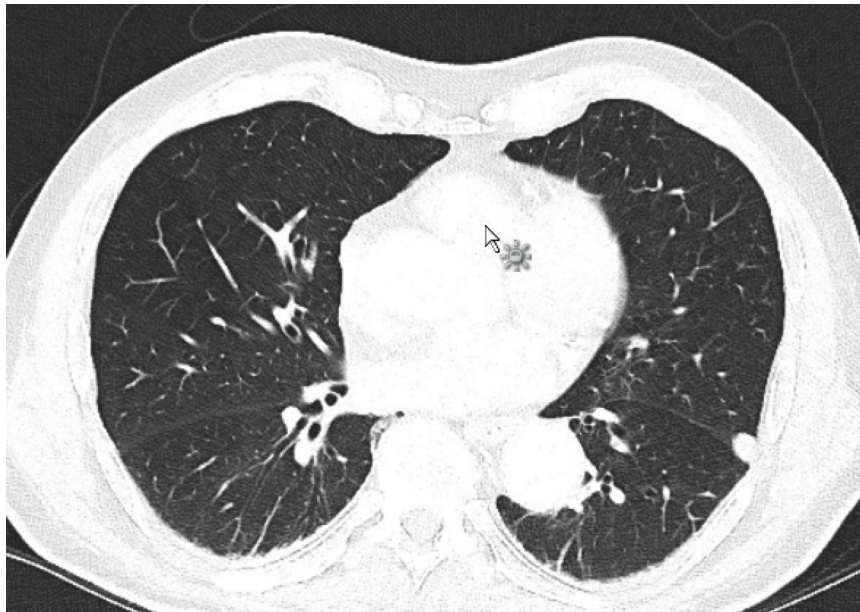
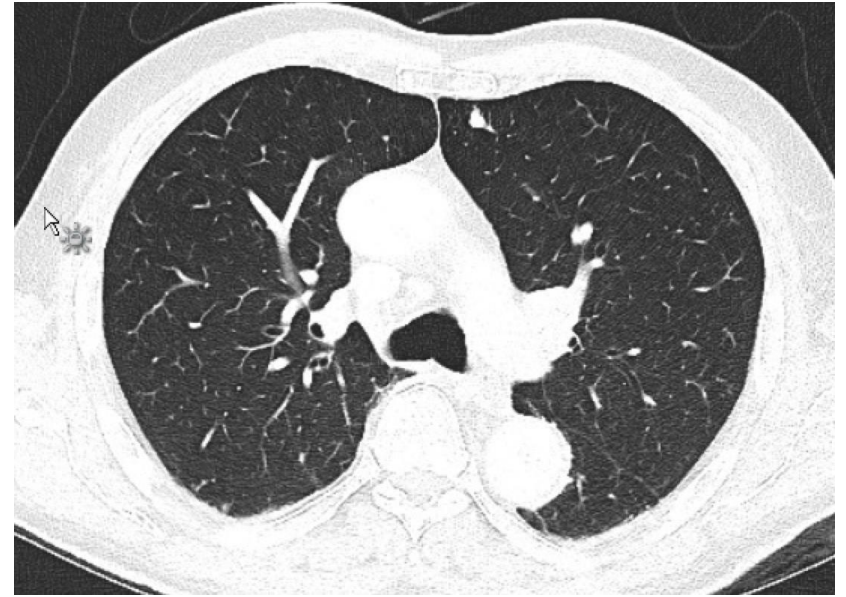
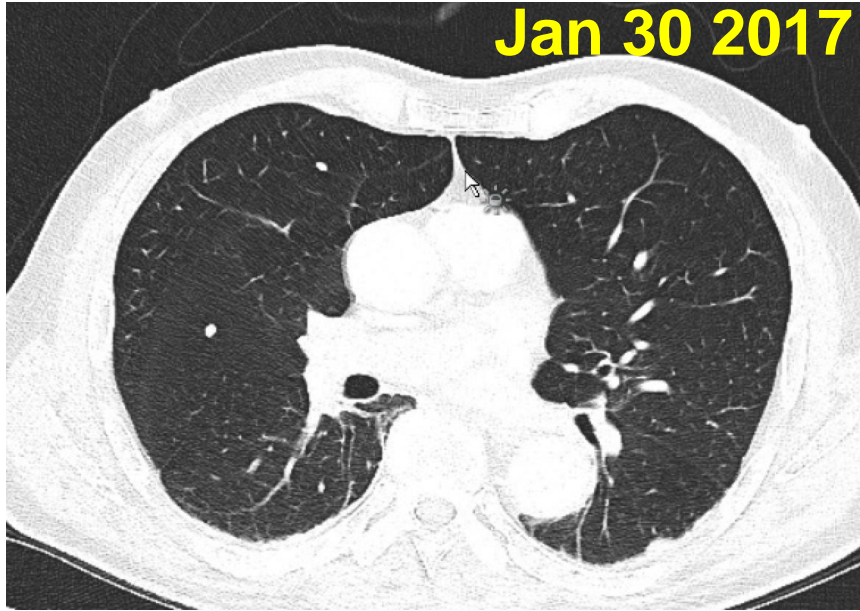
Mesenchymal chondrosarcoma

Clear cell chondrosarcoma

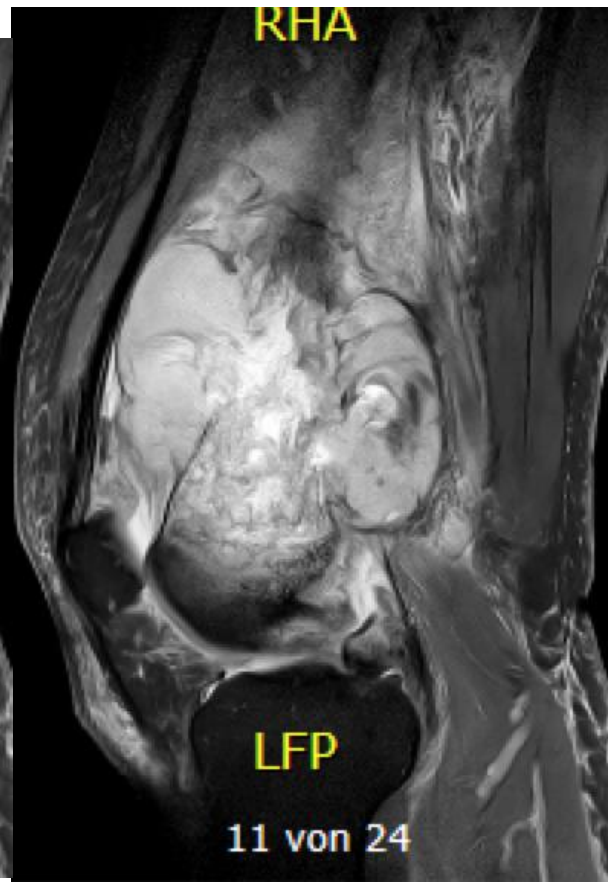
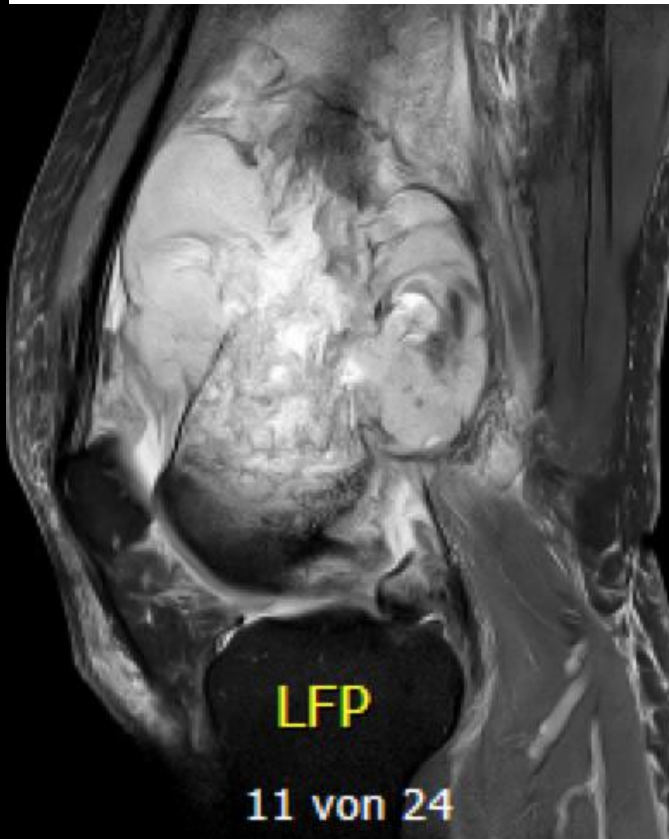
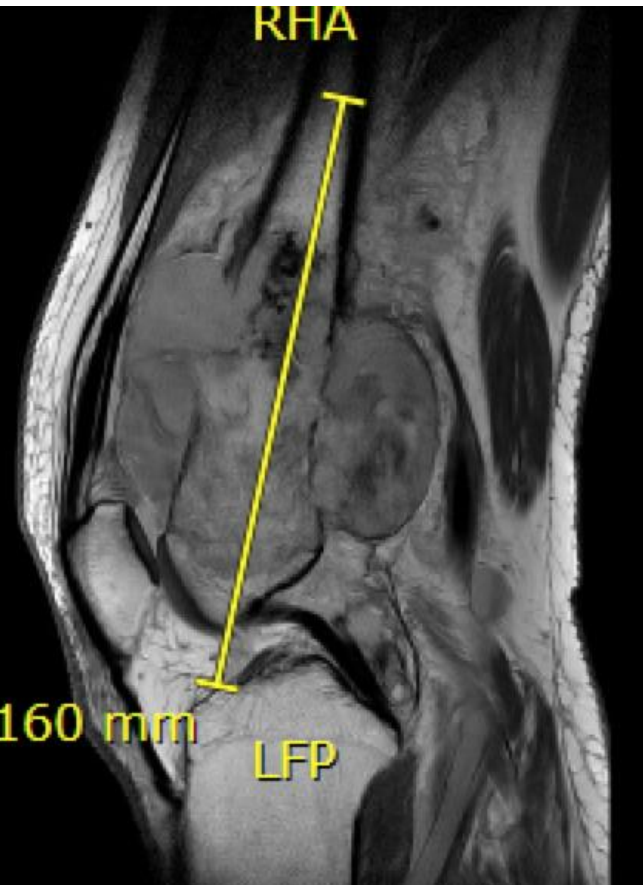


distal femur resection / 79yo / m

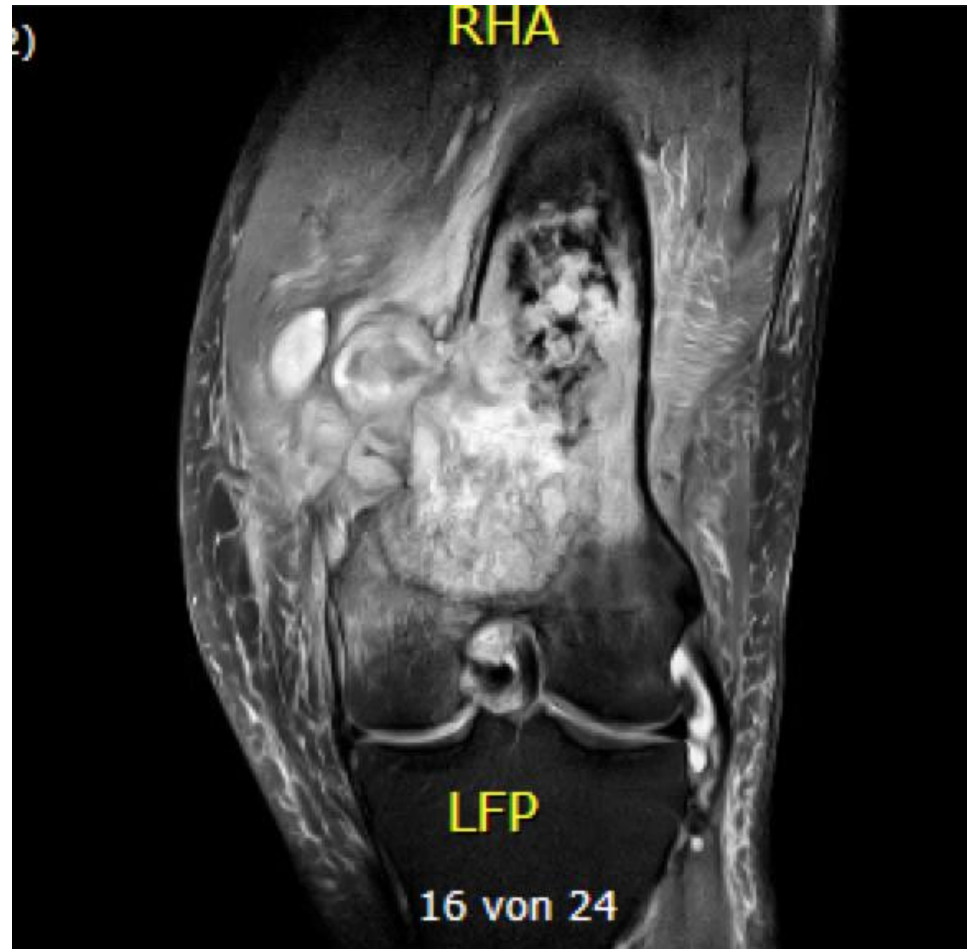
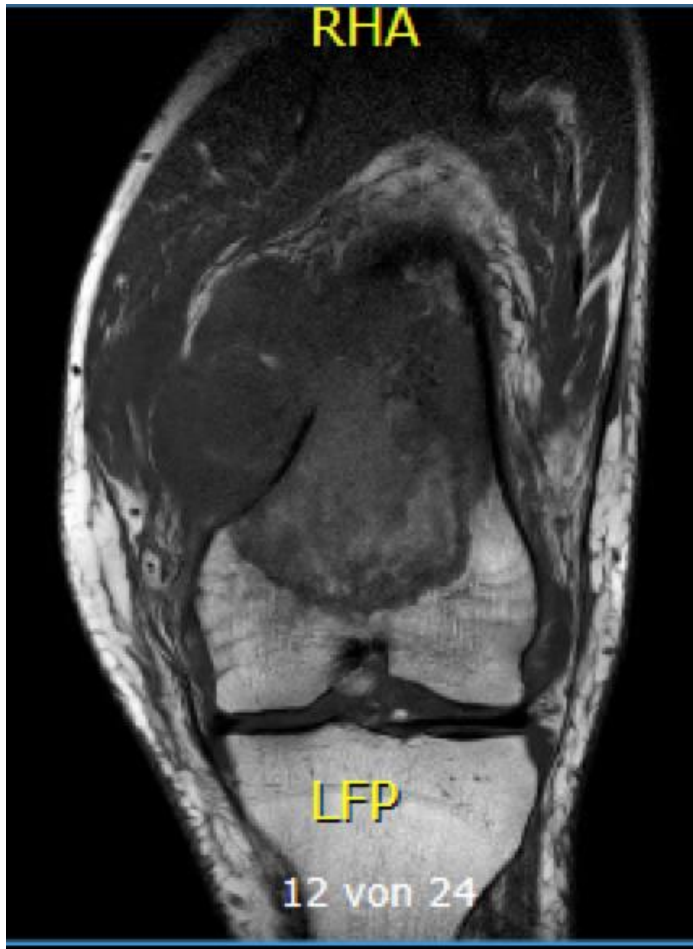Jan 30 2017



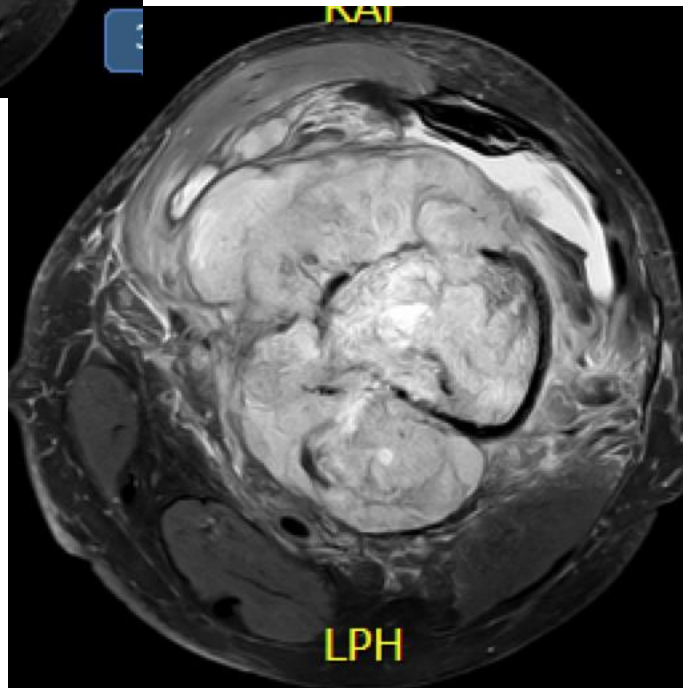
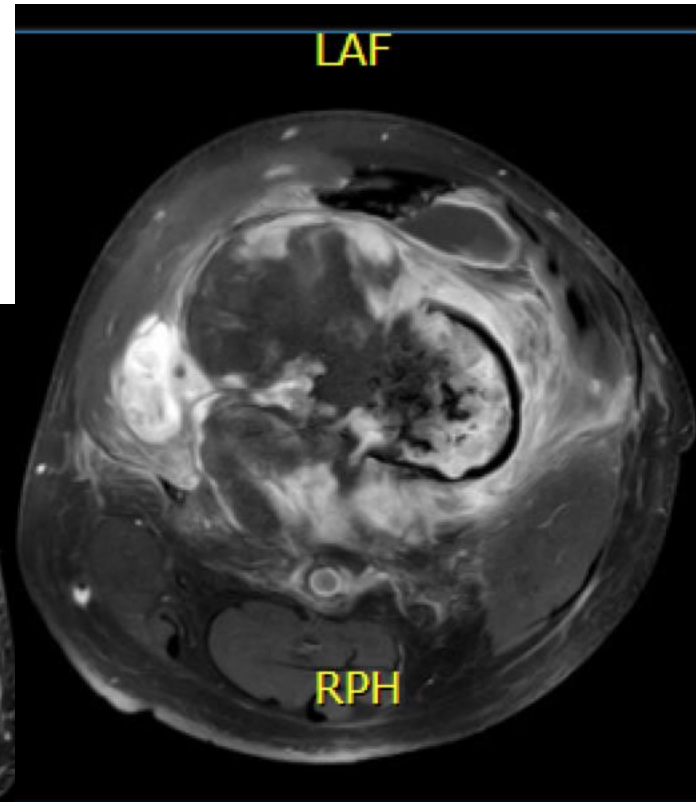
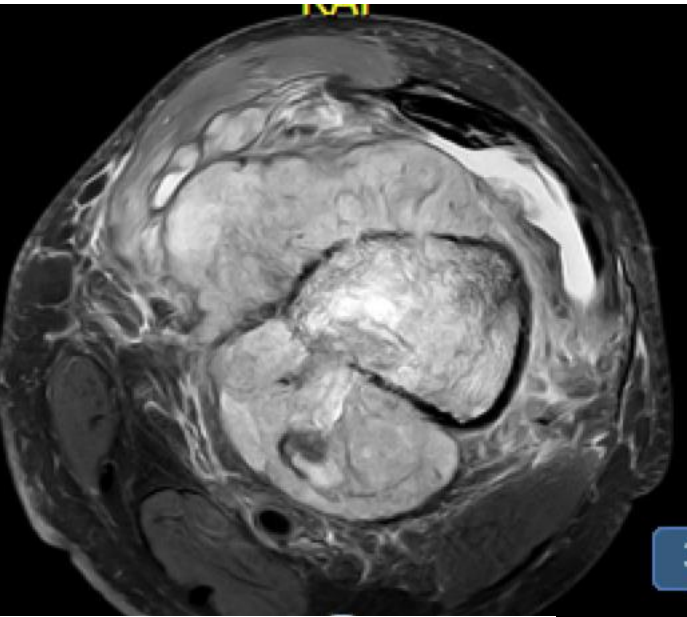
distal femur resection / 79yo / m



distal femur resection / 79yo / m

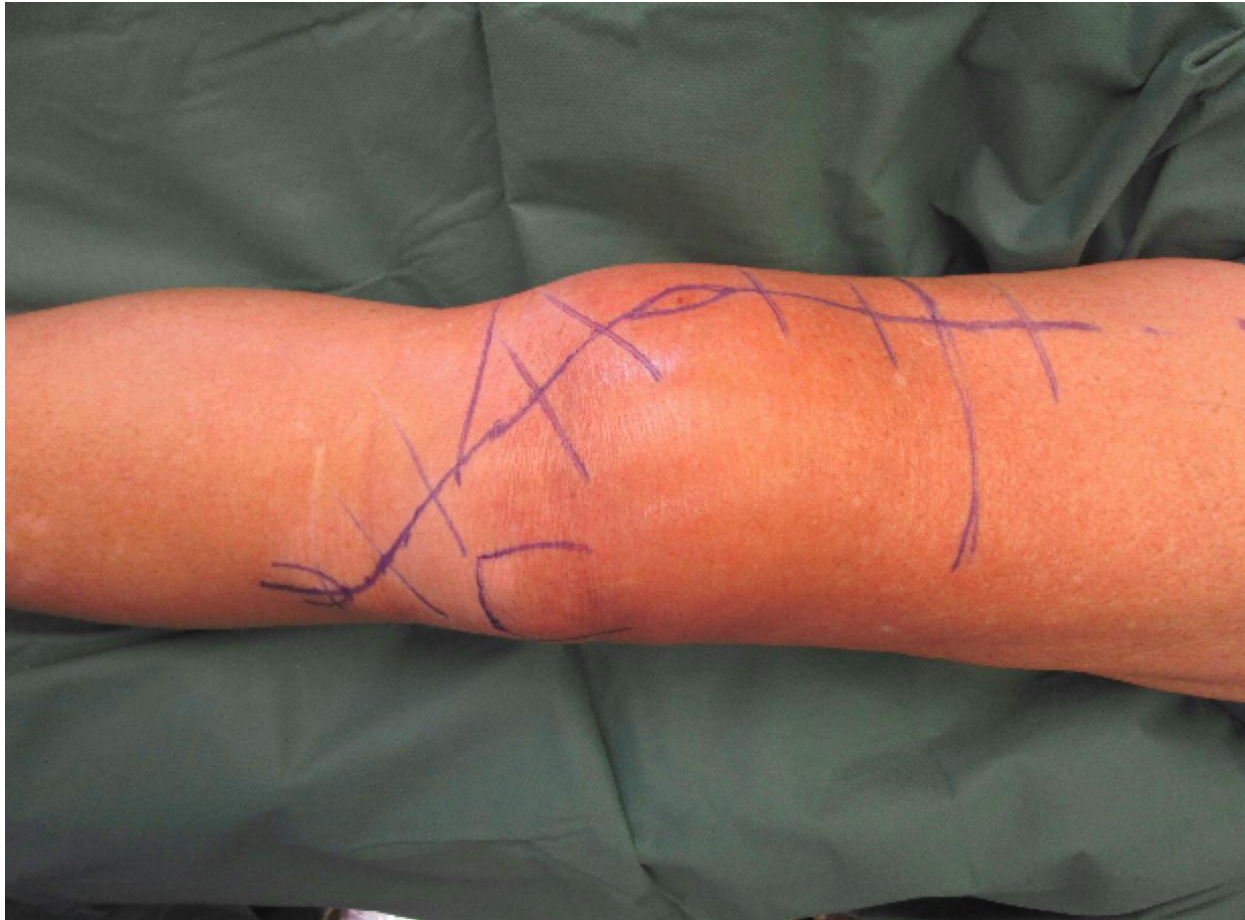


distal femur resection / 79yo / m



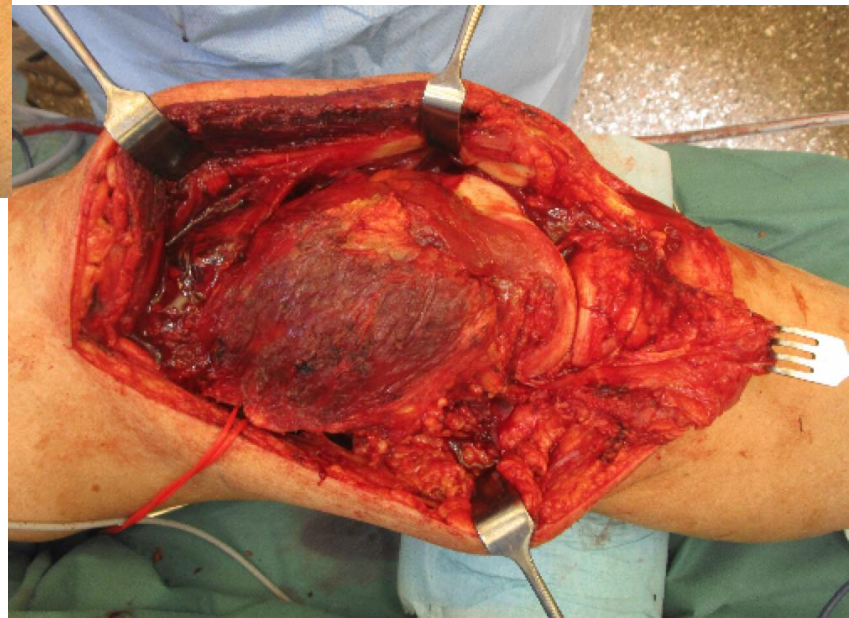
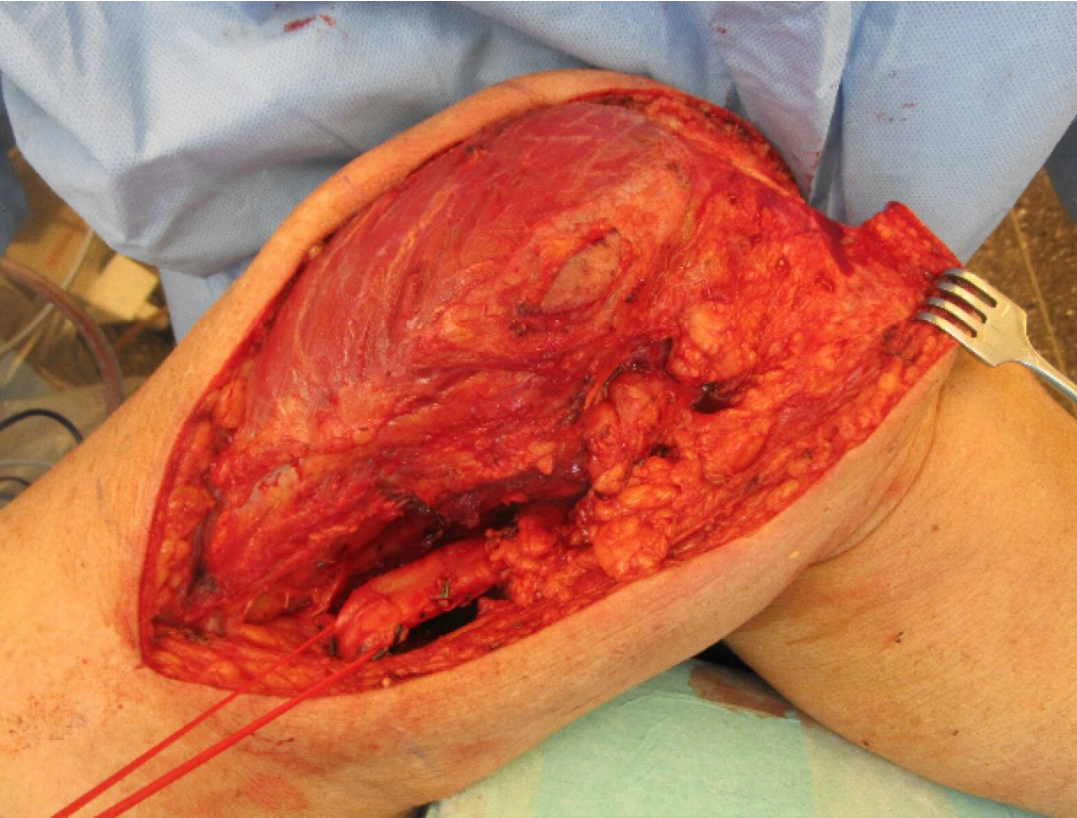
distal femur resection / 79yo / m

OP 23.1.2017



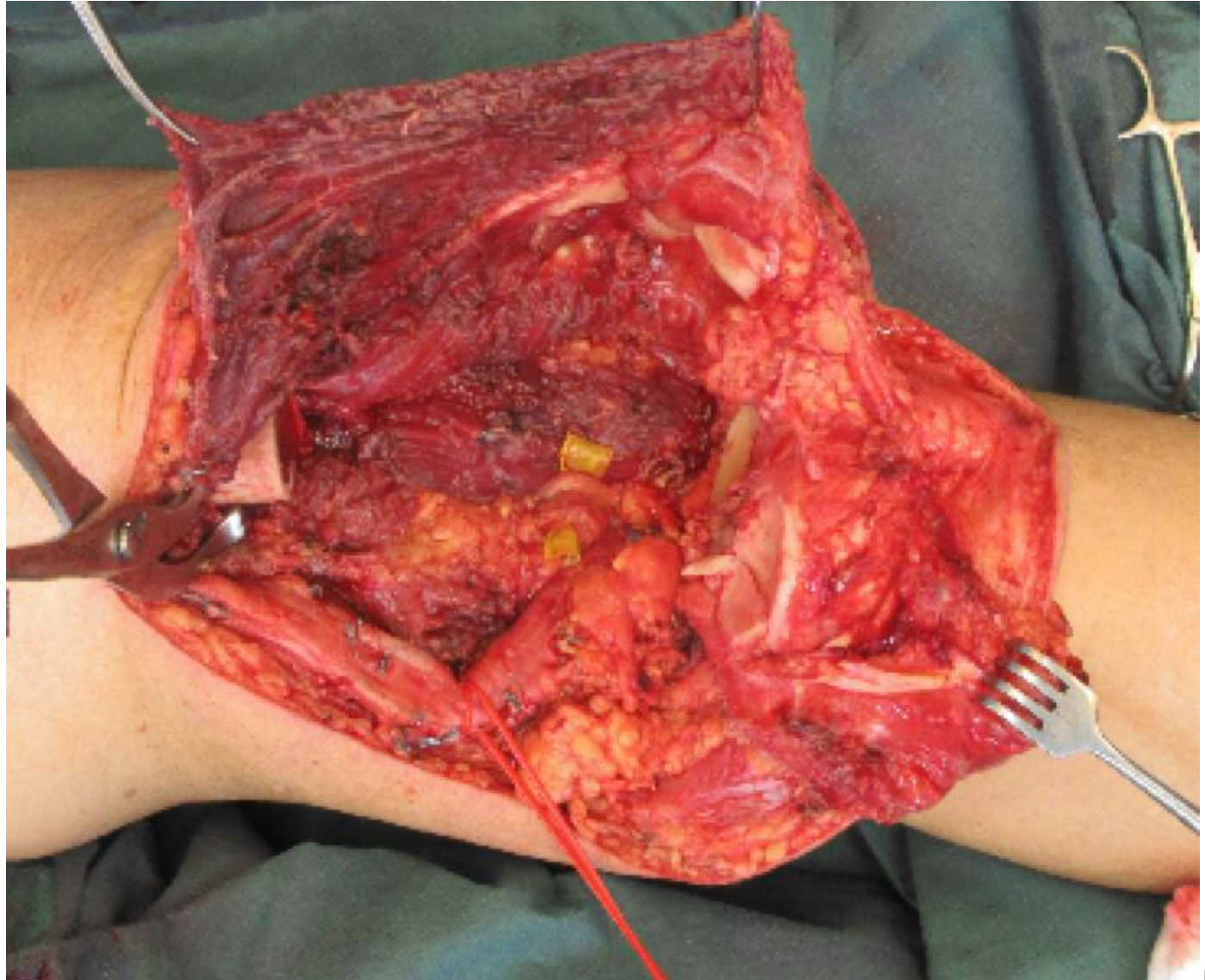
distal femur resection / 79yo / m

OP 23.1.2017



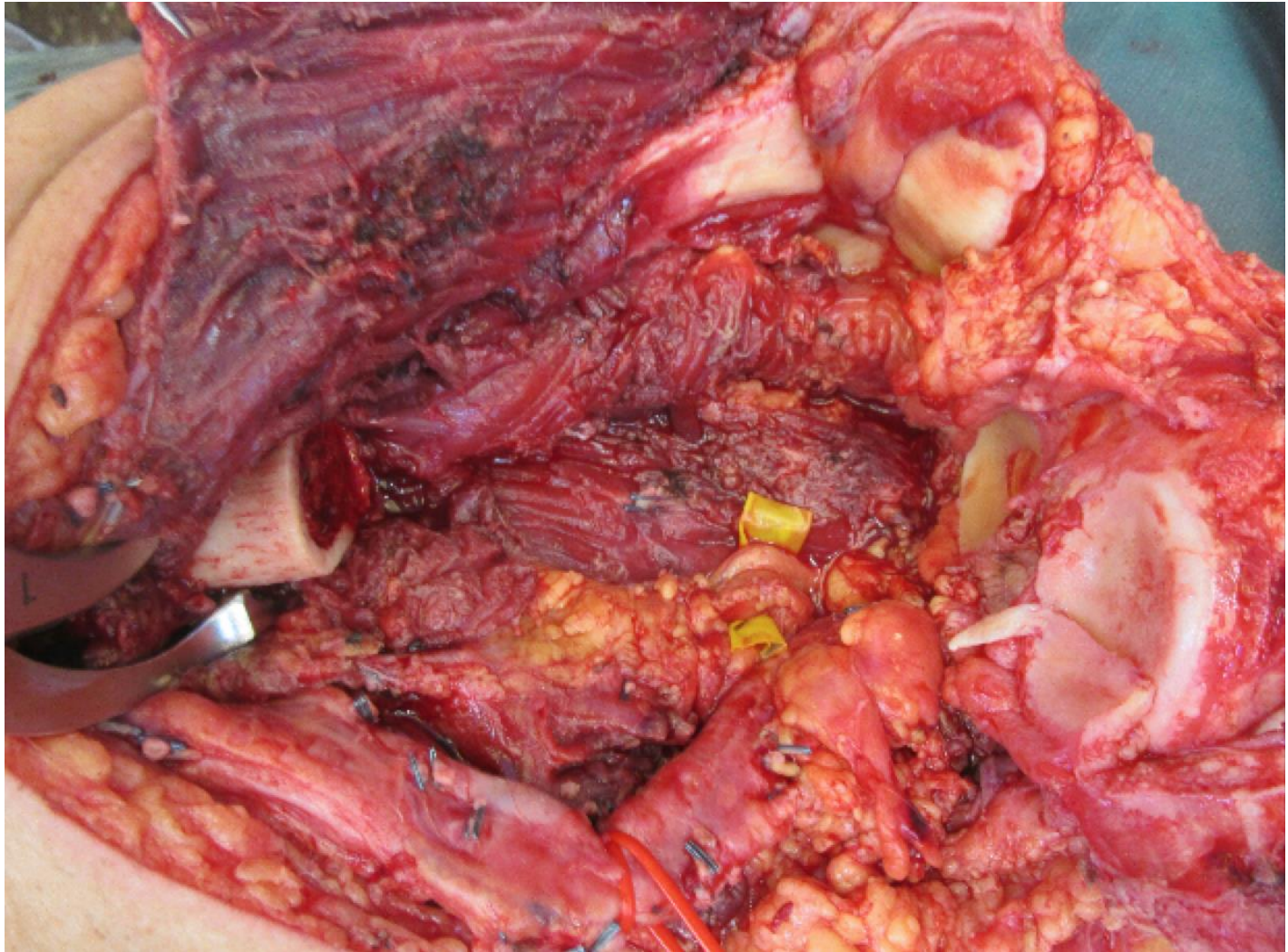
distal femur resection / 79yo / m

OP 23.1.2017

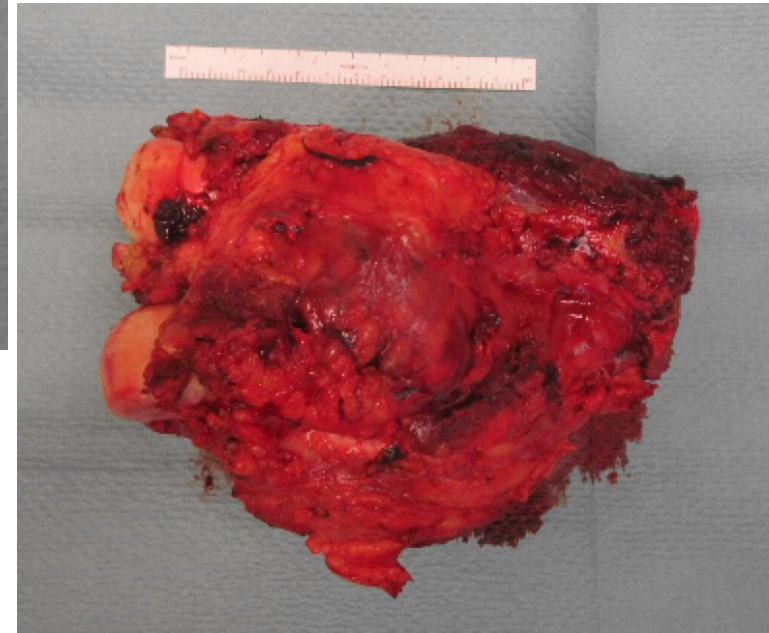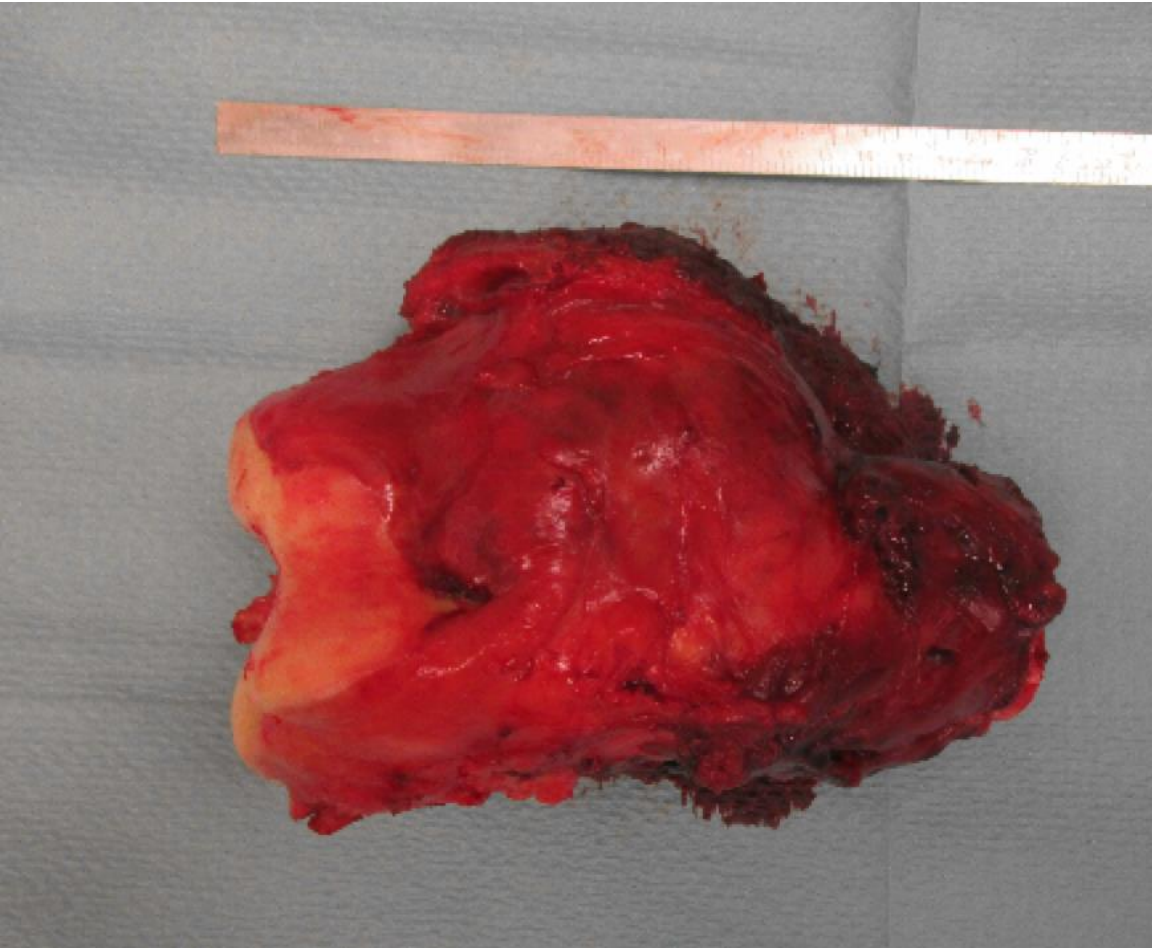


distal femur resection / 79yo / m

OP 23.1.2017

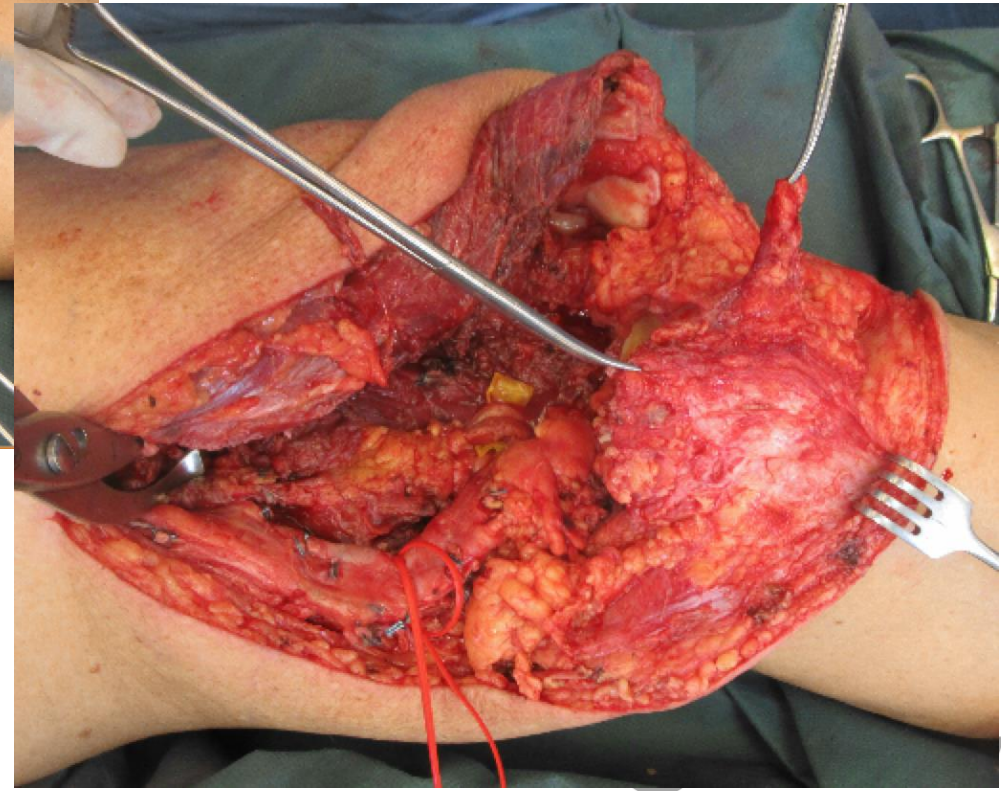
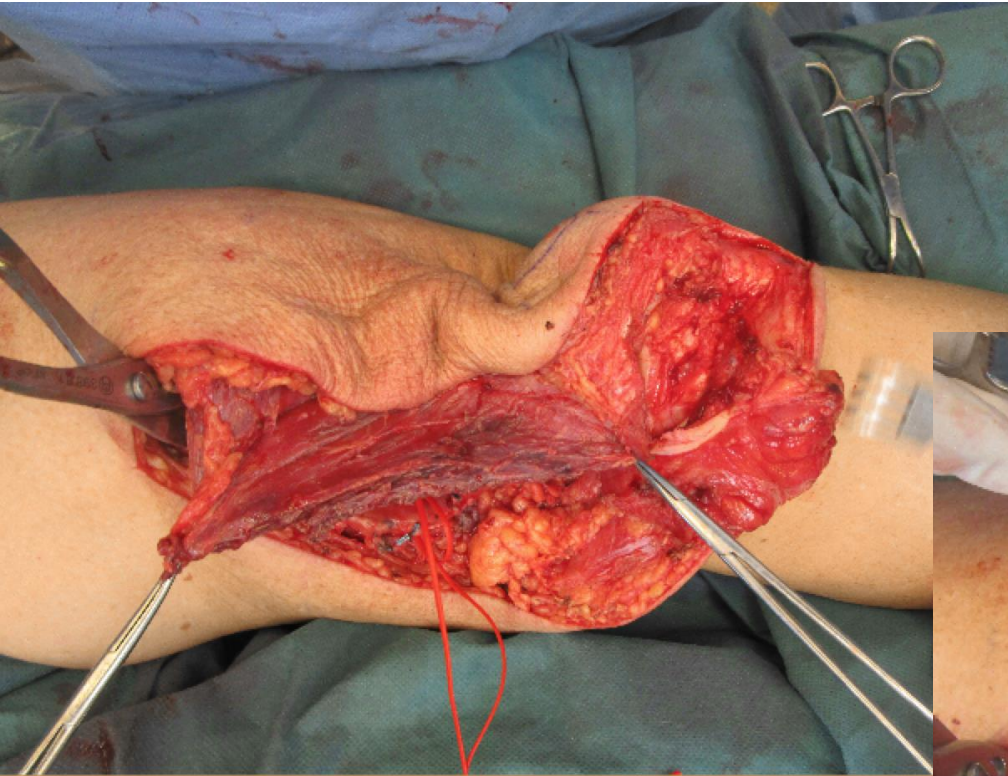


distal femur resection / 79yo / m



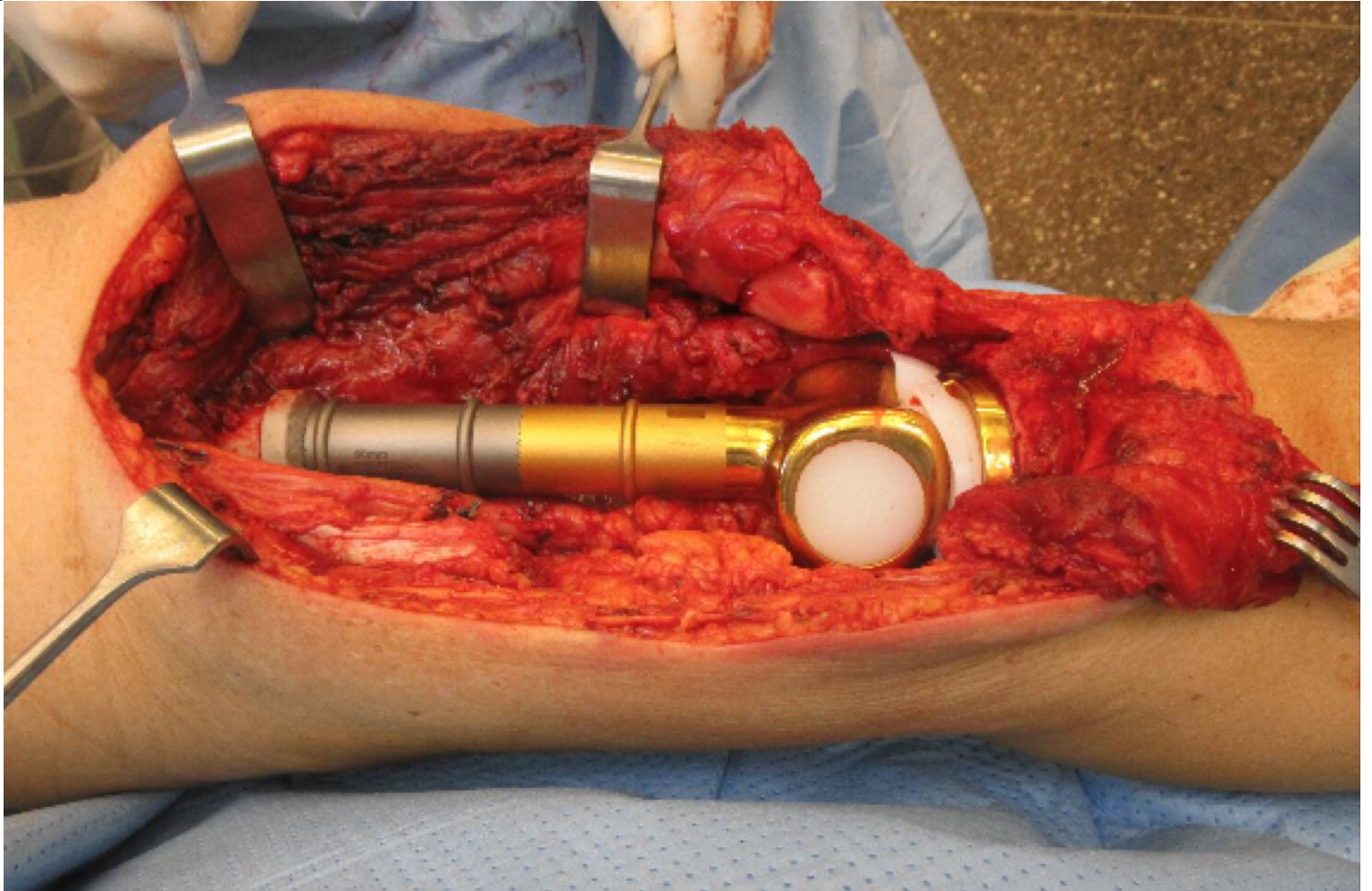
distal femur resection / 79yo / m

OP 23.1.2017



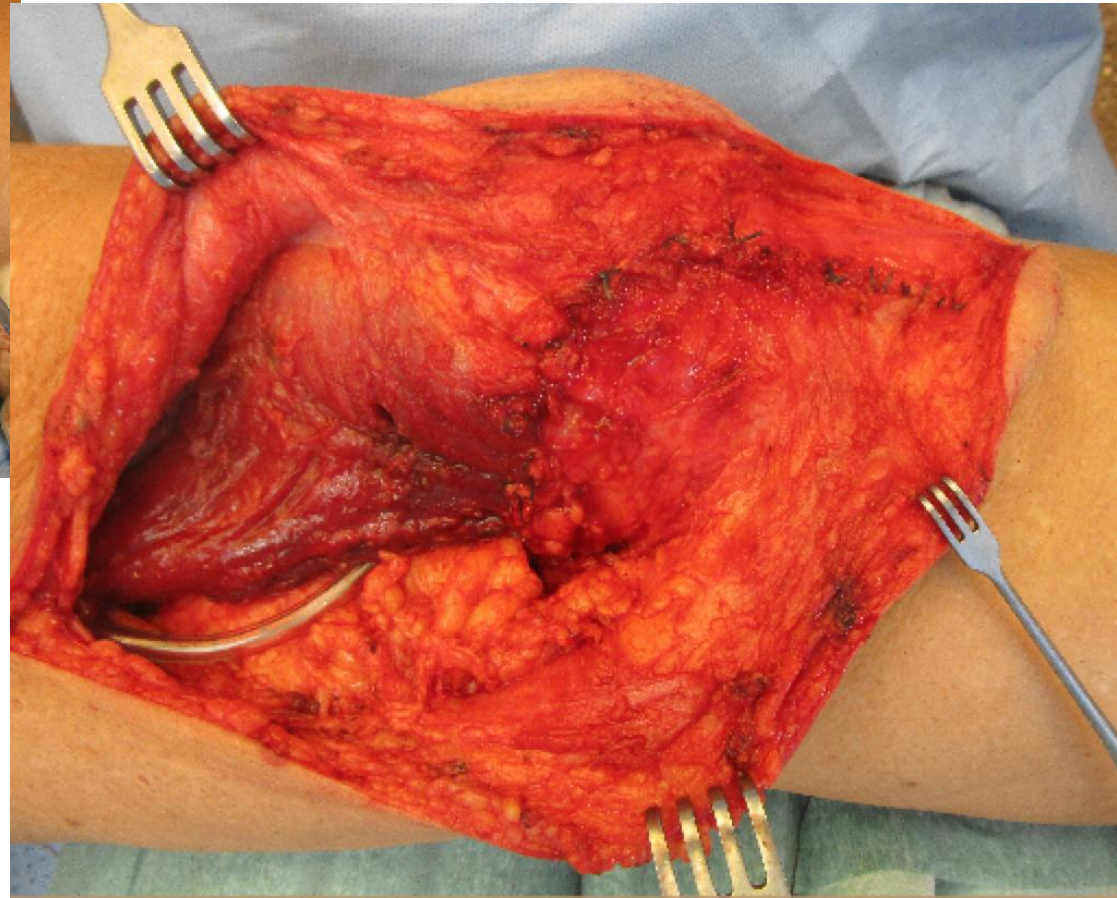
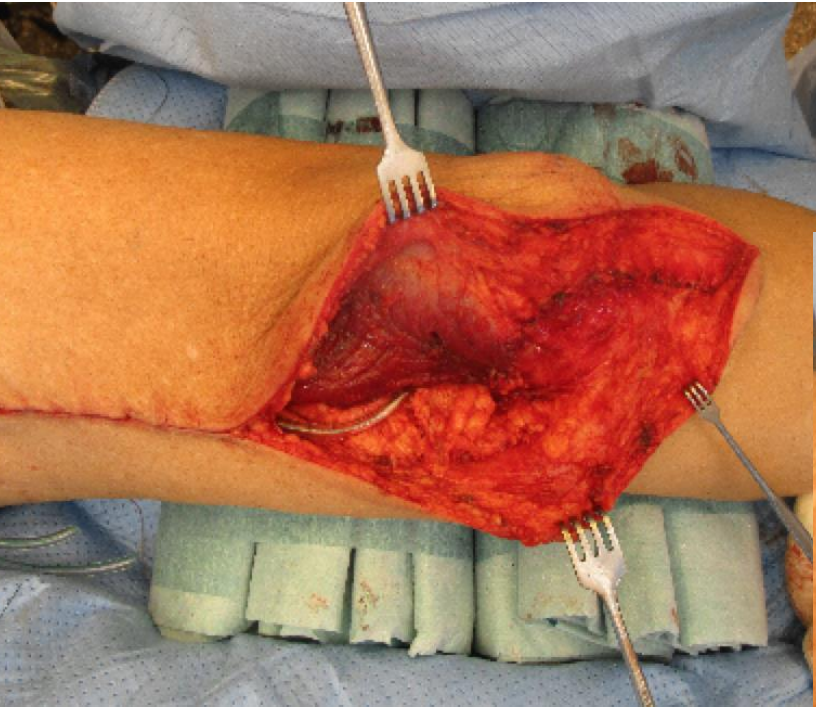
distal femur resection / 79yo / m

OP 23.1.2017



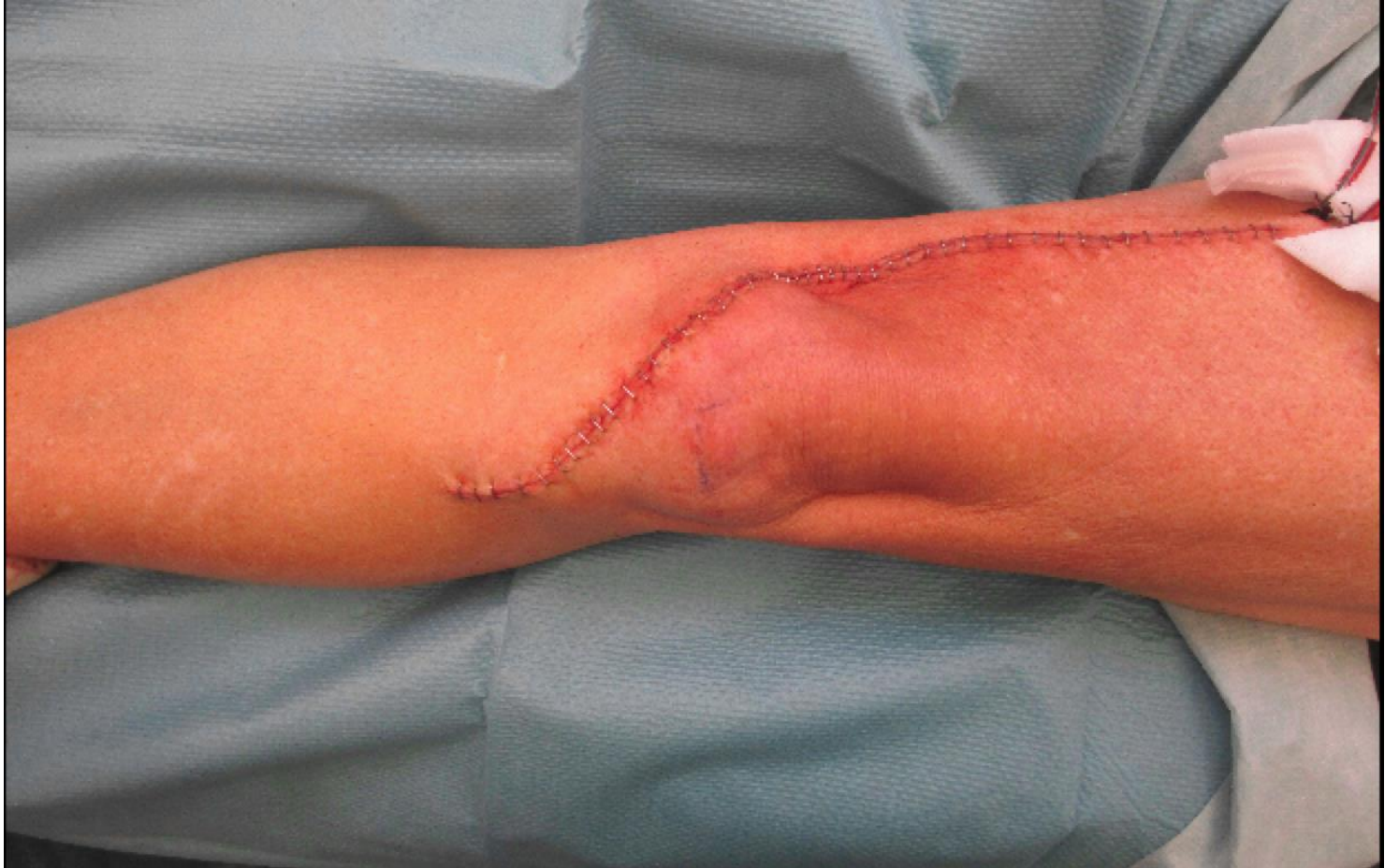distal femur resection / 79yo / m

OP 23.1.2017



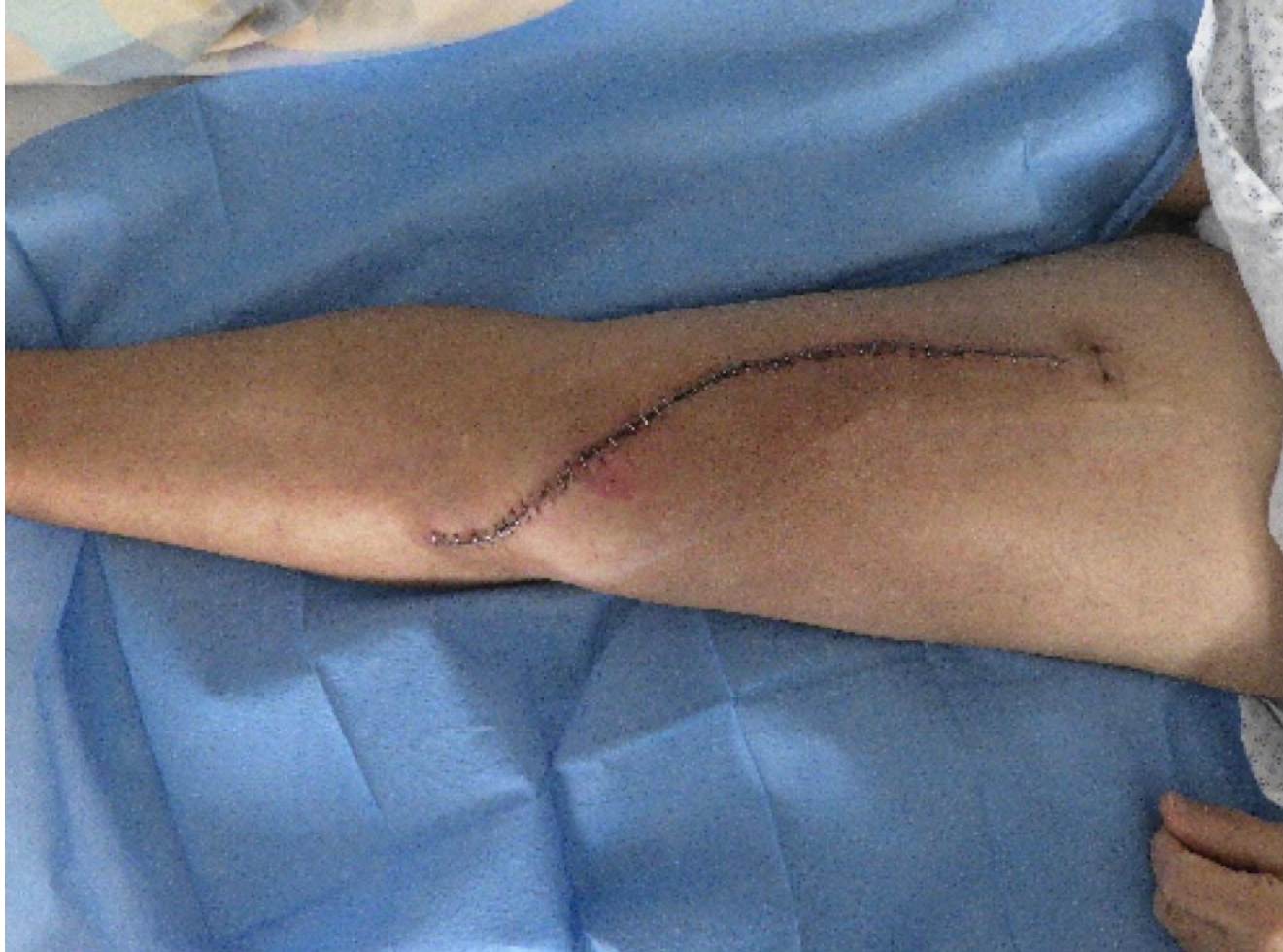distal femur resection / 79yo / m

OP 23.1.2017

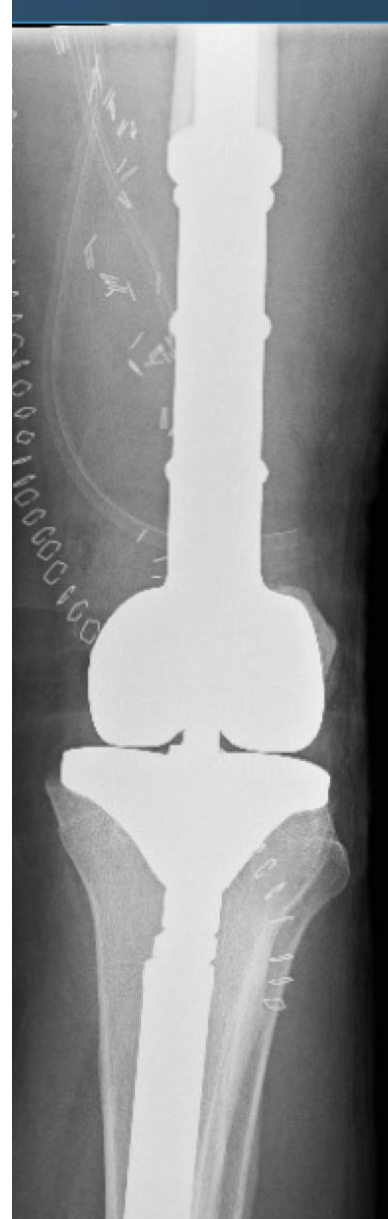
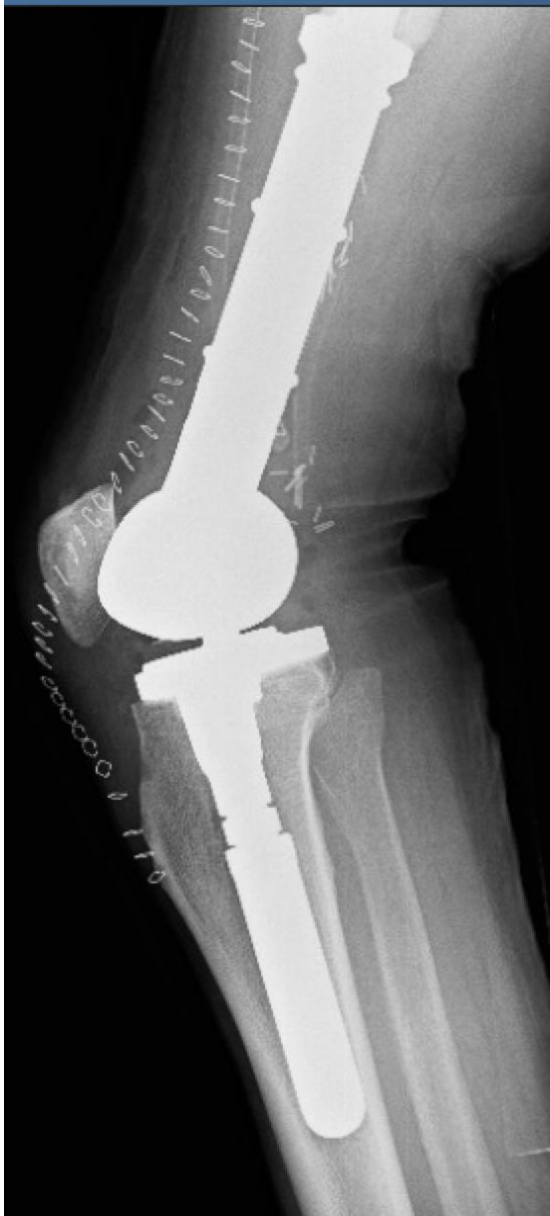

distal femur resection / 79yo / m

1 week postop; 2.2.2017



distal femur resection / 79yo / m



MUTARS®



Distales Femur MK
Operationstechnik

implantcast 