

humerus; proximal; transarticular; APC

♀ 44 yo musician

1st referral: 08.04.09

HPI: accident on ice on sept 30th 2008, persistent pain at L shoulder joint.

No night pain, PT w/o benefit

MRI (Luzern) showed lesion >> referral for further diagnosis and treatment

PMH: history of sectio

humerus; proximal; transarticular; APC

apr 8th, 2009

Clinical examination:

atrophy of deltoid muscle,

ROM L shoulder: active flexion 150° , abduction 140° , IR to gluteal region with pain

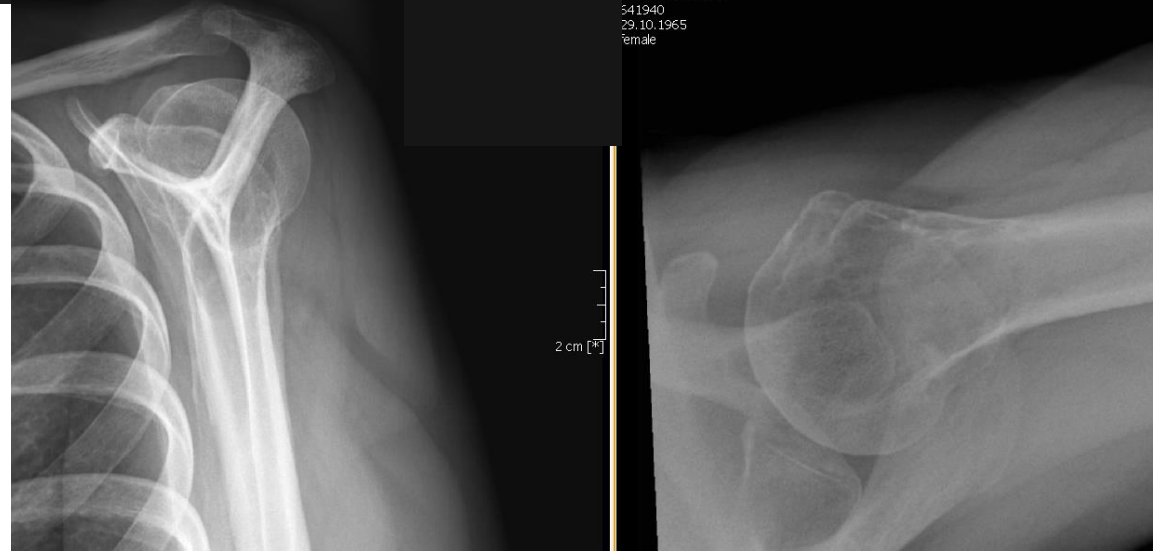
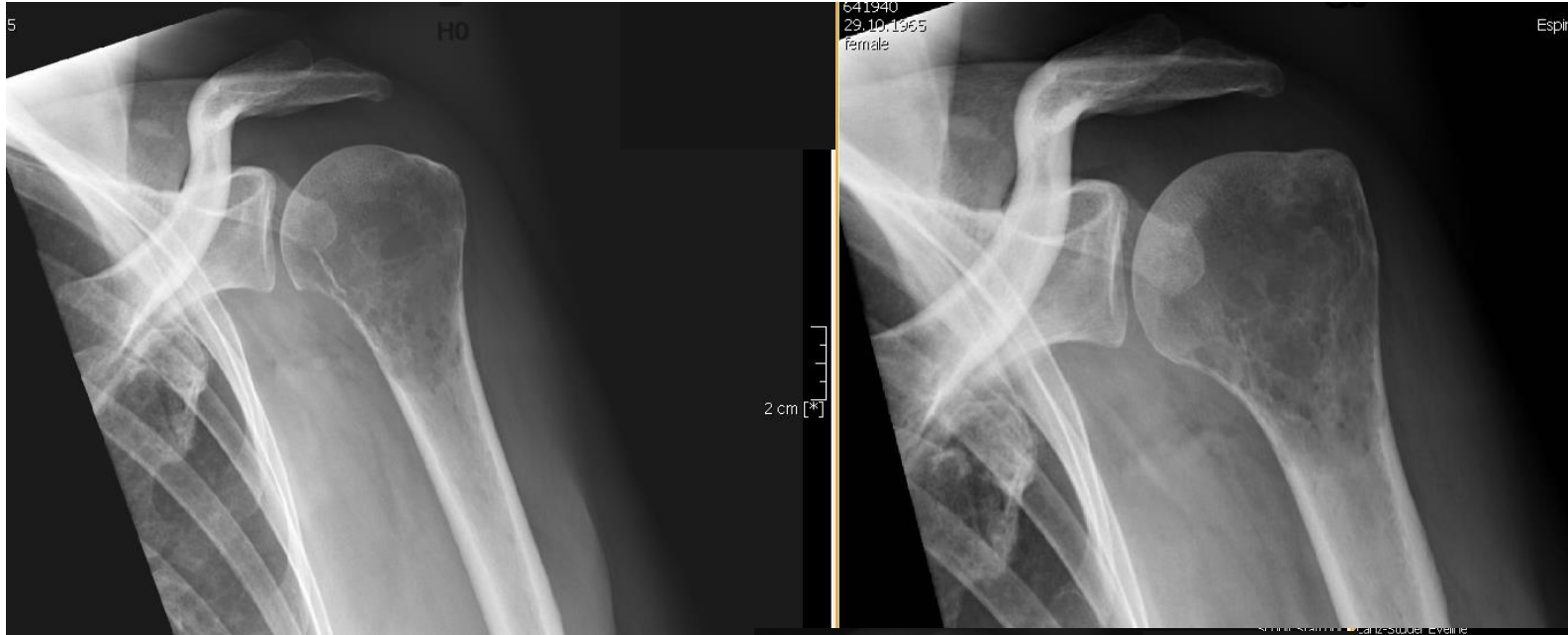
ac-joint not painful, positive subacromial impingement-signs

SSP-muscle could not be tested because of pain

Forced ER reduced, signs for biceps tendinitis positive

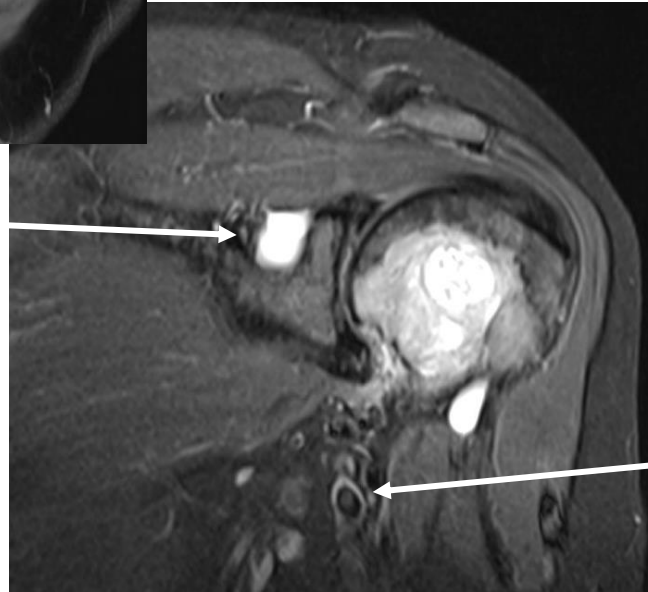
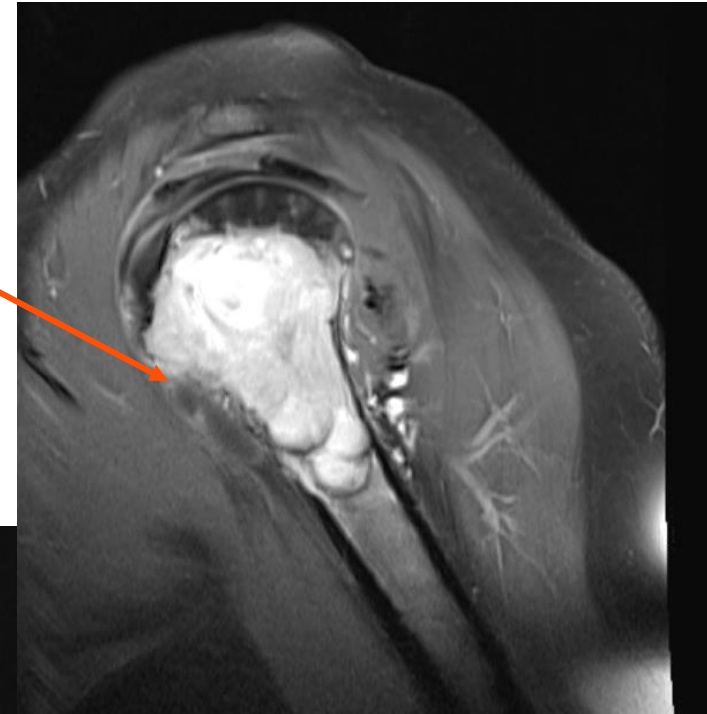
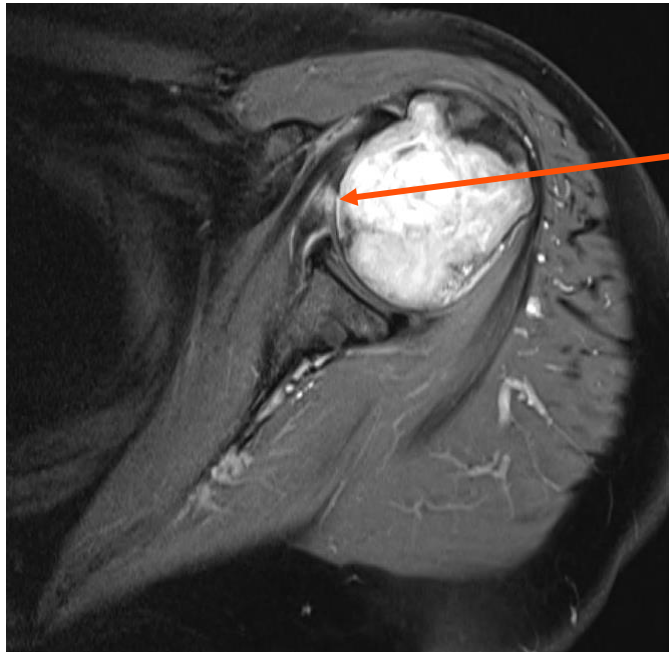
humerus; proximal; transarticular; APC

Xray: April 8th, 2009

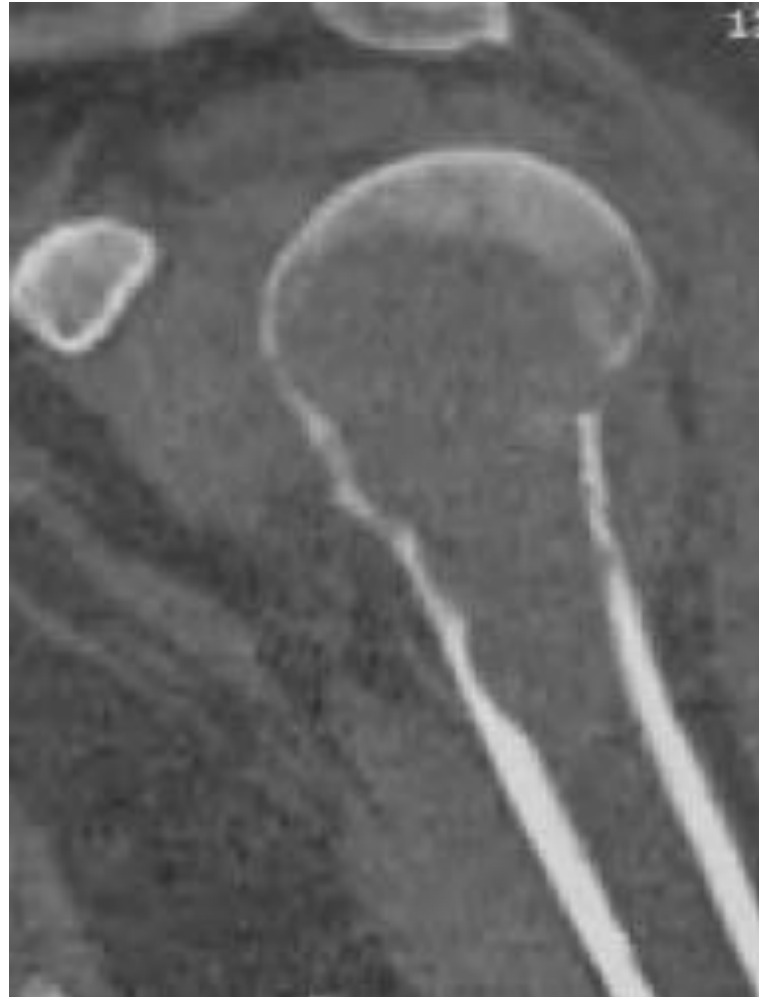
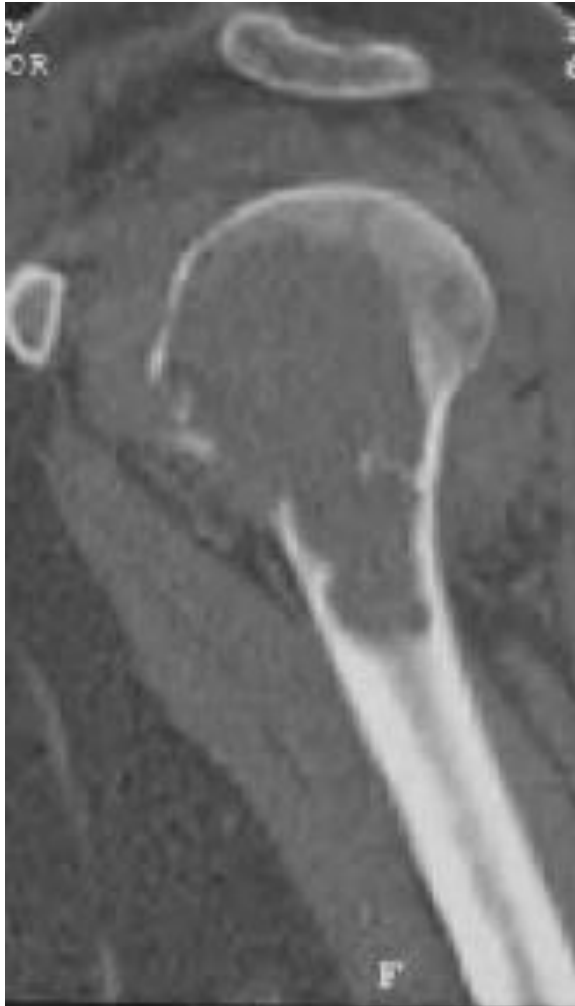
humerus; proximal; transarticular; APC

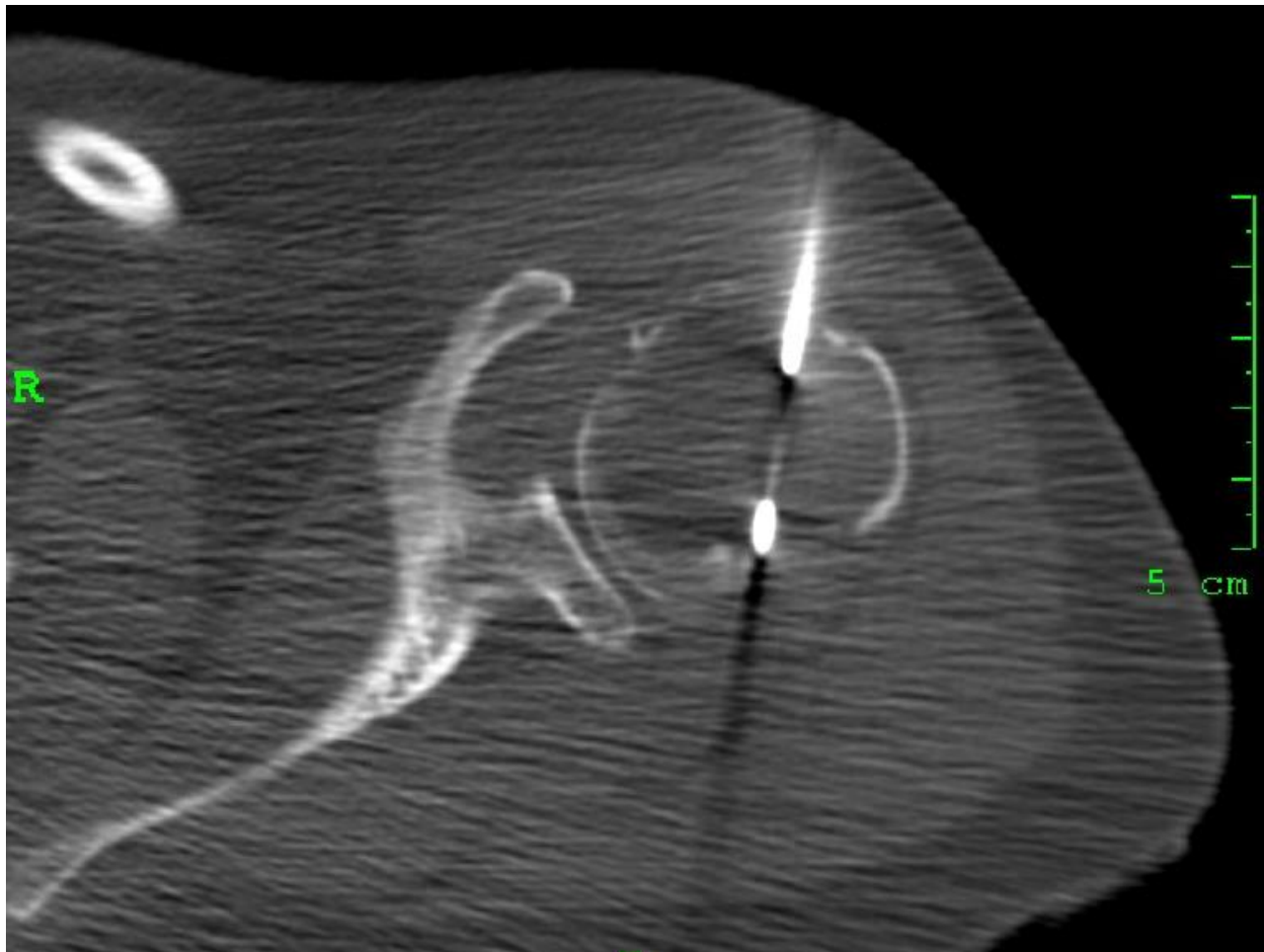
MRI: April 17th, 2009



humerus; proximal; transarticular; APC MRI: April 8th, 2009



humerus; proximal; transarticular; APC CT-Biopsy: April 17th, 2009



Anterior approach,
beneath the biceps
tendon,

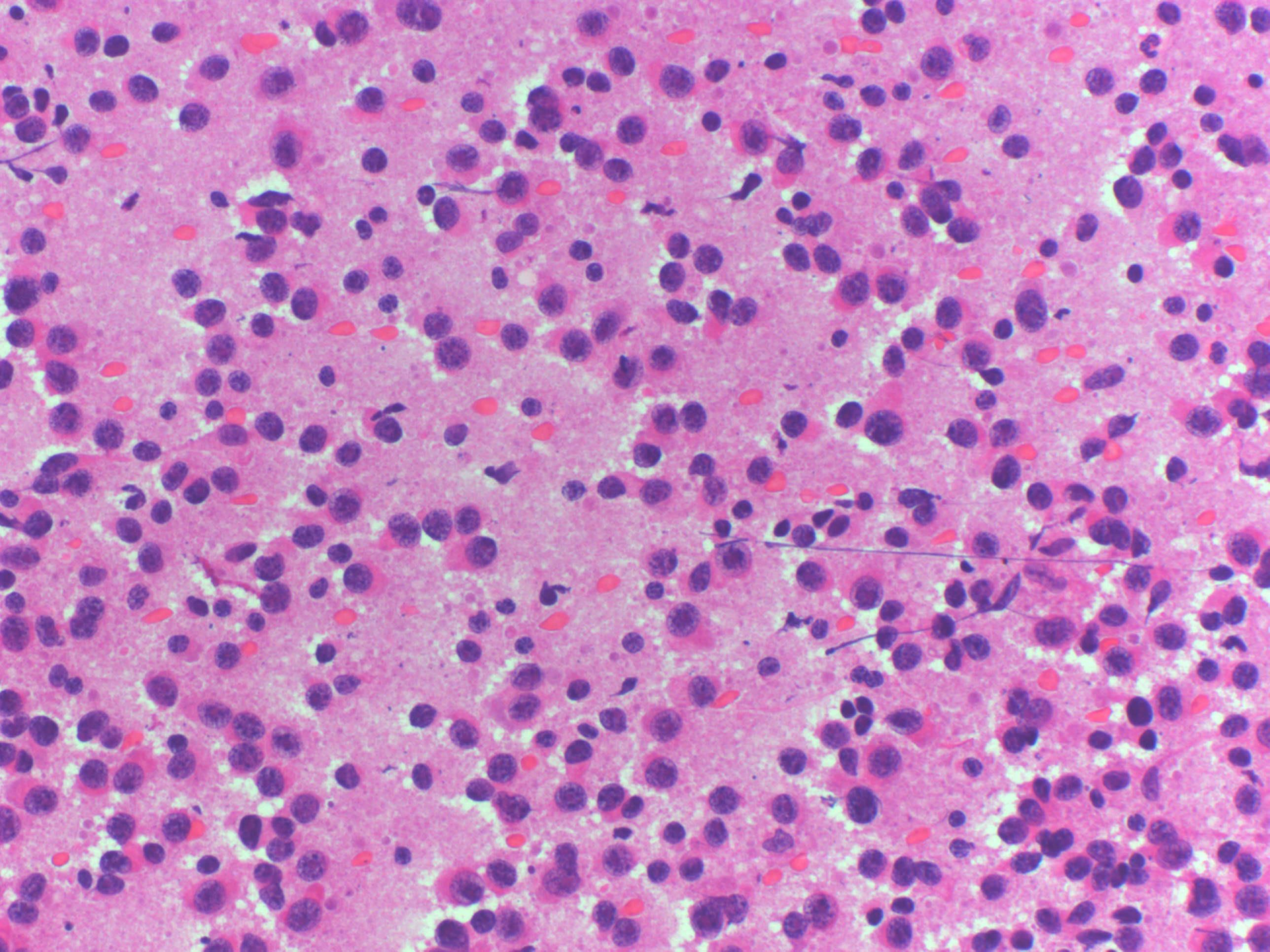
Contained blood
clots and soft
material

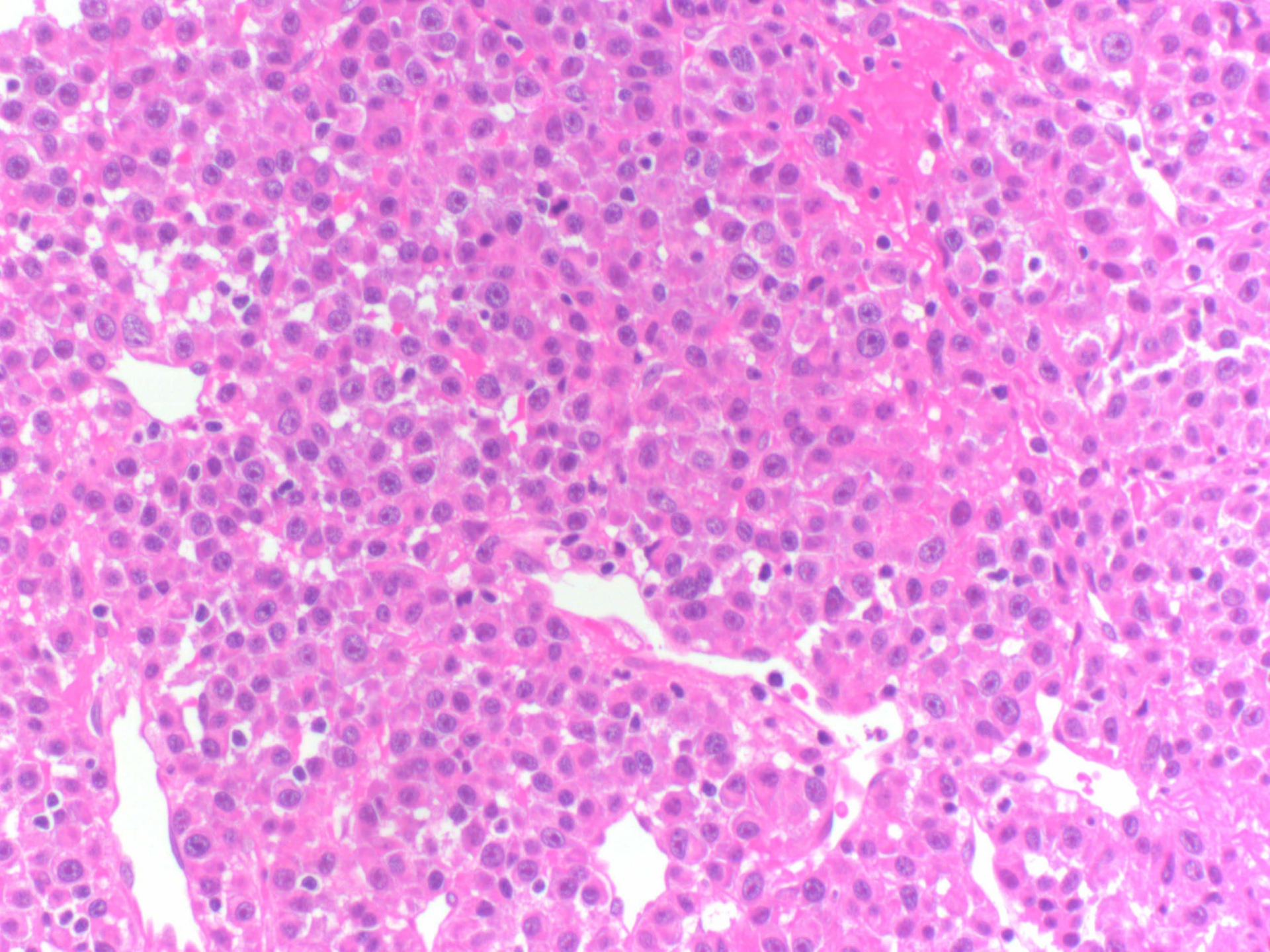
humerus; proximal; transarticular; APC CT-Biopsy: April 17th, 2009

Pathology (B2009)

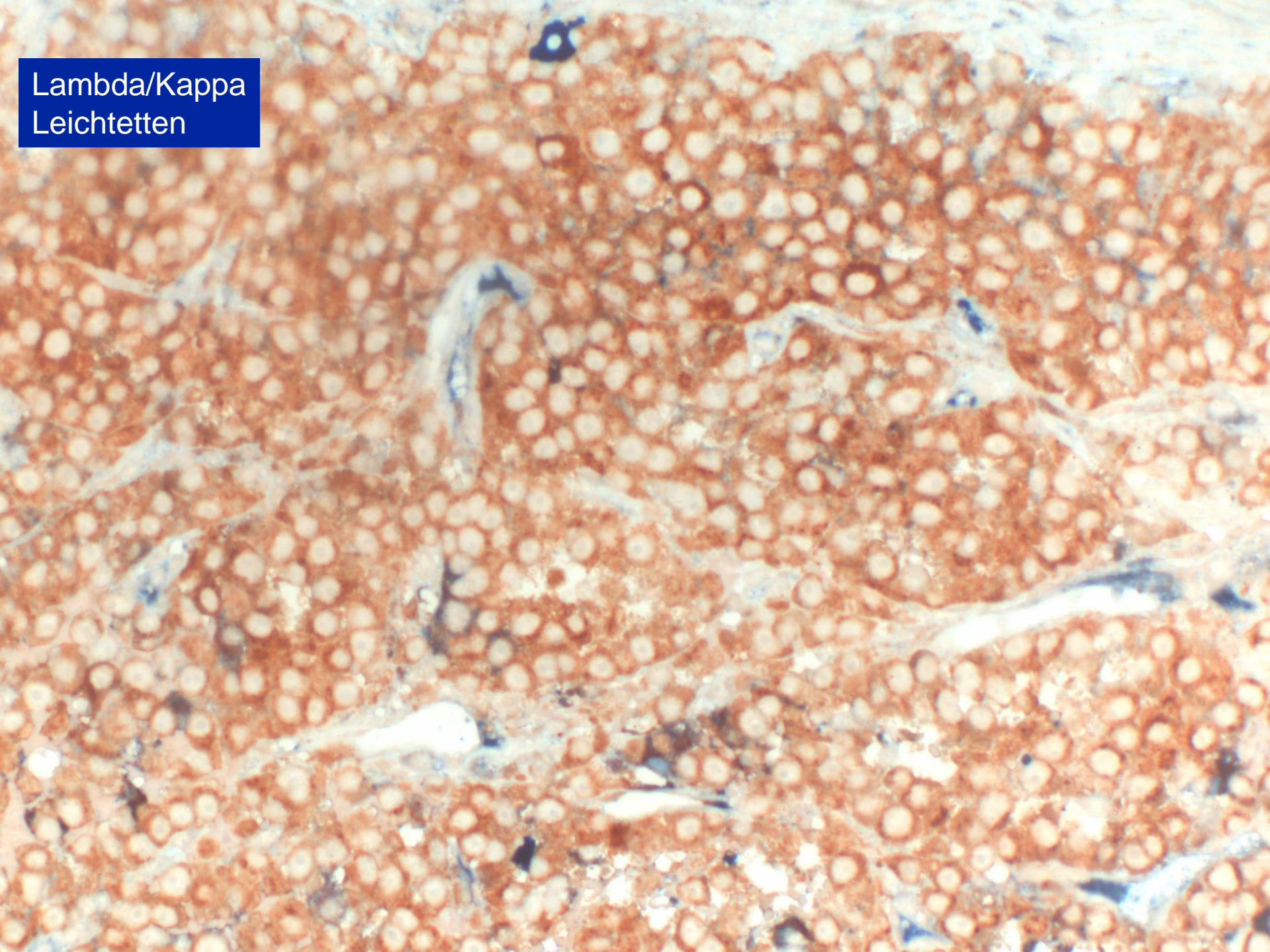
Diagnose

B 2009.16789+90: Mässig differenziertes Plasmazellmyelom mit Leichtketten-Restriktion für Kappa (Humeruskopf links).

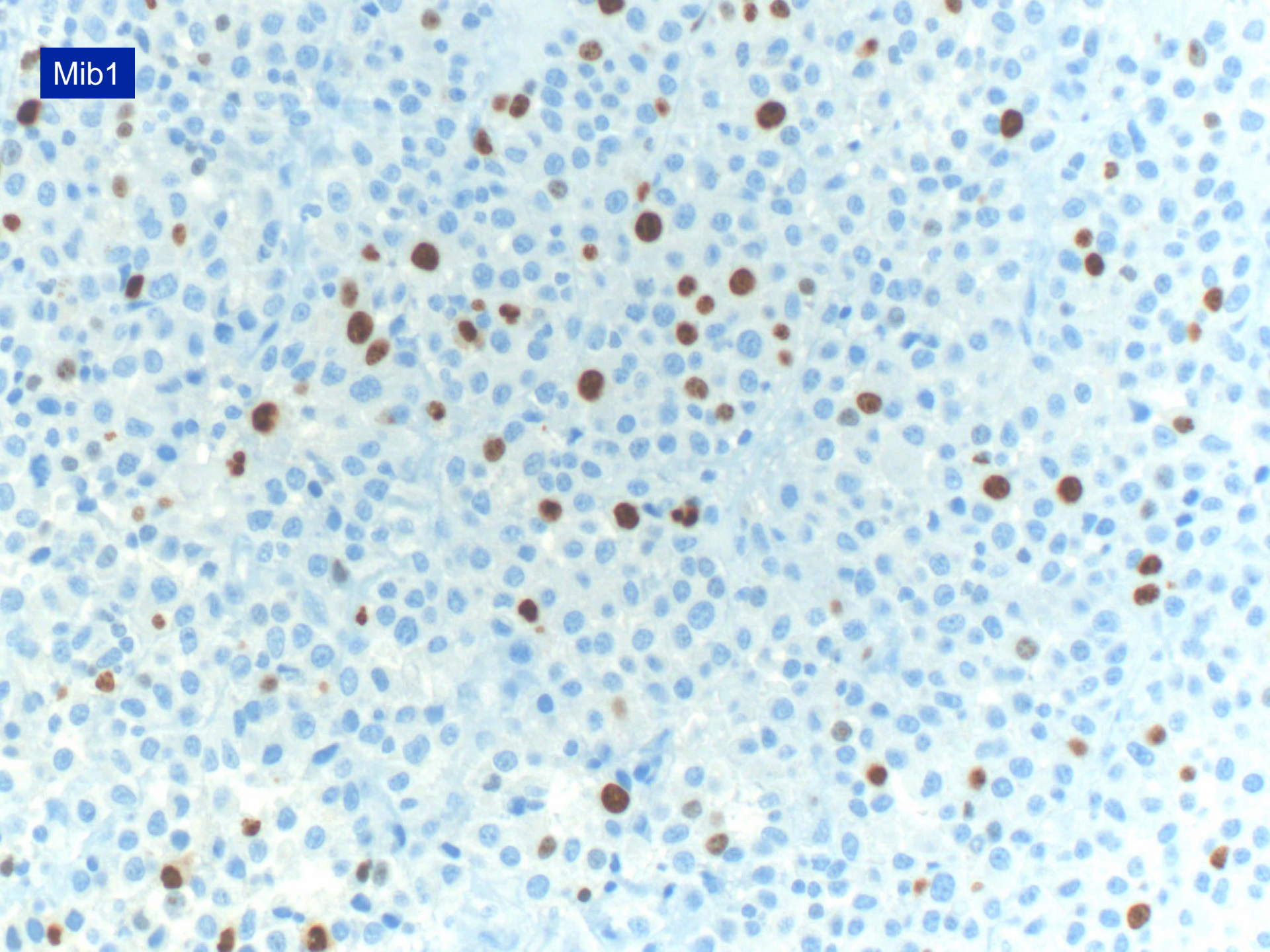




Lambda/Kappa
Leichtetten

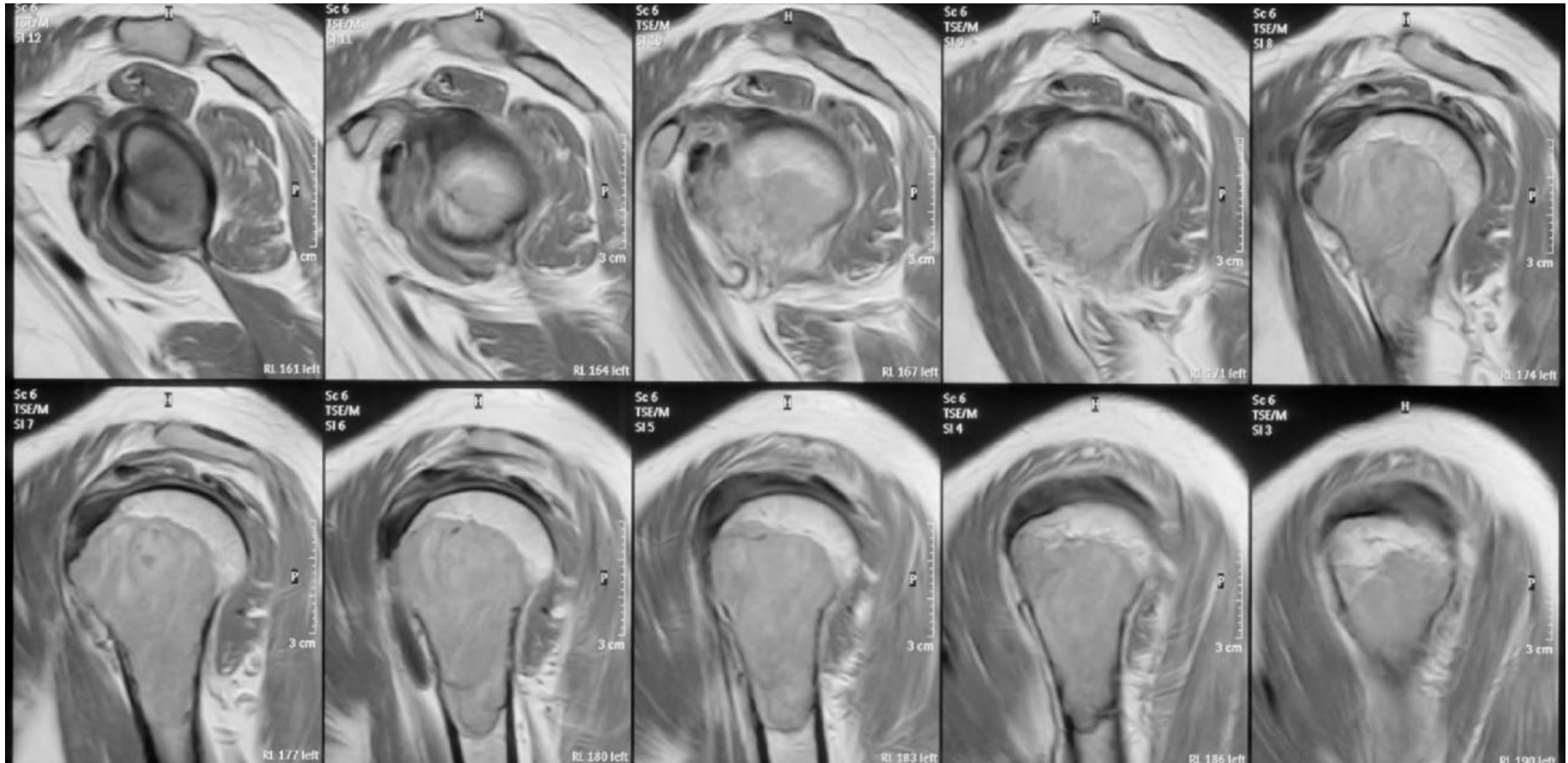


Mib1



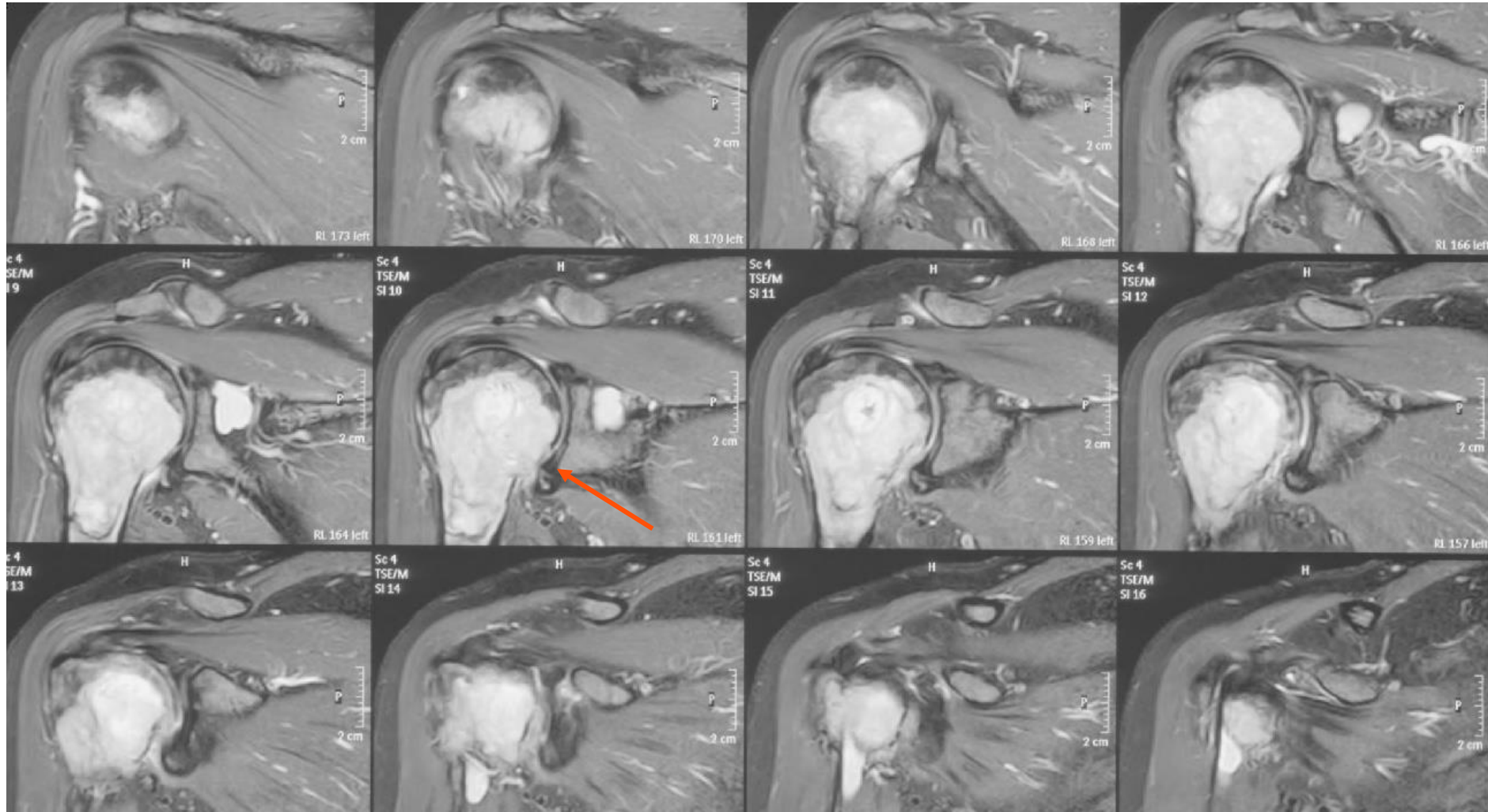
humerus; proximal; transarticular; APC

MRI: April 8th, 2009



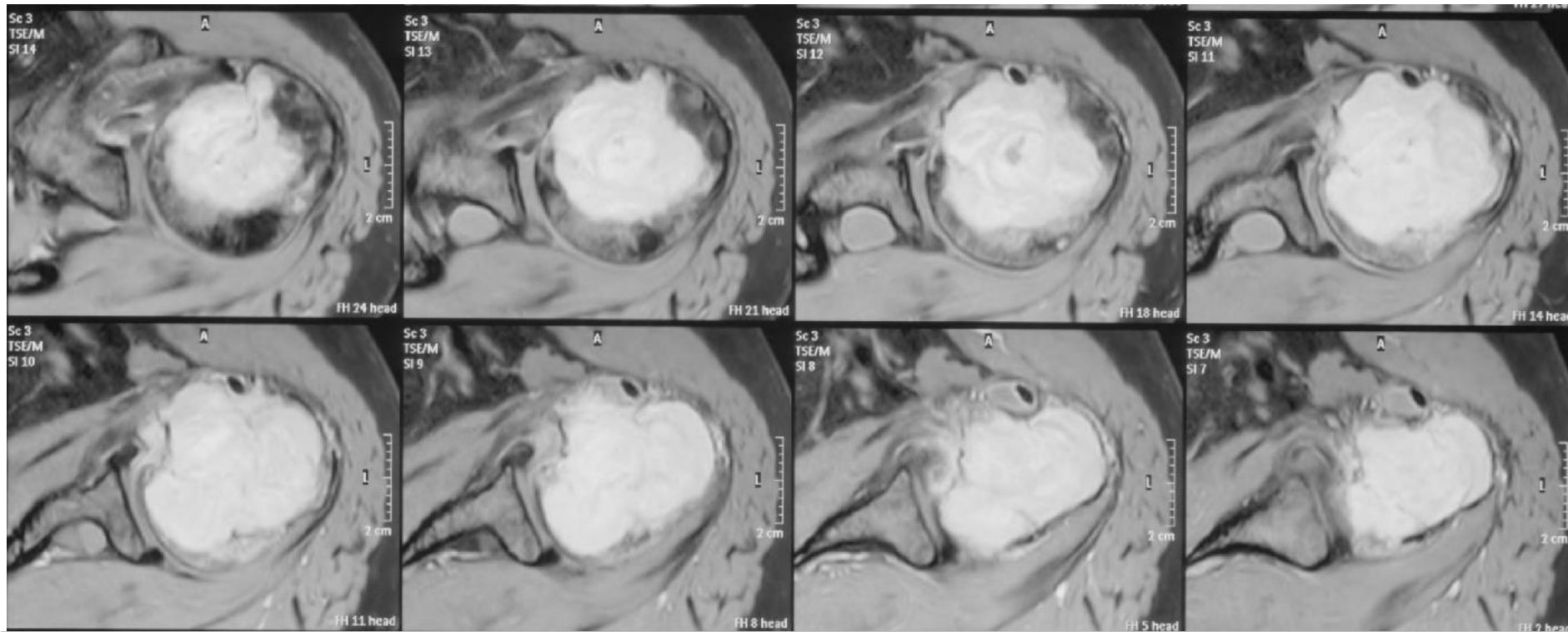
humerus; proximal; transarticular; APC

MRI: April 8th, 2009



humerus; proximal; transarticular; APC

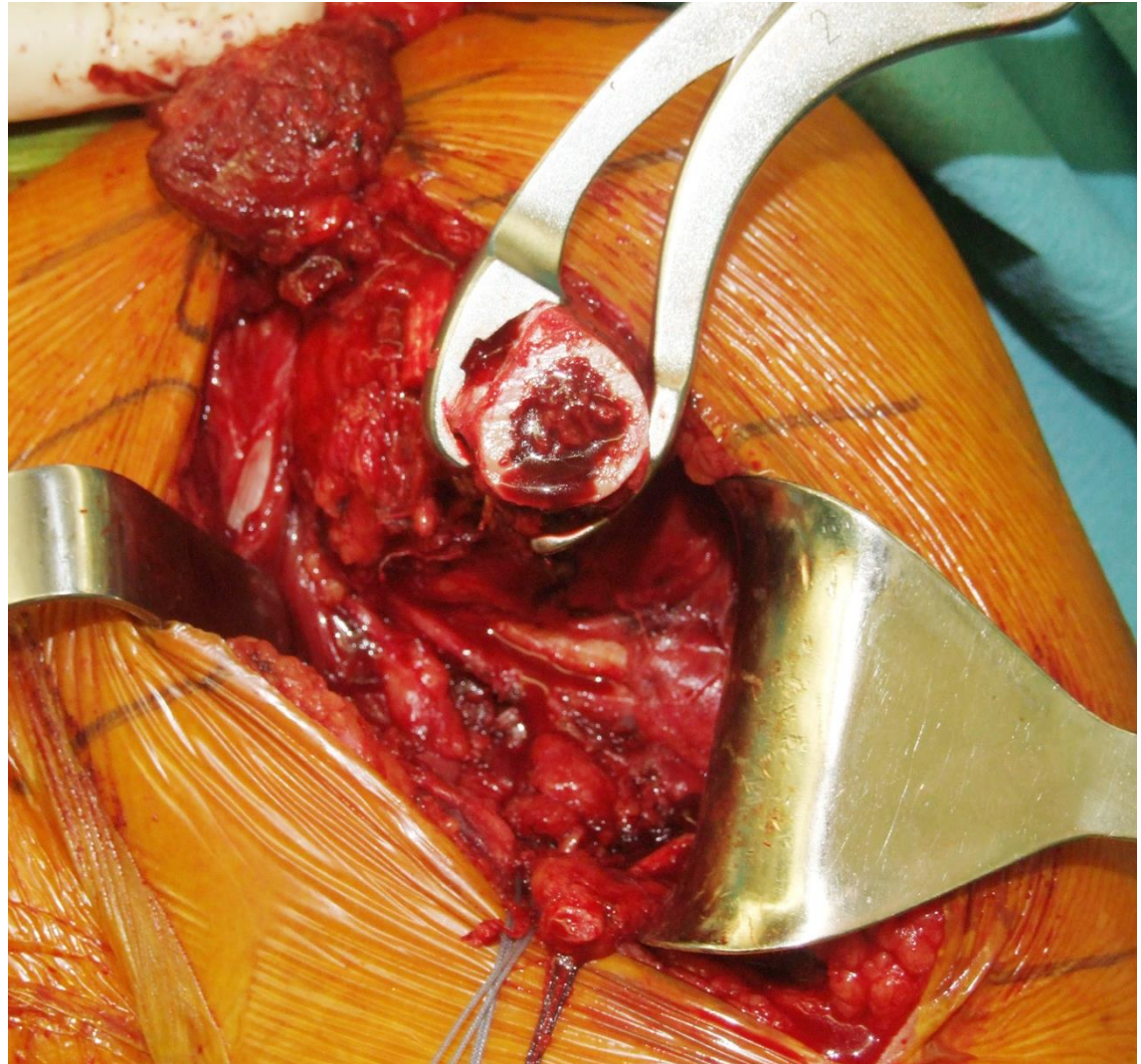
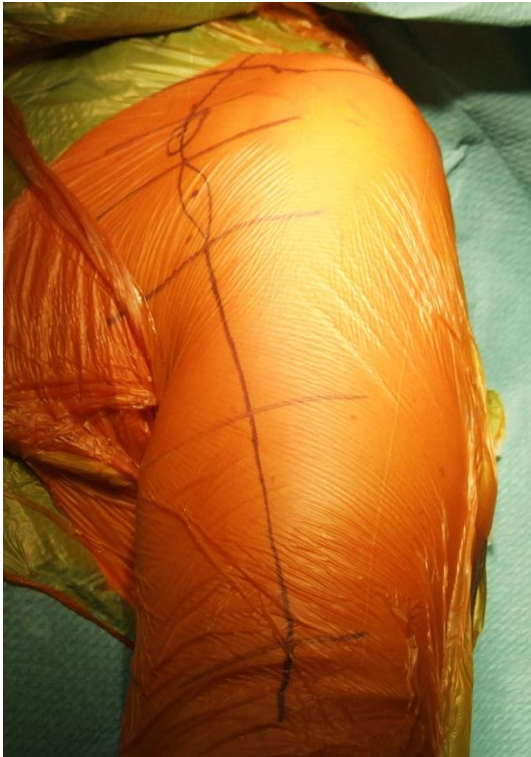MRI: April 8th, 2009



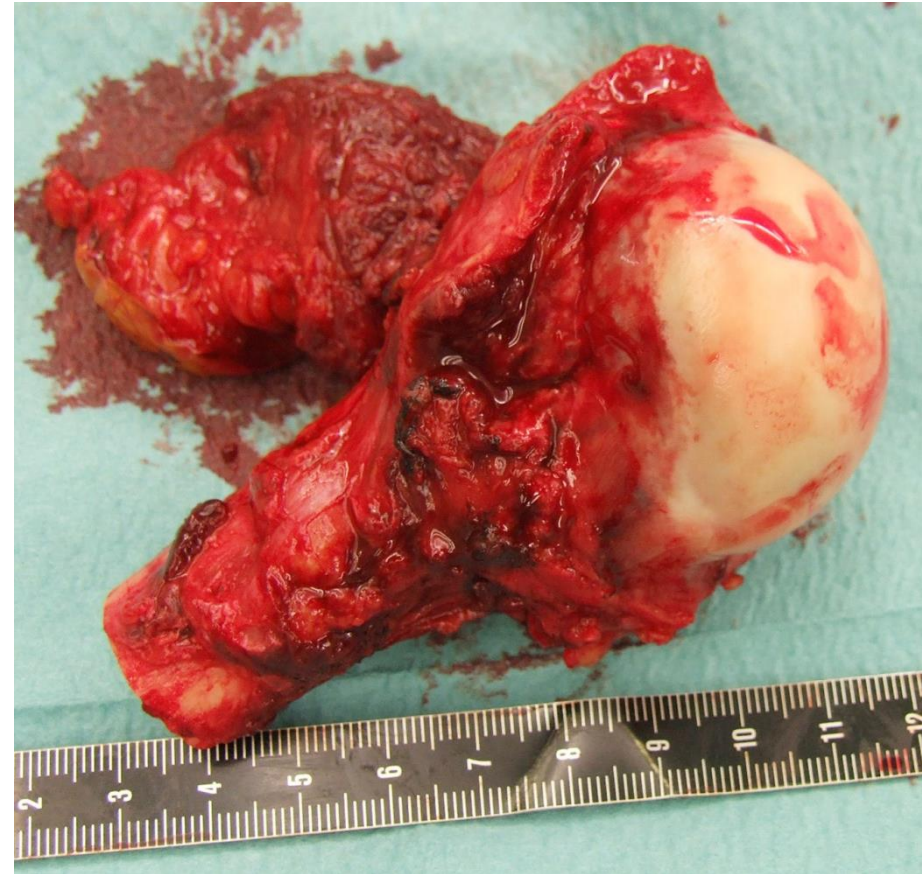
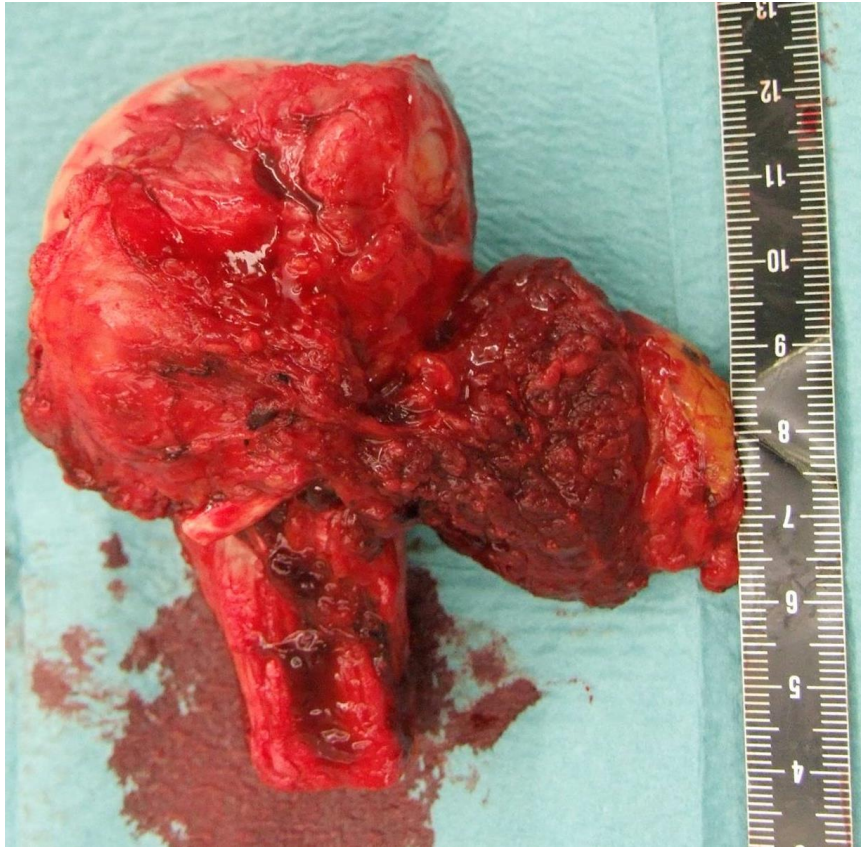
MRI and CT-Scan from april 6th, 2009 shows large lobulated mass, discontinuity of corticalis and soft tissue infiltration in axillary region

humerus; proximal; transarticular; APC

Surgery: June 30th, 2009

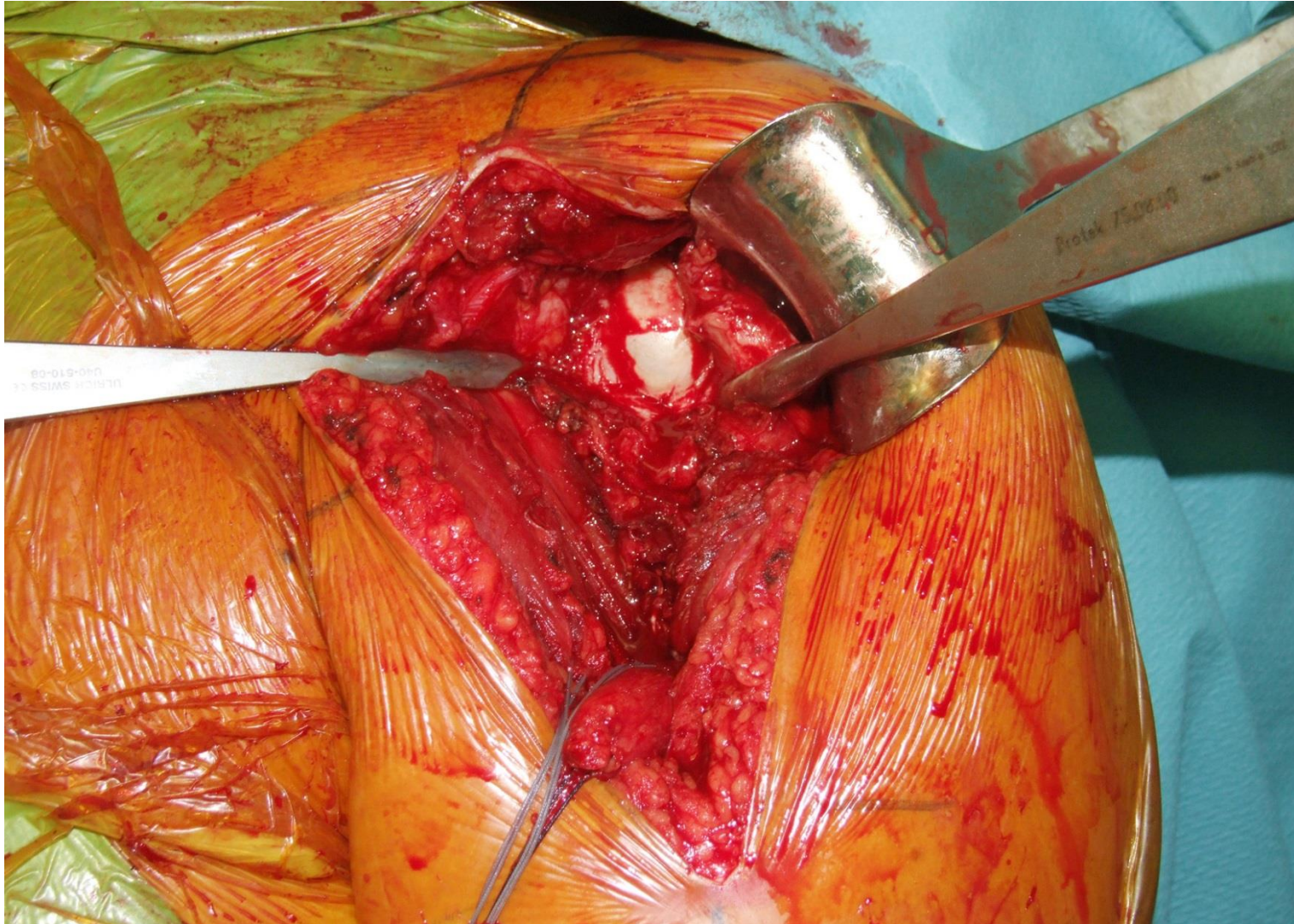

humerus; proximal; transarticular; APC Surgery: June 30th, 2009

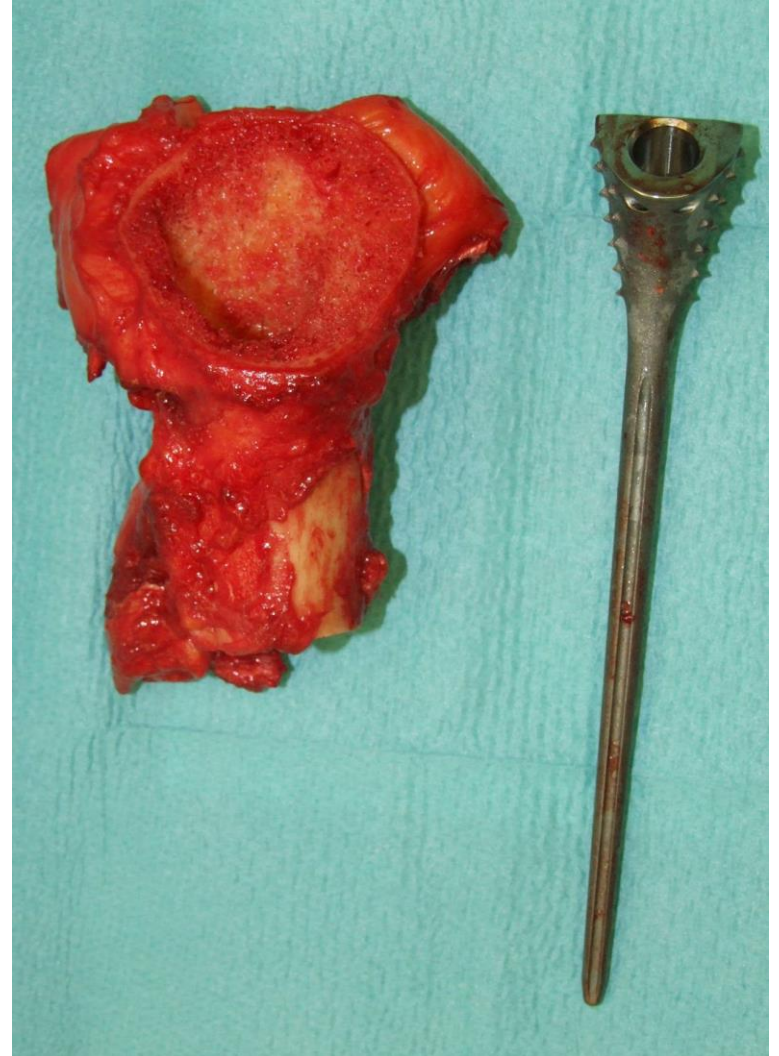
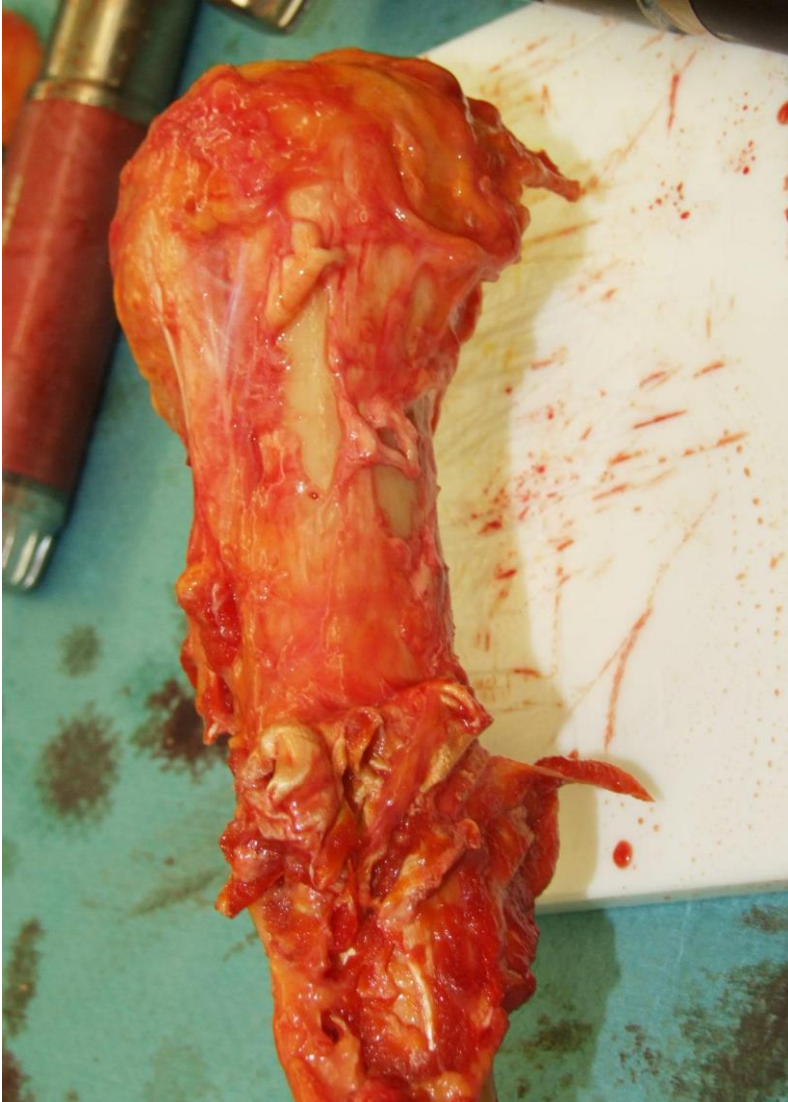


humerus; proximal; transarticular; APC

Surgery: June 30th, 2009

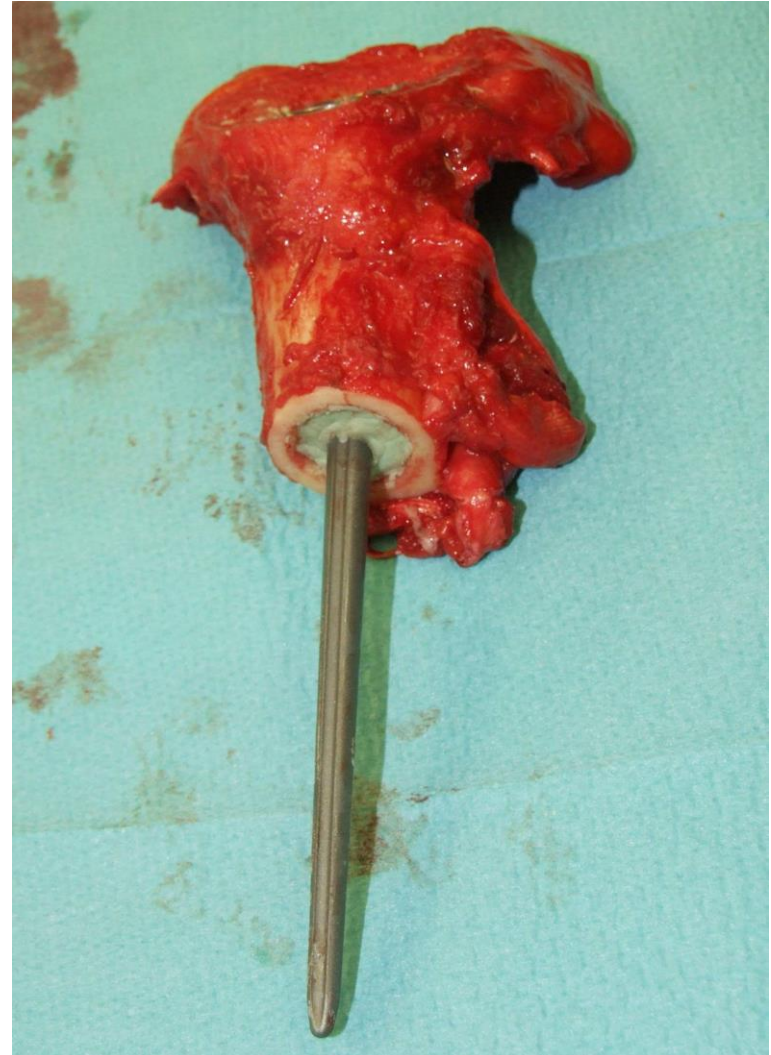
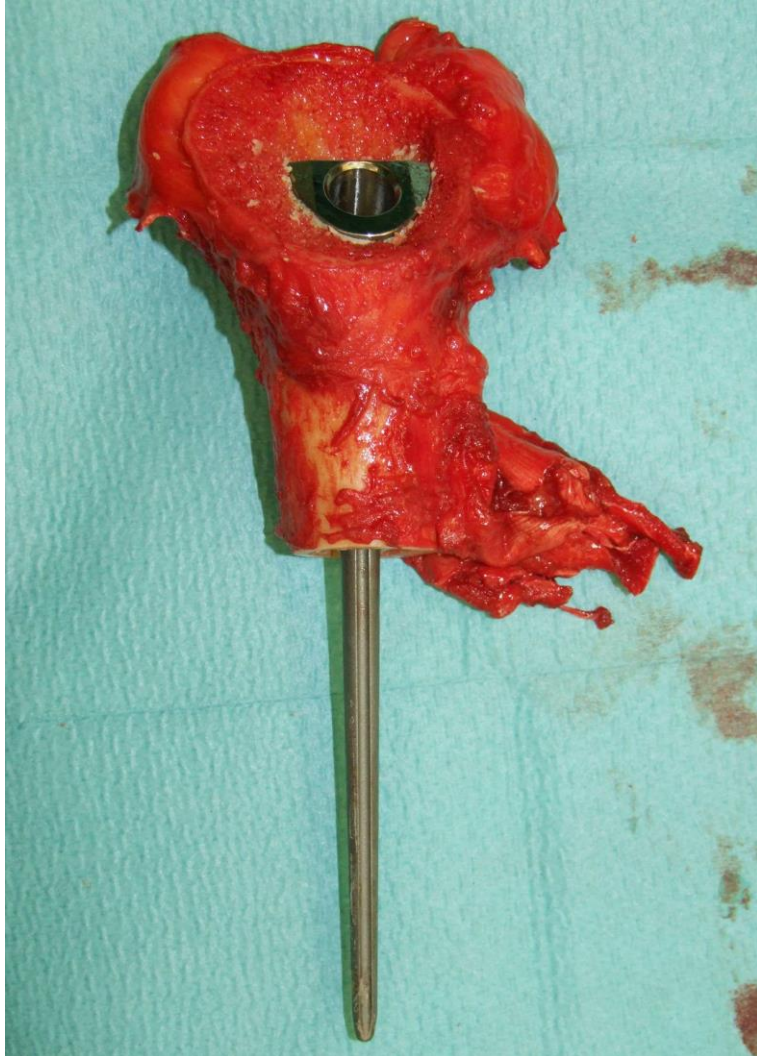


humerus; proximal; transarticular; APC Surgery: June 30th, 2009



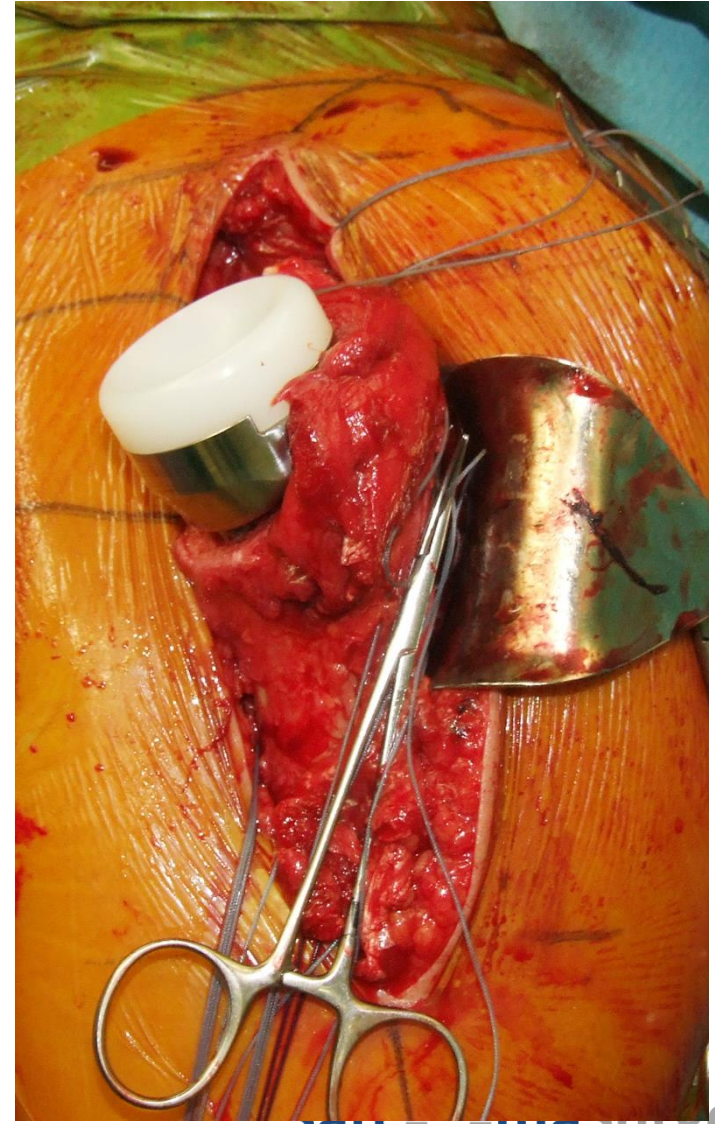
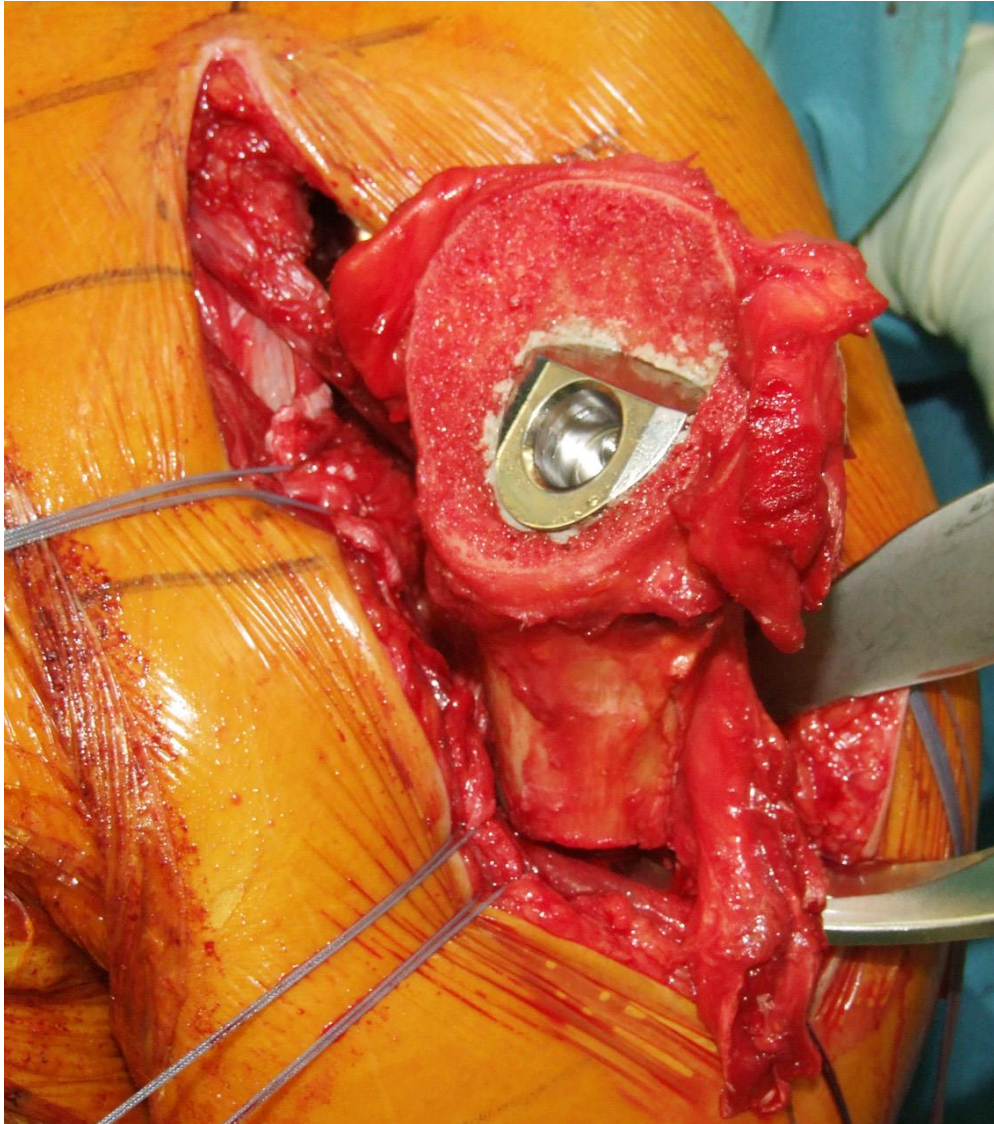
humerus; proximal; transarticular; APC

Surgery: June 30th, 2009

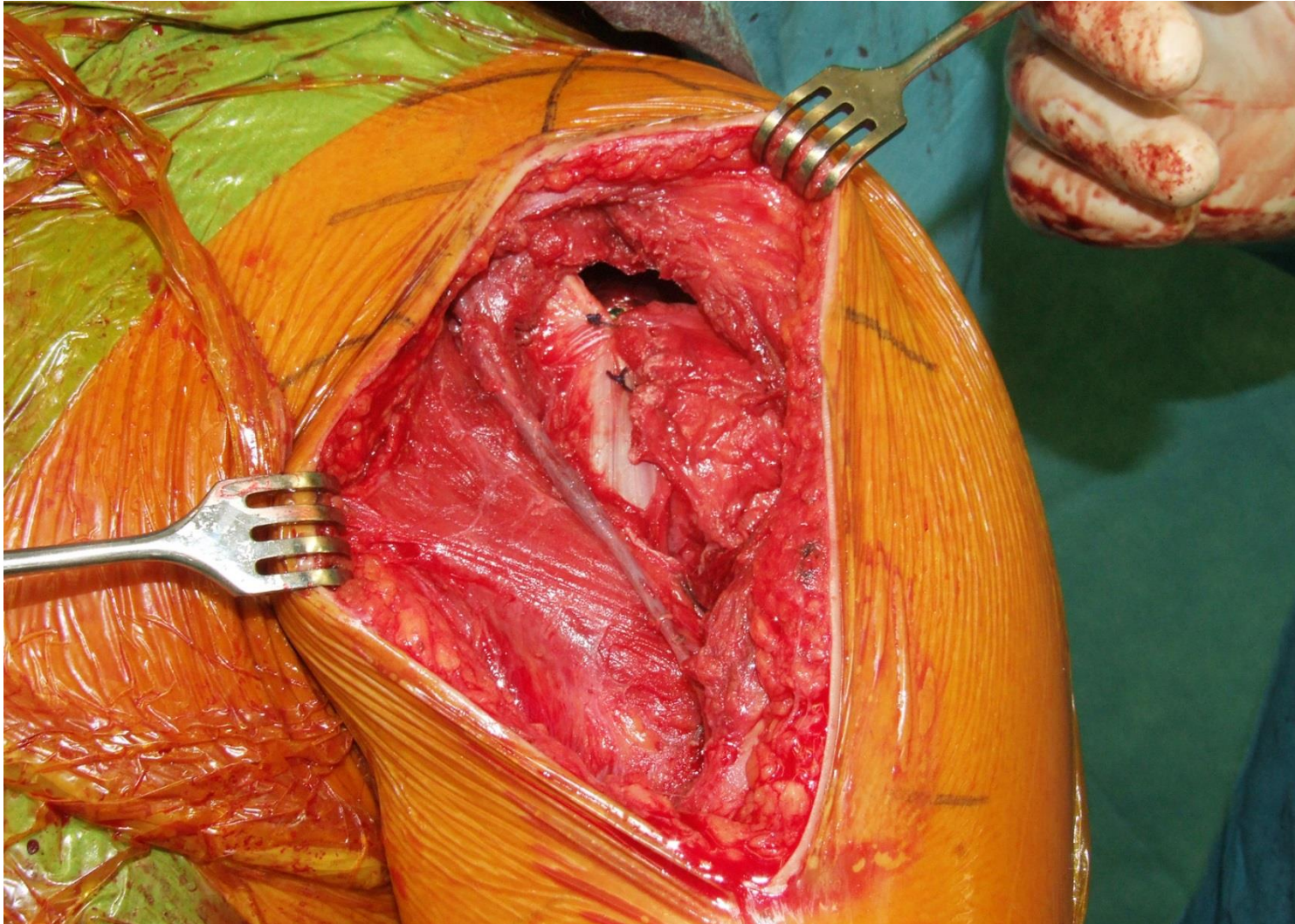

humerus; proximal; transarticular; APC

Surgery: June 30th, 2009

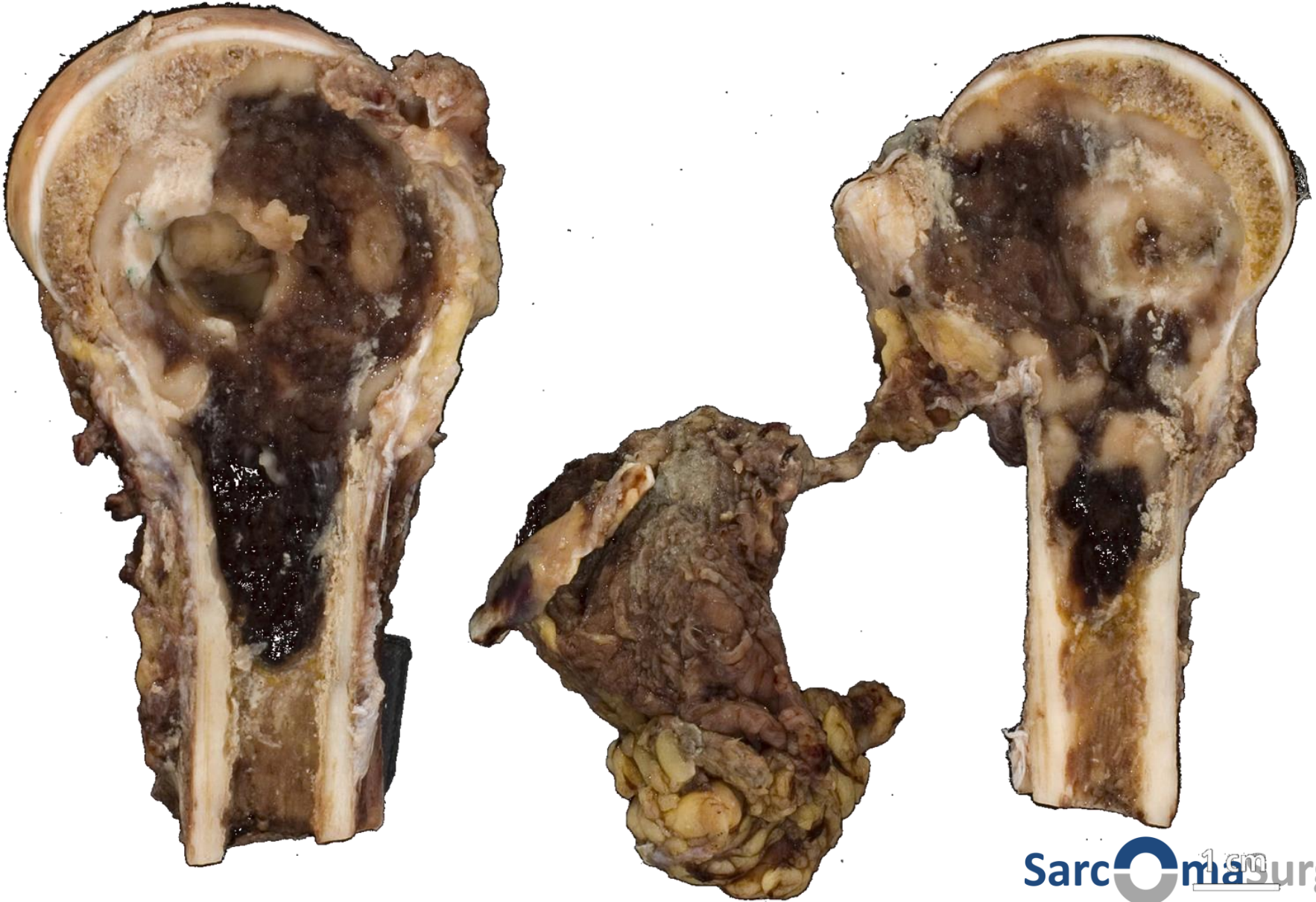


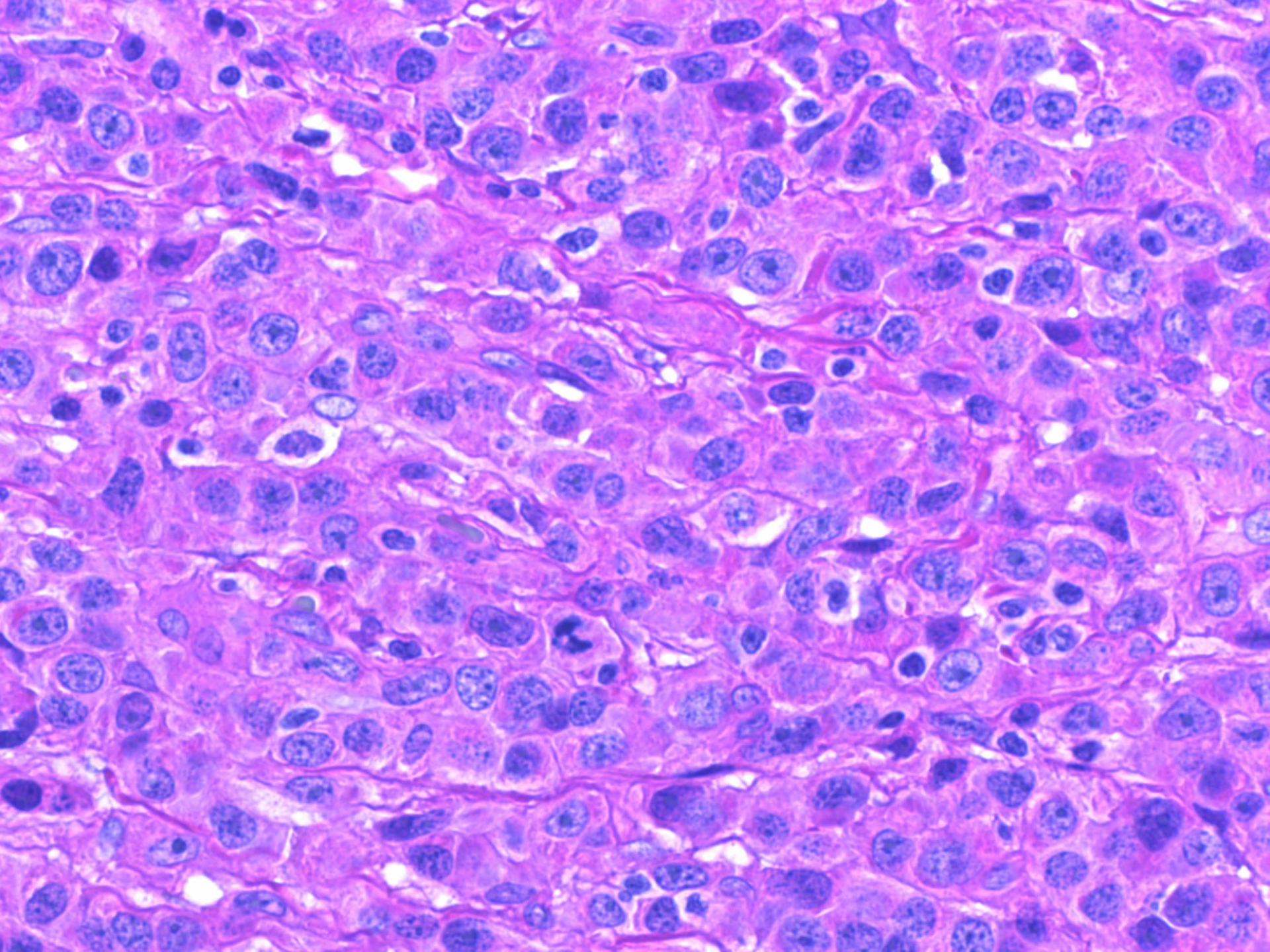
humerus; proximal; transarticular; APC Surgery: June 30th, 2009

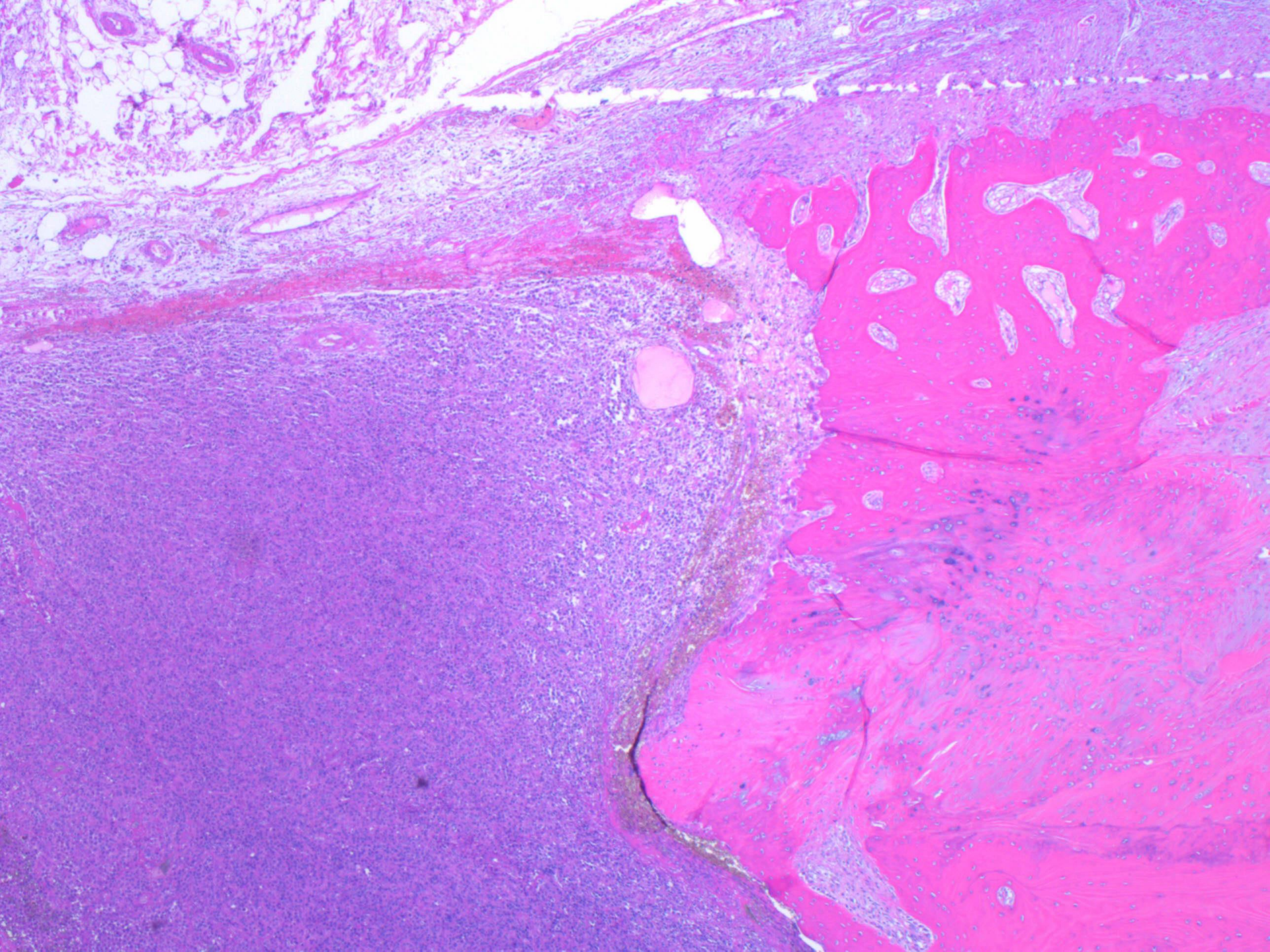


humerus; proximal; transarticular; APC

Surgery: June 30th, 2009





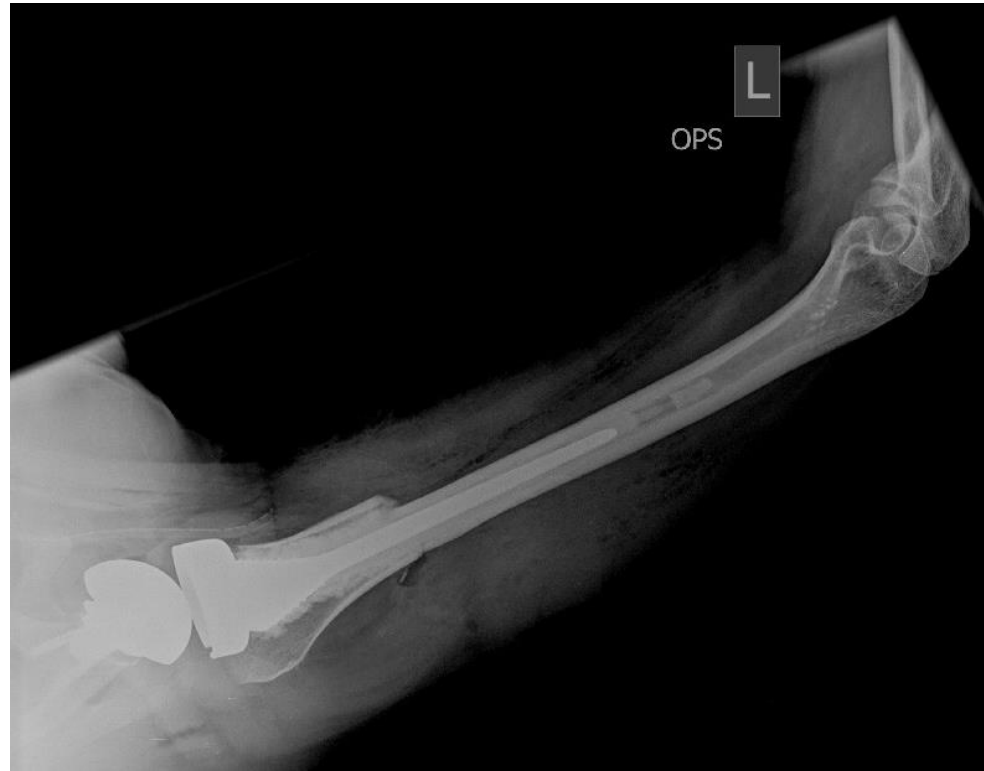
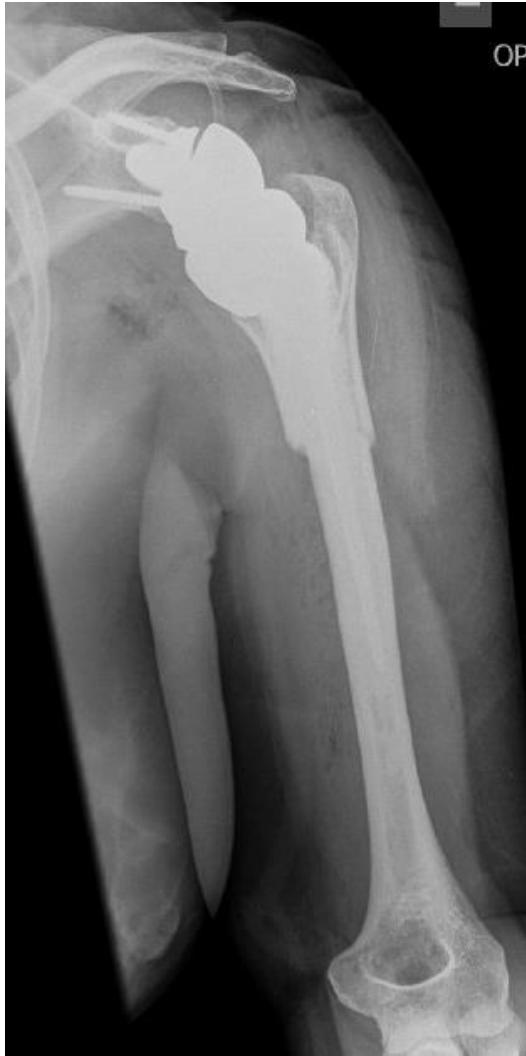
Diagnose

Humeruskopfresektat links mit Infiltraten des bekannten Plasmazellmyeloms , fokal mit Durchbruch der Kortikalis und Ausbreitung ins periostäre Weichgewebe. Kein Tumornachweis am Resektionsrand. Kein Gelenkeinbruch.

humerus; proximal; transarticular; APC

Xray: June 30th, 2009



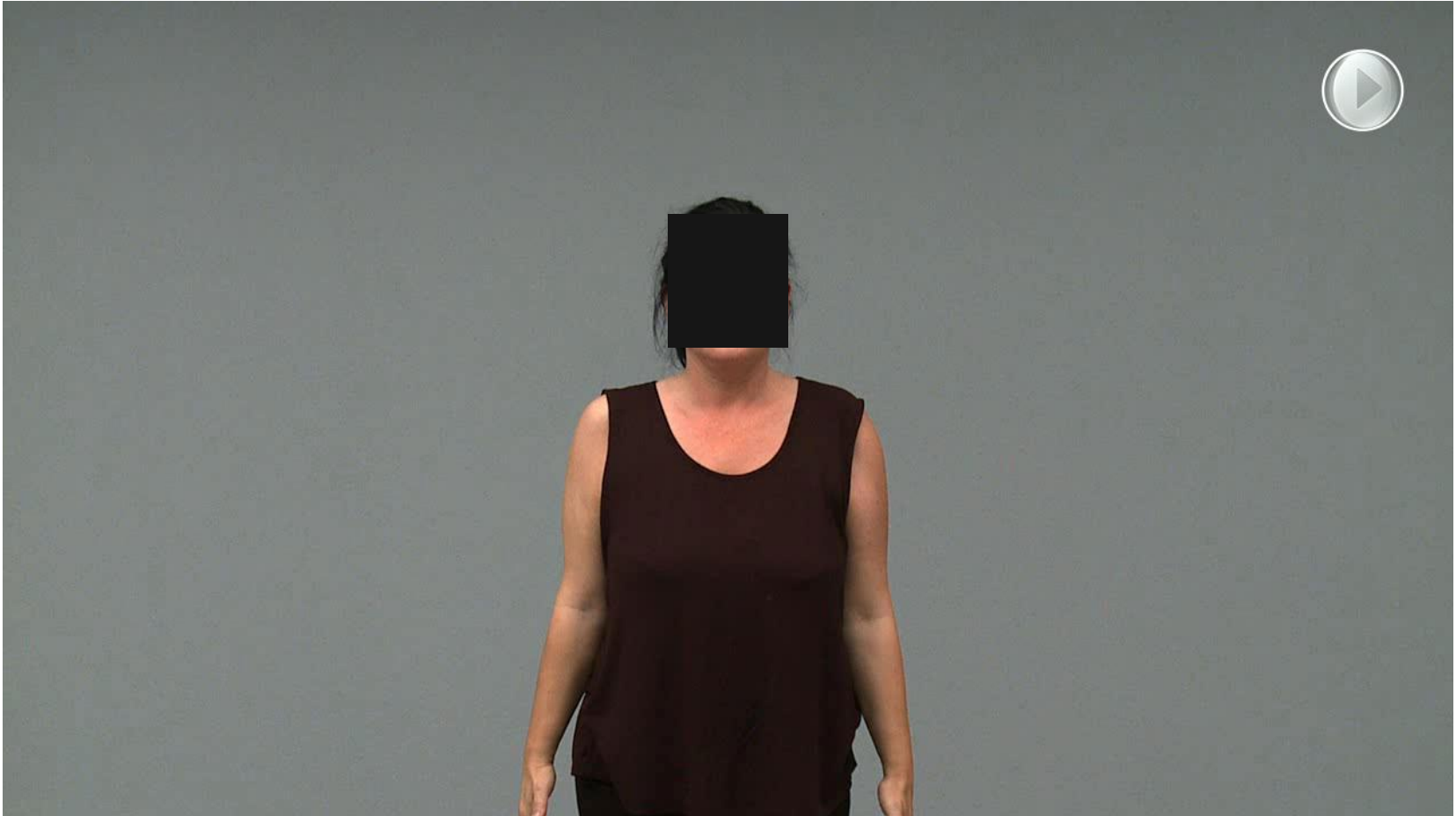humerus; proximal; transarticular; APC

Radiooncology Lucerne:

**12 x 3 Gy = 36 Gy humerus from August
27 to September 14, 2009**

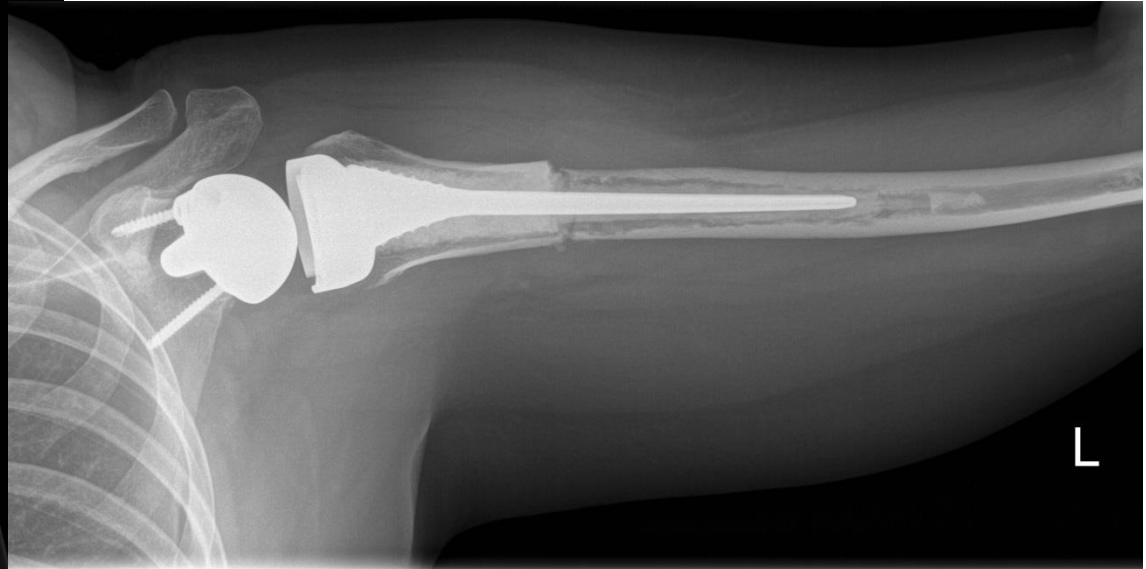
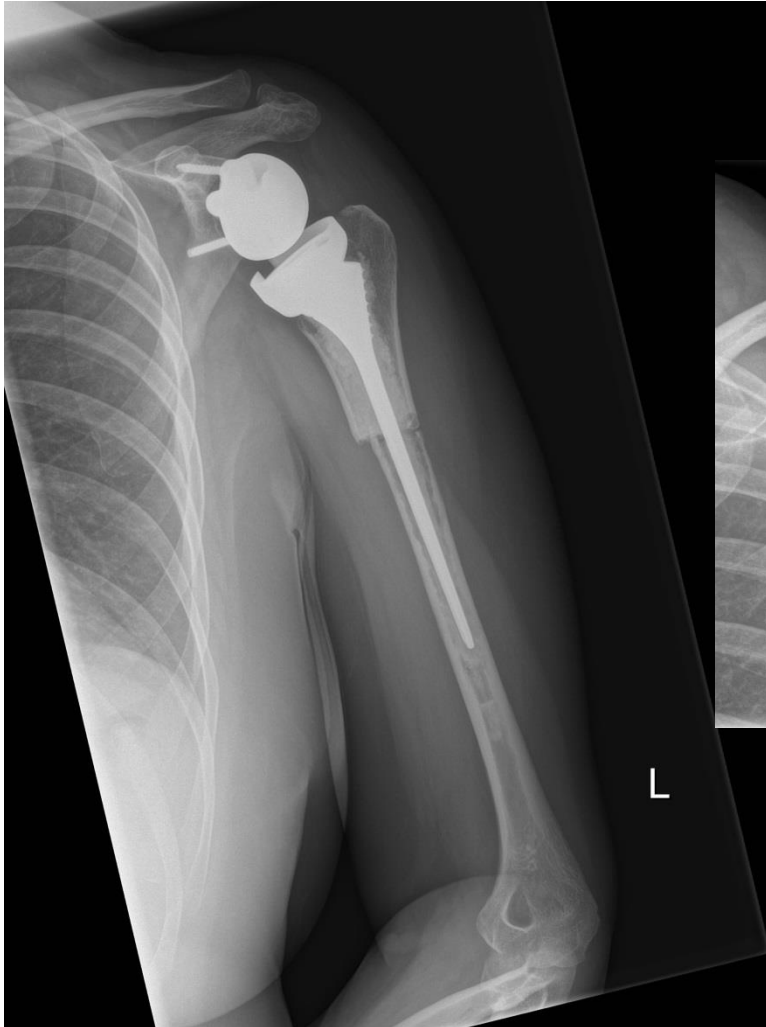
humerus; proximal; transarticular; APC

October 21, 2009 (4 ms postop)




humerus; proximal; transarticular; APC

Xray: July 28th, 2010



humerus; proximal; transarticular; APC

August 02, 2010 (14 ms postop)



humerus; proximal; transarticular; APC

March 2011

New osteolysis in cranium, sternum and thoracal vertebral body 4

**Radiotherapy of the sternum
(07.03.-16.03.11): 21 Gy**

humerus; proximal; transarticular; APC

Chemotherapy (02.03.11-30.05.11):

Velcade, Endoxan, Dexamethosan, Zometa

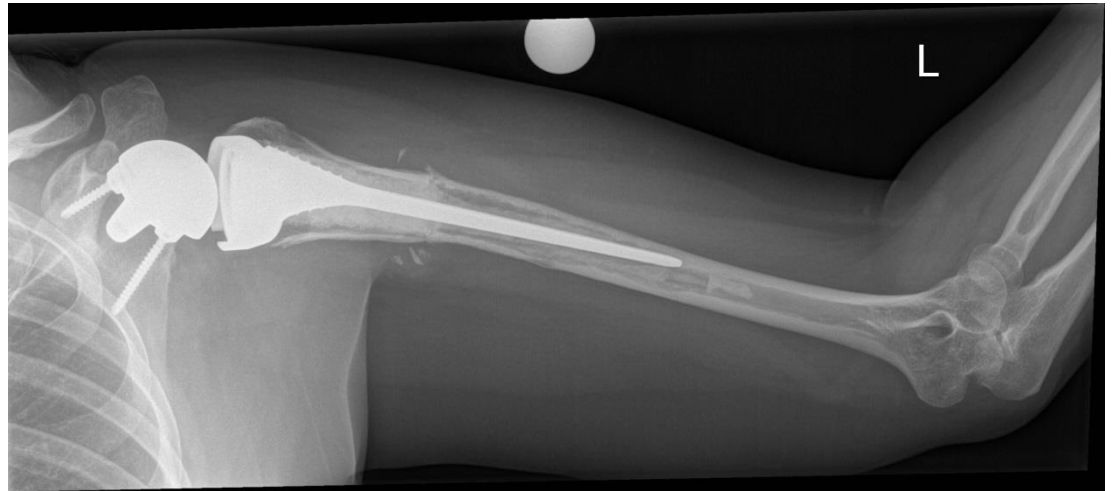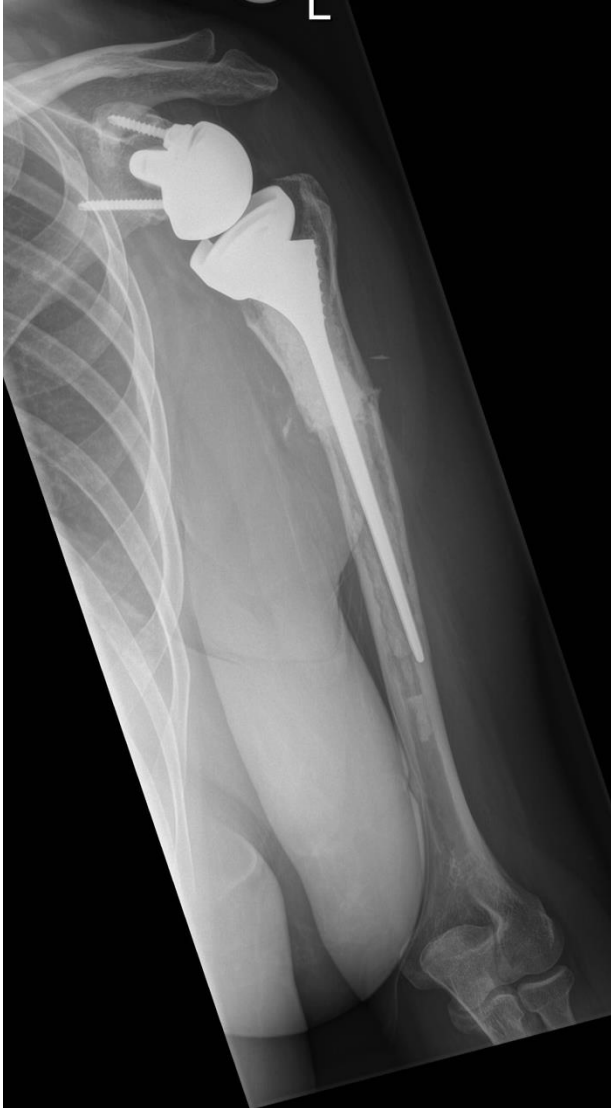humerus; proximal; transarticular; APC

Autologous stem cell transplantation 22.06.11

Complete remission 11.07.11

humerus; proximal; transarticular; APC

Xray: Aug 31st, 2011



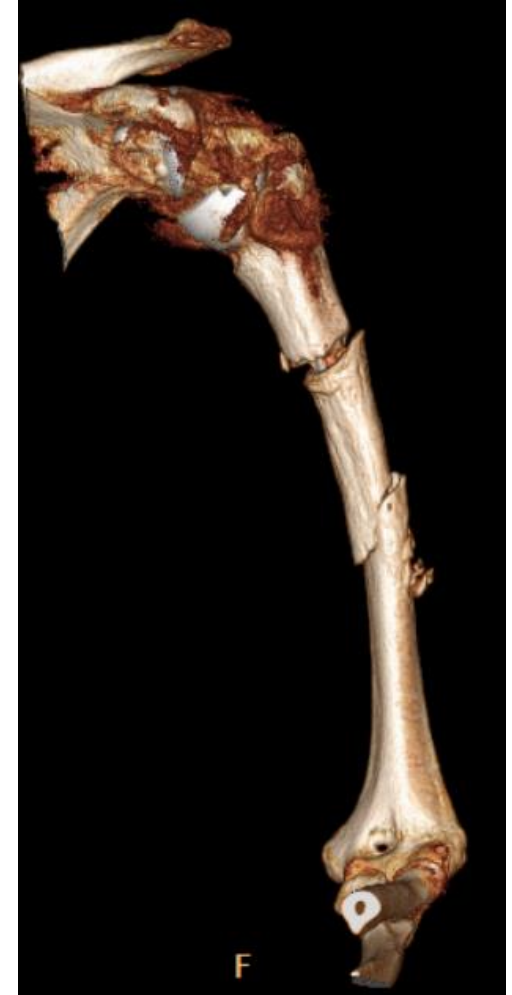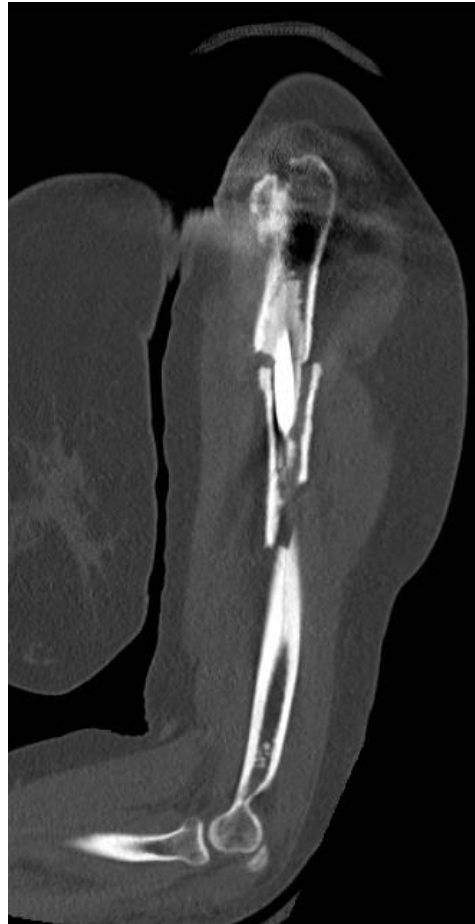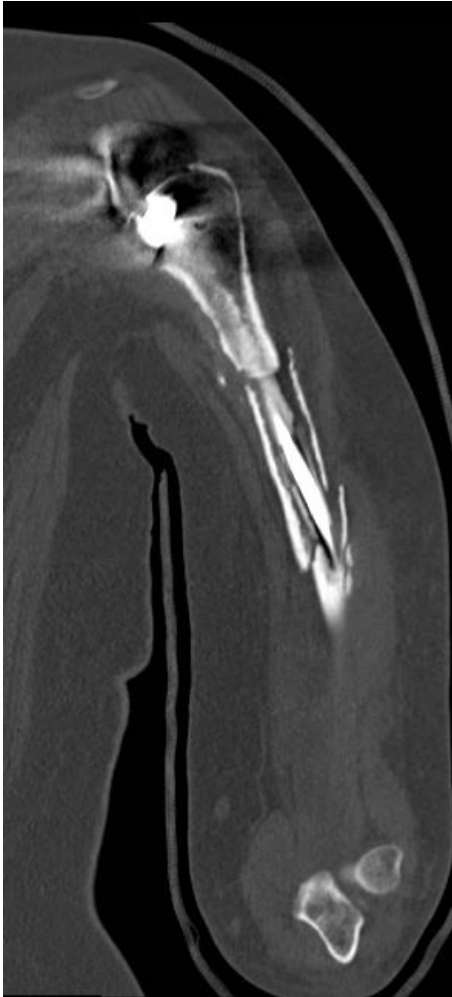
humerus; proximal; transarticular; APC

Downfall after a concert 21.02.12

**Cracking sound in humerus, sudden
onset of pain**

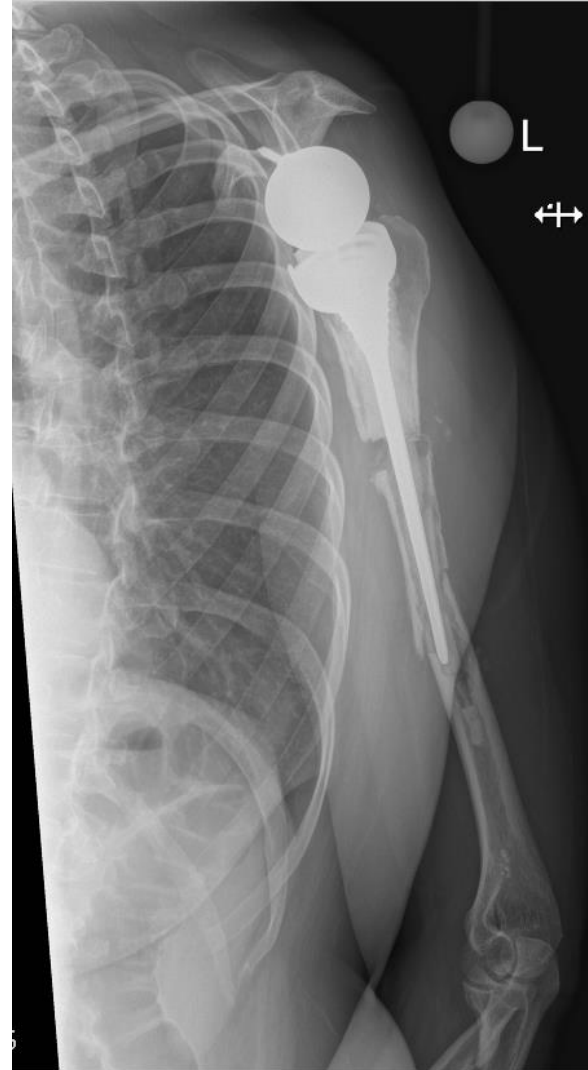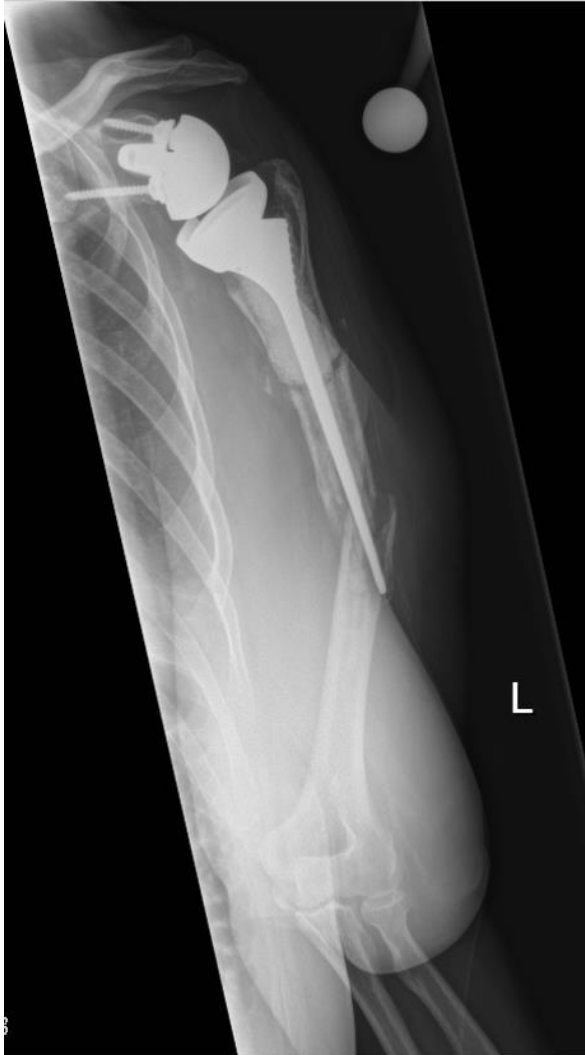humerus; proximal; transarticular; APC

CT: February 27th 2012



humerus; proximal; transarticular; APC

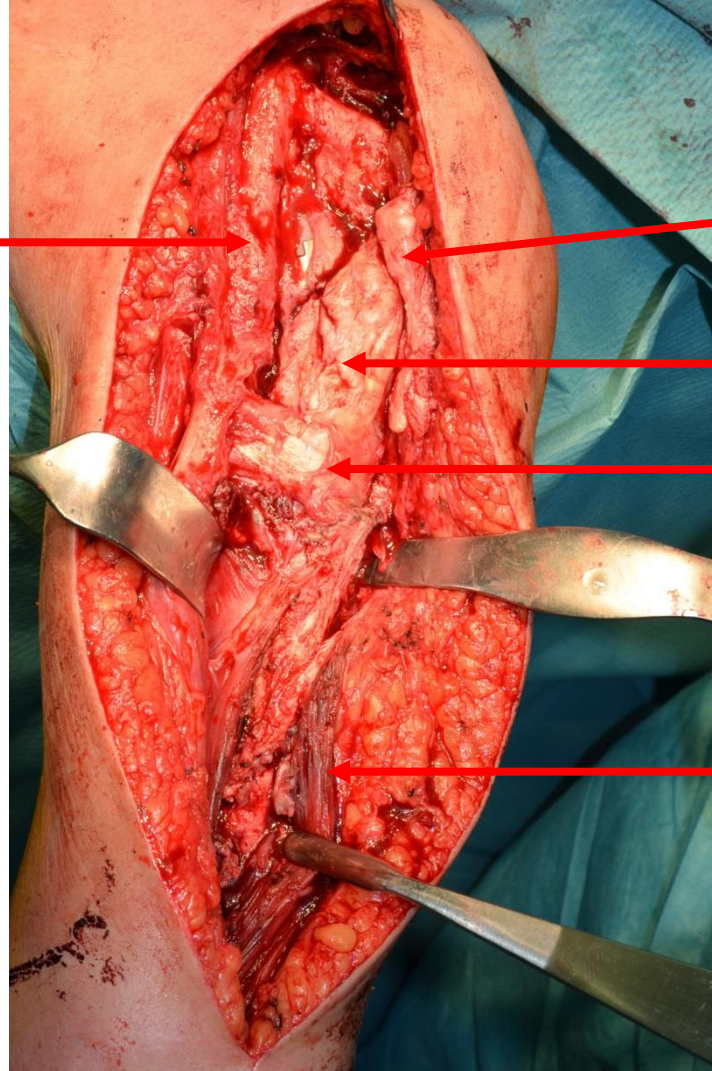
Xray: March 26th, 2012



humerus; proximal; transarticular; APC

Surgery: March 27th, 2012

Conjoint tendon



M. deltoideus

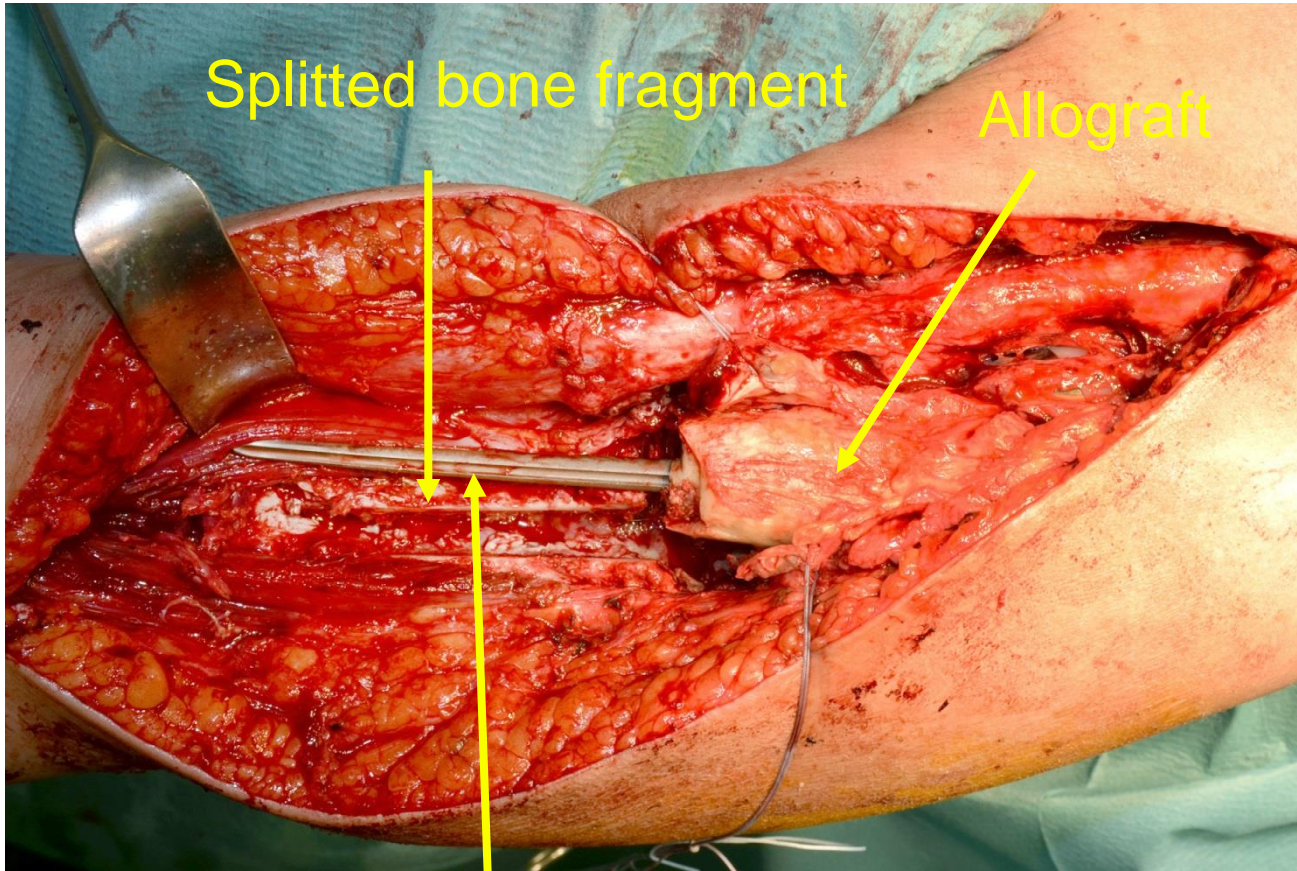
Allograft

Episcopo transfer

M. Biceps brachii

humerus; proximal; transarticular; APC

Surgery: March 27th, 2012



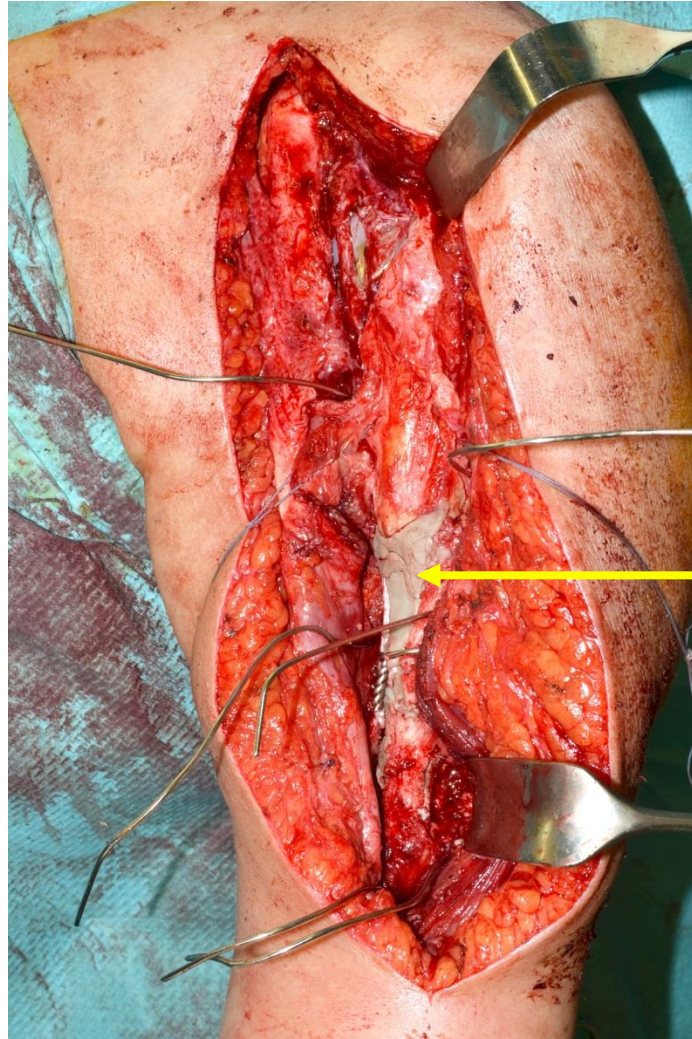
Splitted bone fragment

Allograft

Distal portion of prosthesis

humerus; proximal; transarticular; APC

Surgery: March 27th, 2012

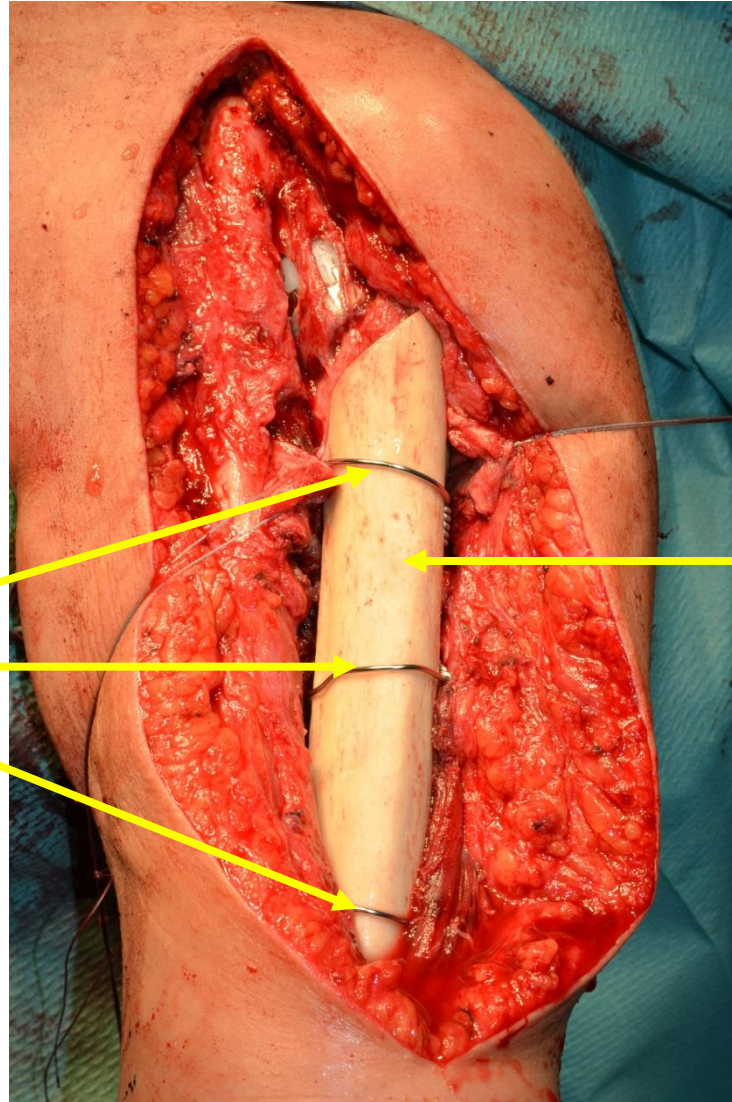


Cement

humerus; proximal; transarticular; APC

Surgery: March 27th, 2012

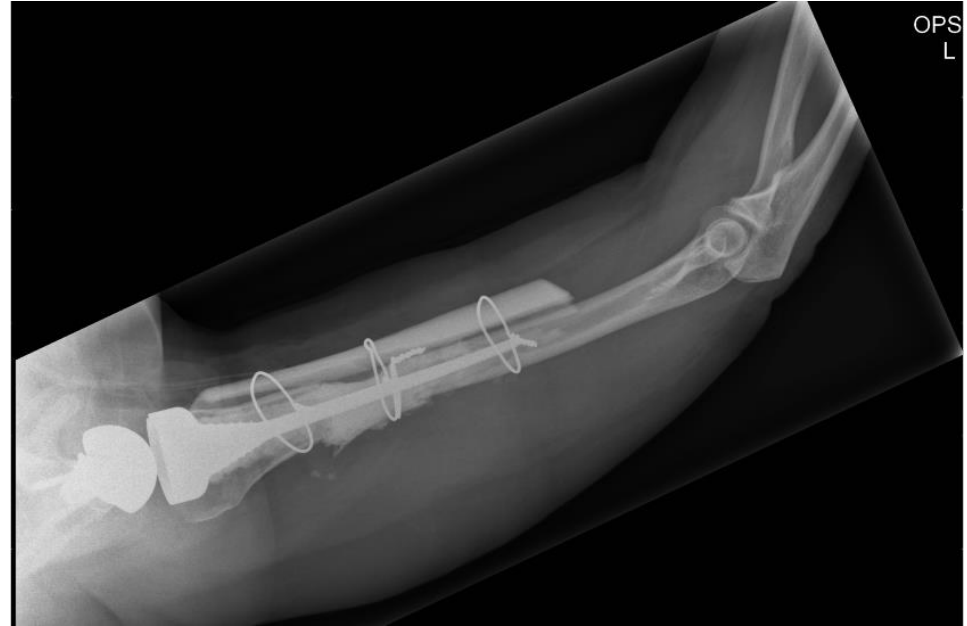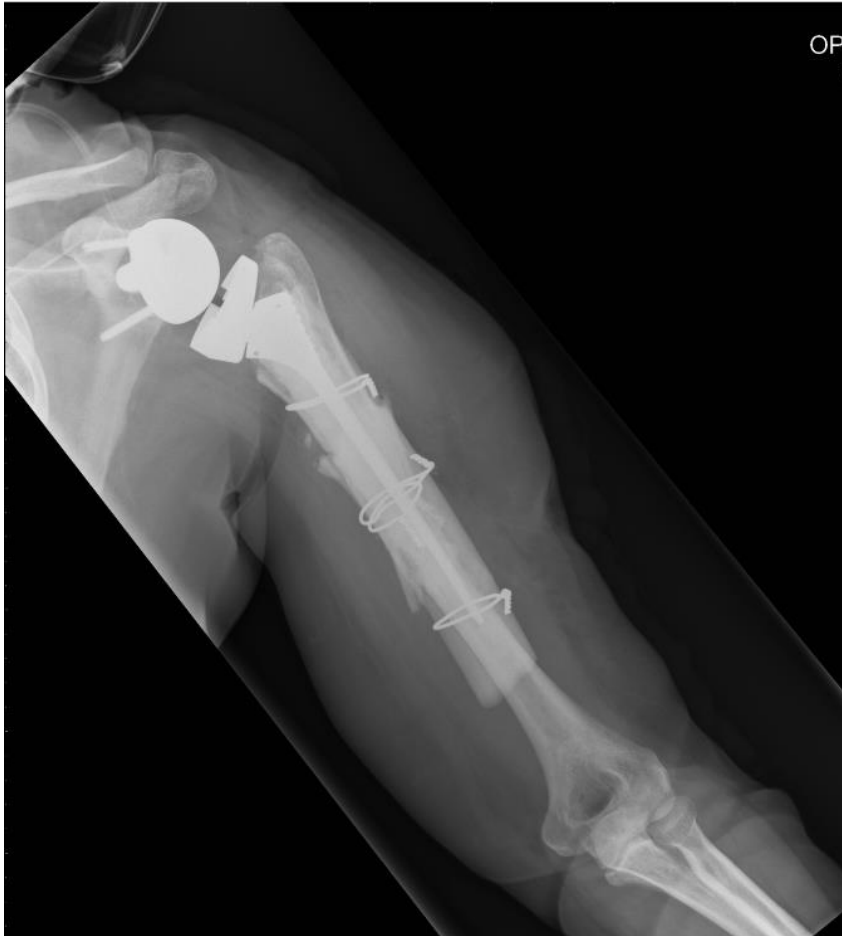Cerclage



Strut Femur
Allograft

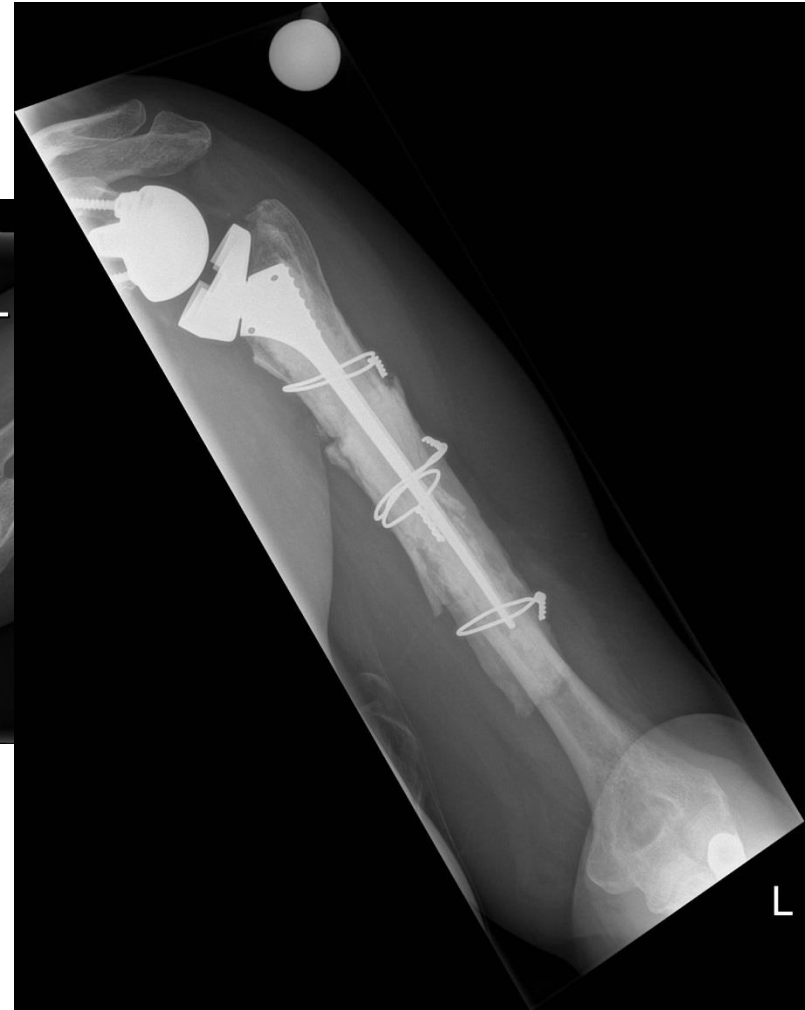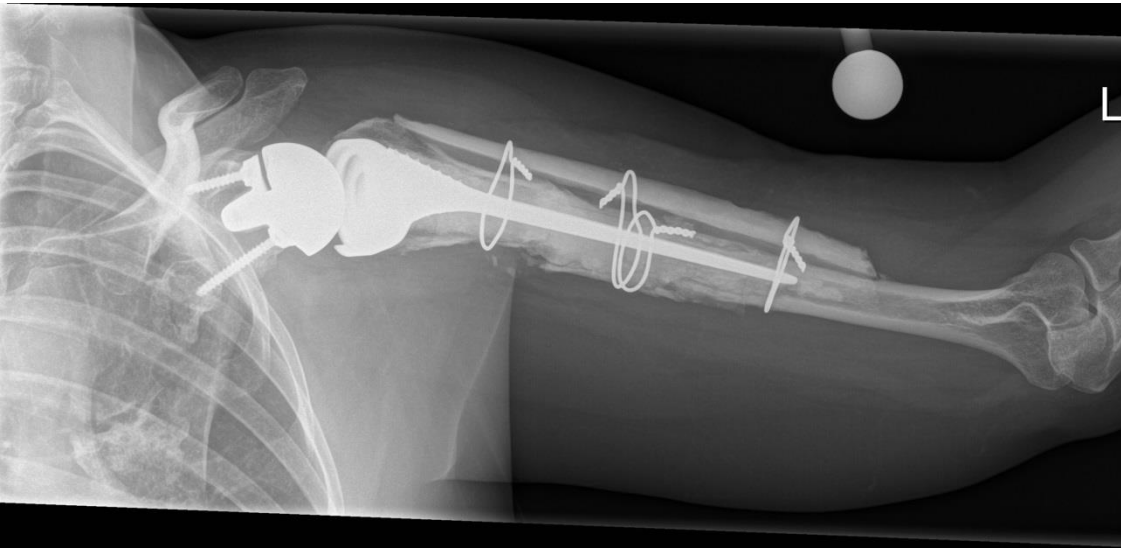
humerus; proximal; transarticular; APC

Xray: March 27th, 2012



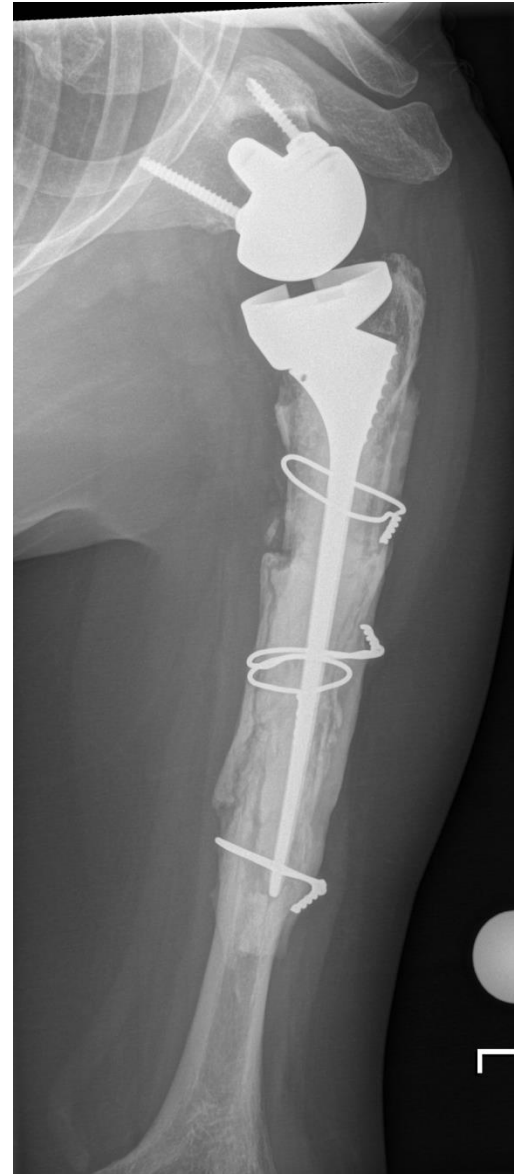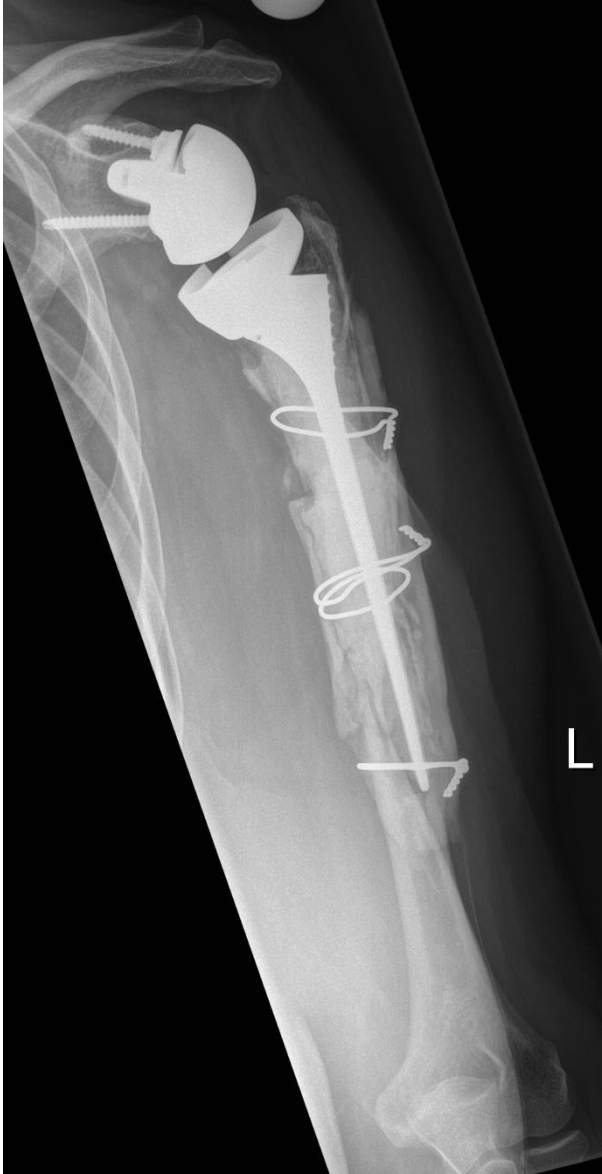humerus; proximal; transarticular; APC

Xray: June 20th, 2012



humerus; proximal; transarticular; APC

Xray: March 13th, 2013



humerus; proximal; transarticular; APC March 13, 2013 (12 ms postop)



humerus; proximal; transarticular; APC

October 31, 2017

Stable disease under chemotherapy