

Scapula; partial inferior

♂ 37y, Magaziner

1st referral: 19.01.2011

HPI:

14 days ago in the shower first palpable swelling in the R shoulder blade. No pain, no restriction. Presentation at GP with further imaging.

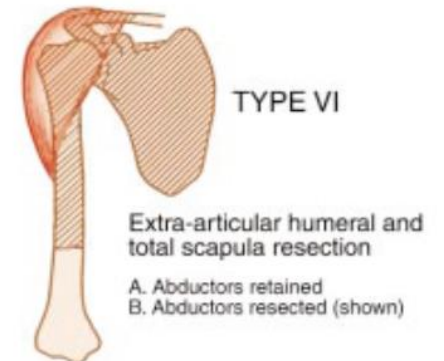
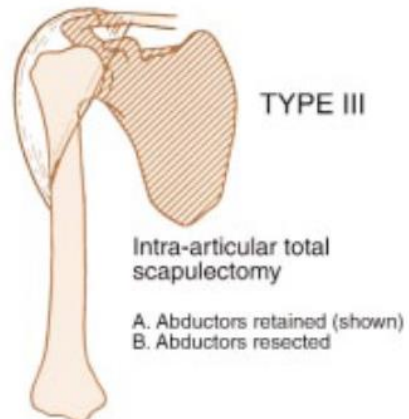
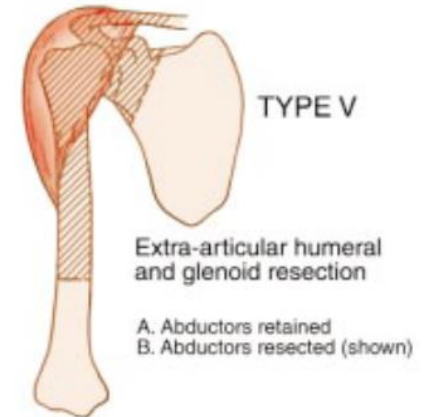
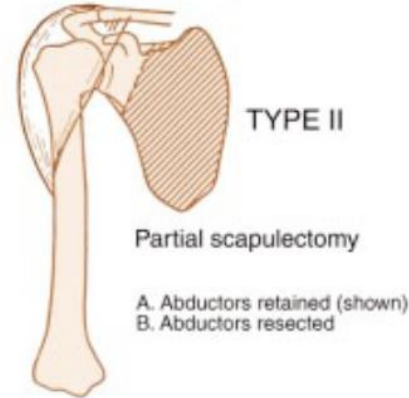
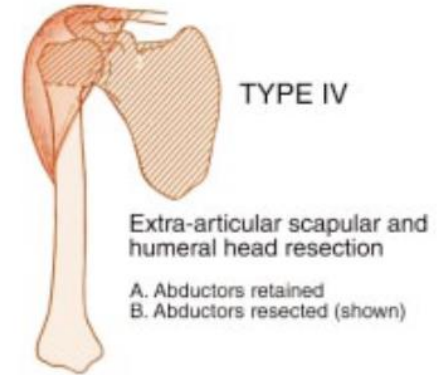
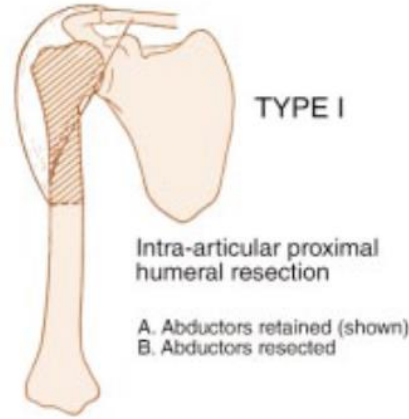
PMH:

- Arterial hypertension
- Nicotine abuse
- Tonsillectomy in 1981
- Appendicitis 2007

axillary nerve?

intra- / transarticular?

level of OT & abductor?

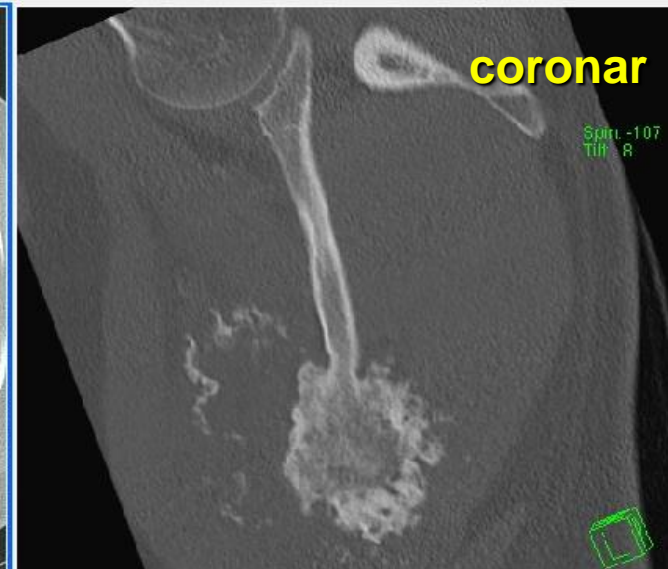
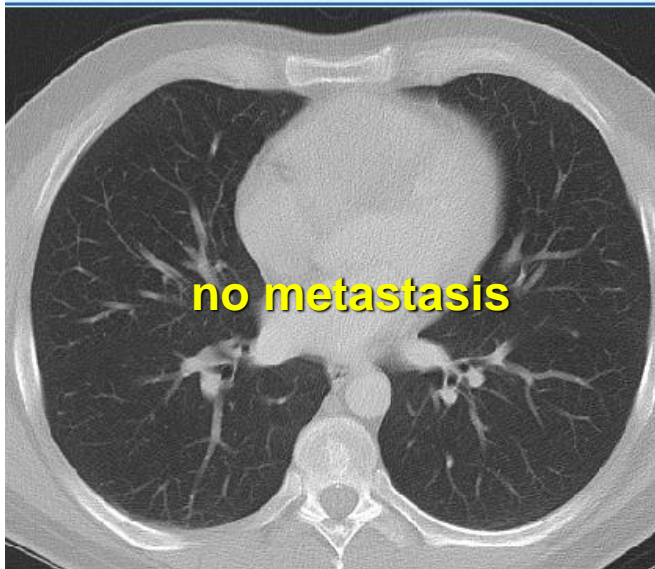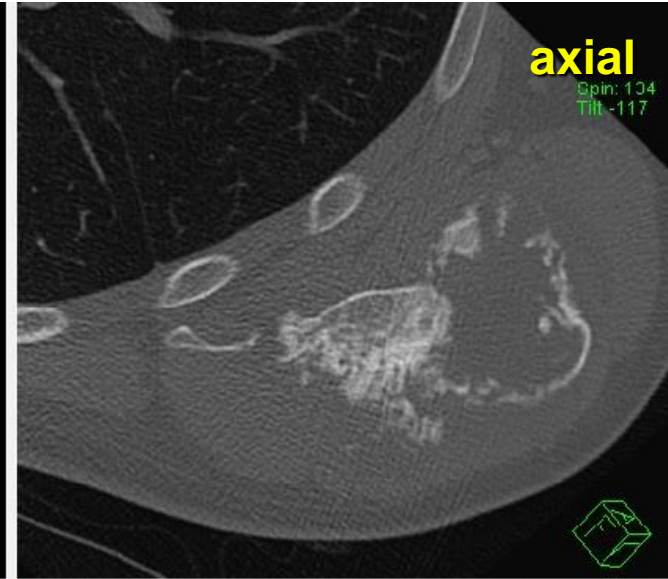
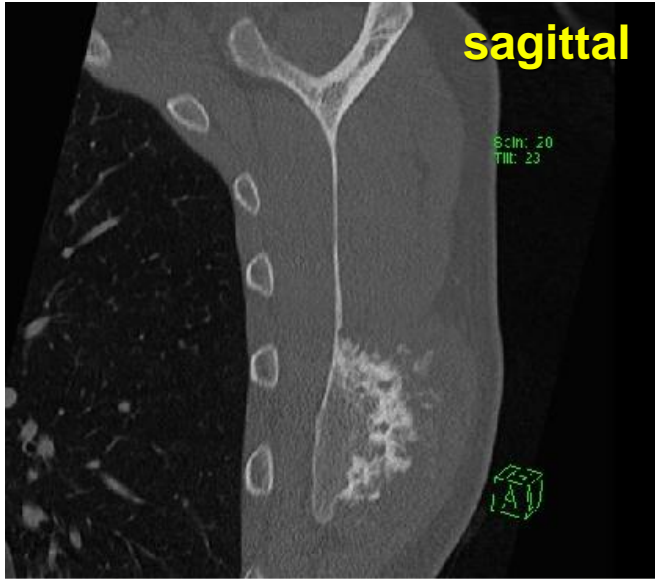


Scapula; partial inferior consultation, Jan 19, 2011

clinical findings:

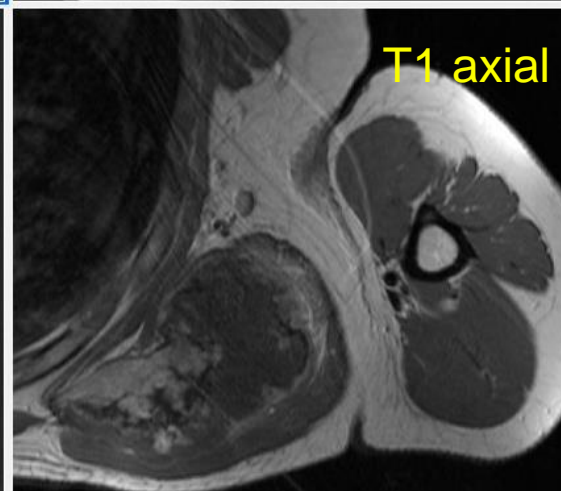
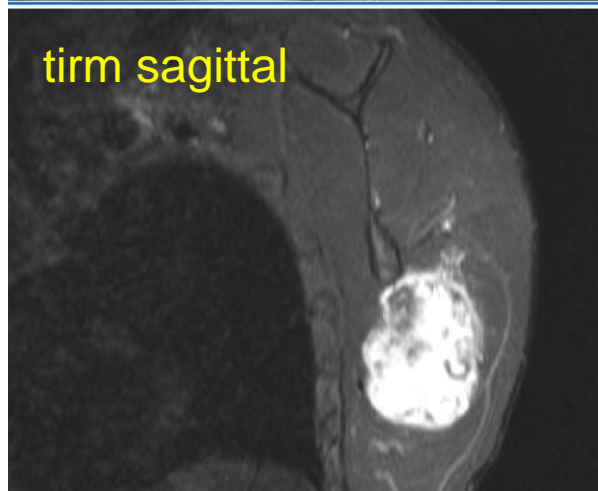
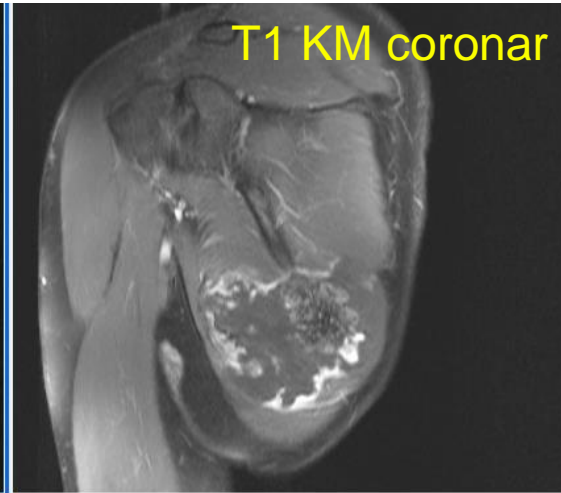
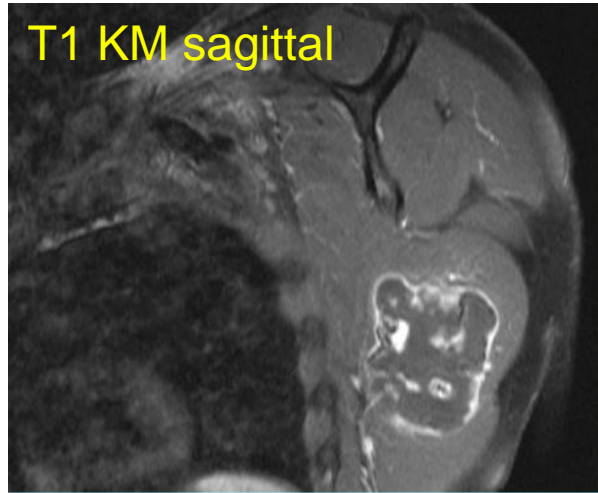
- 10 x 7 cm hard tumor
- displaceable together with the scapula
- Flex and Abd 160 ° , IR T8
- lift-off test negative
- No AC pressure pain
- good strength in Abd, IR and ER rotation
- pDMS intact

Scapula; partial inferior CT chest+abd, Jan 7, 2011

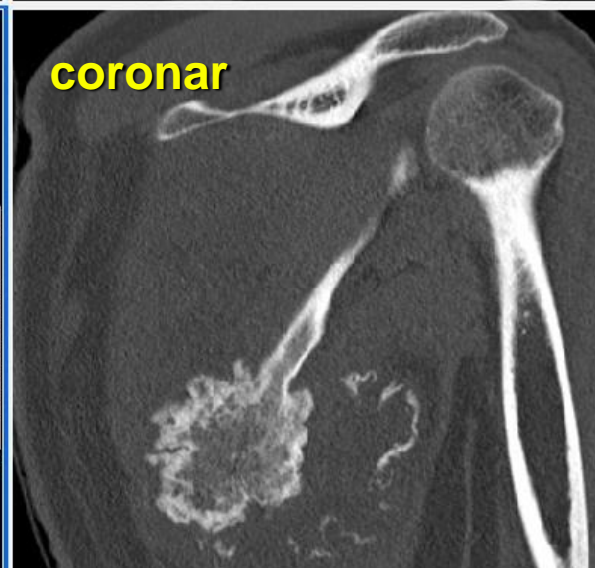
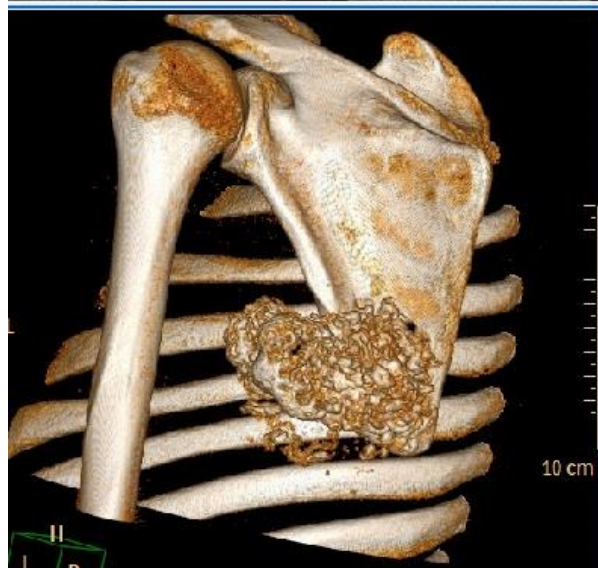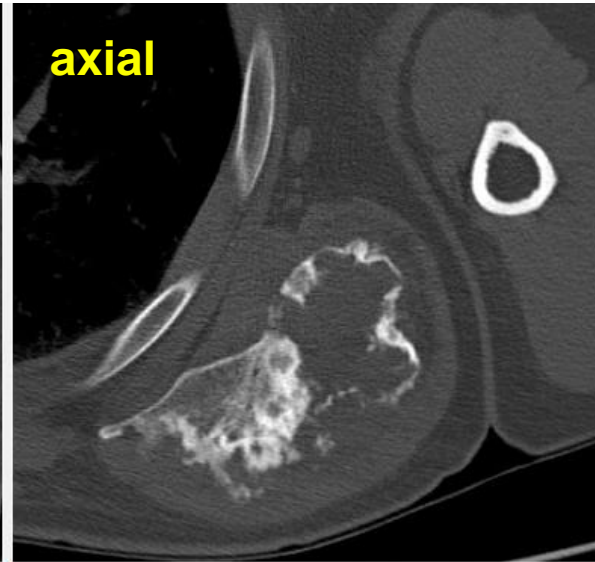

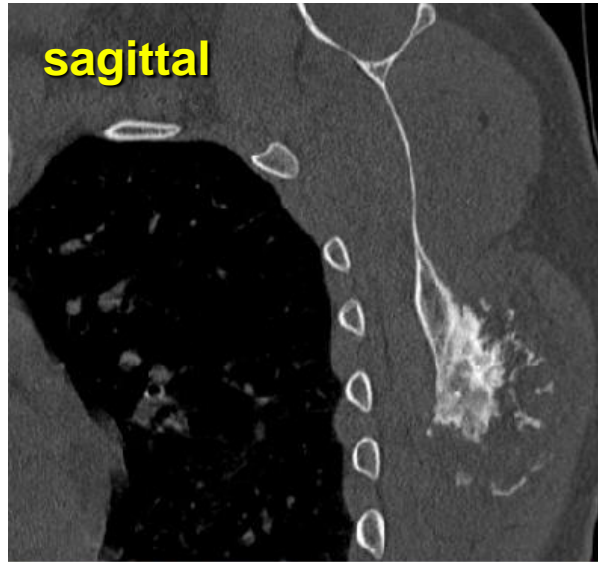
Scapula; partial inferior

MRI shoulder R, Jan 14, 2011

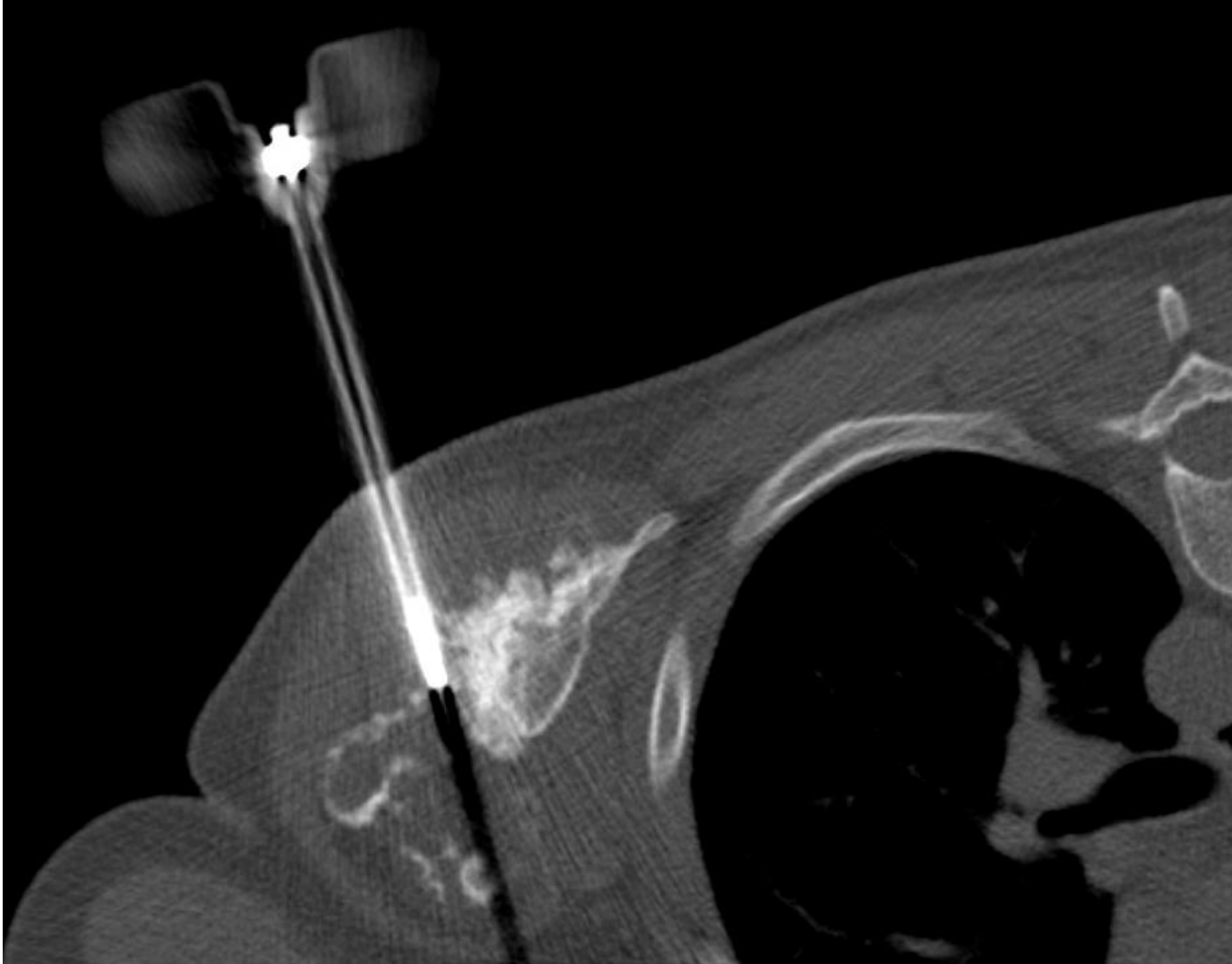

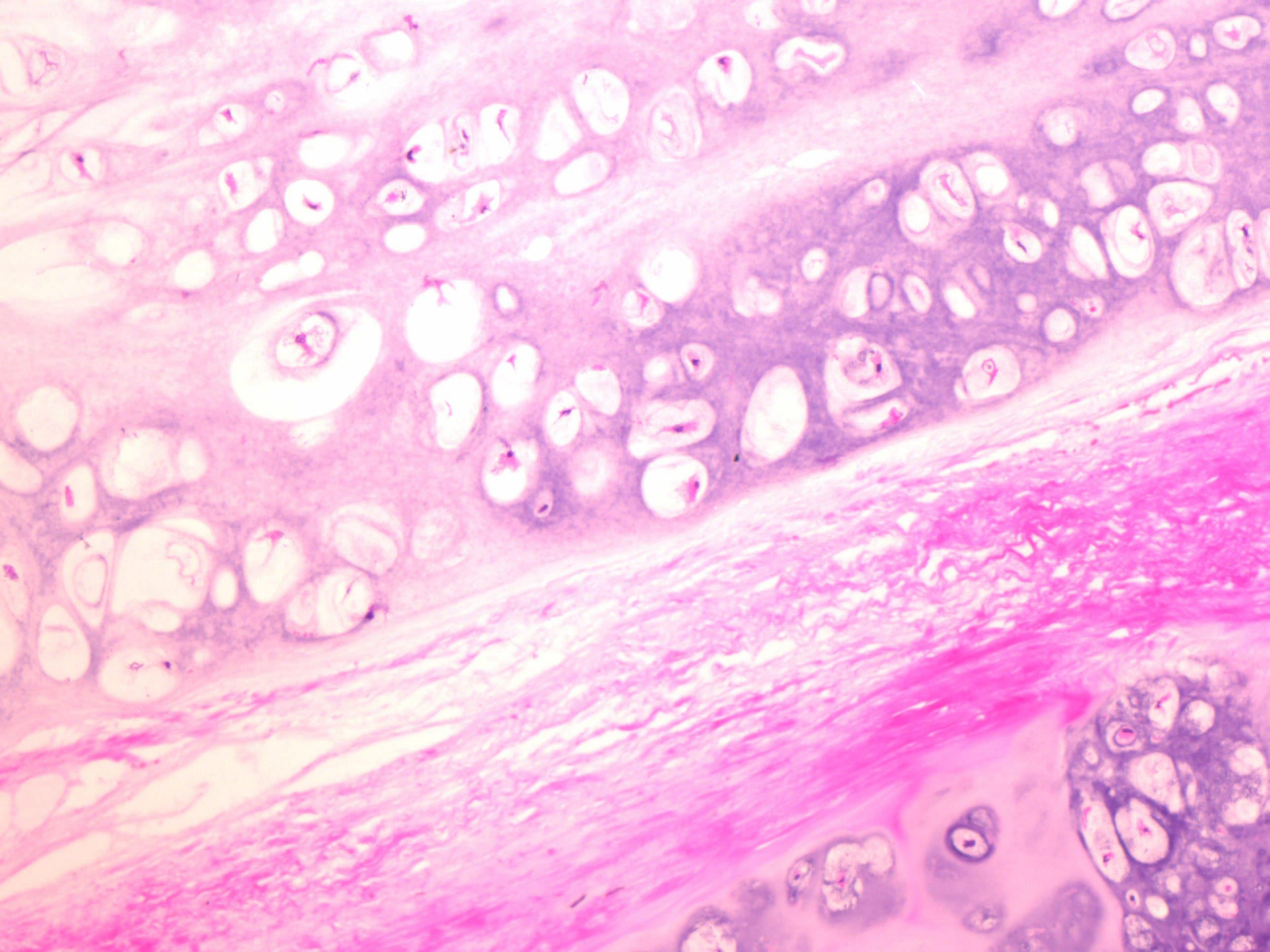
Scapula; partial inferior CT shoulder R, Jan 19, 2011



Scapula; partial inferior

CT- guided biopsy, Jan 19, 2011





Scapula; partial inferior

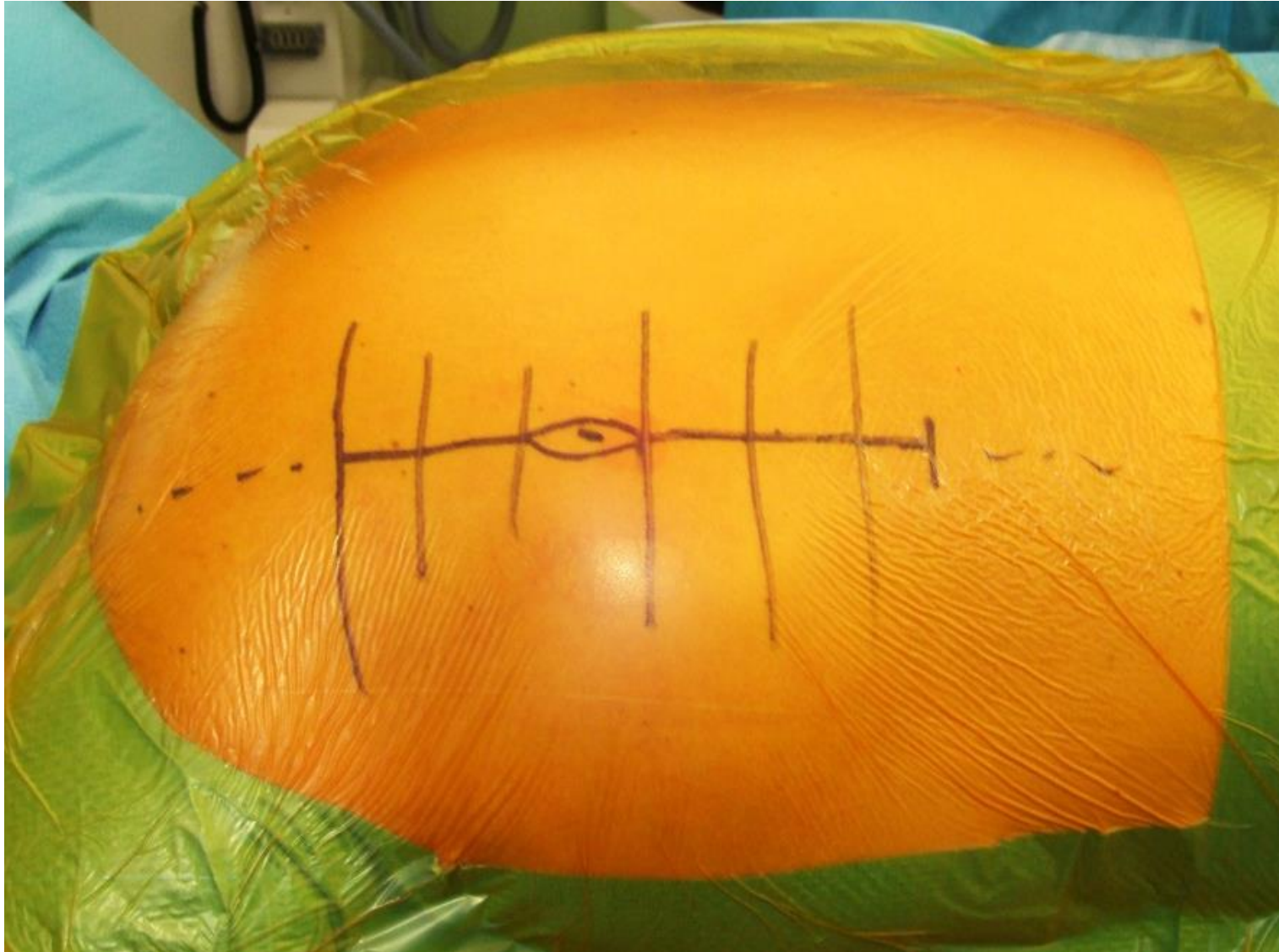
Result biopsy, Jan 19, 2011

Diagnose

Chondromatöse Neoplasie (Scapula links; vgl. Kommentar).

Die Histologie passt in Zusammenschau mit den radiologischen Befunden zum Bild eines konventionellen low-grade Chondrosarkoms.

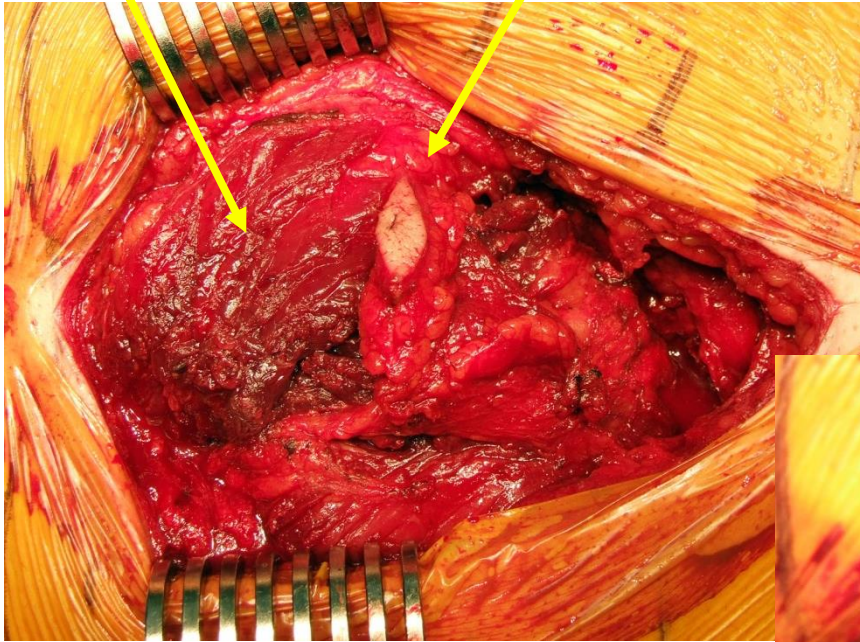
Scapula; partial inferior Surgery, Feb 01, 2011



Scapula; partial inferior Surgery, Feb 01, 2011

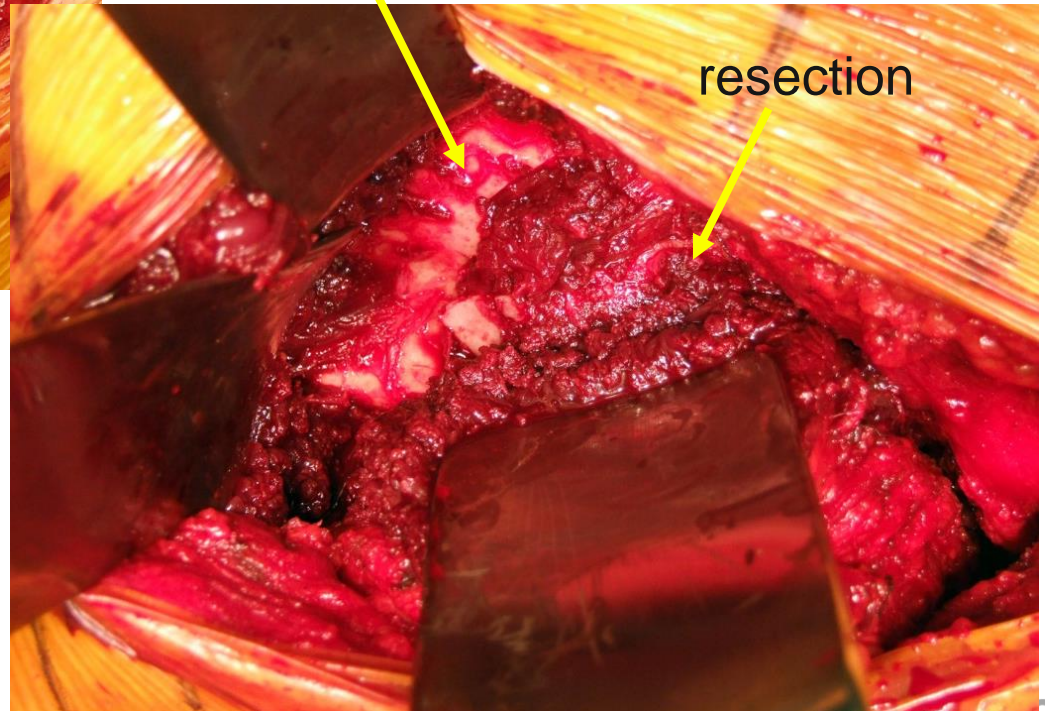Infraspinatus

biopsy

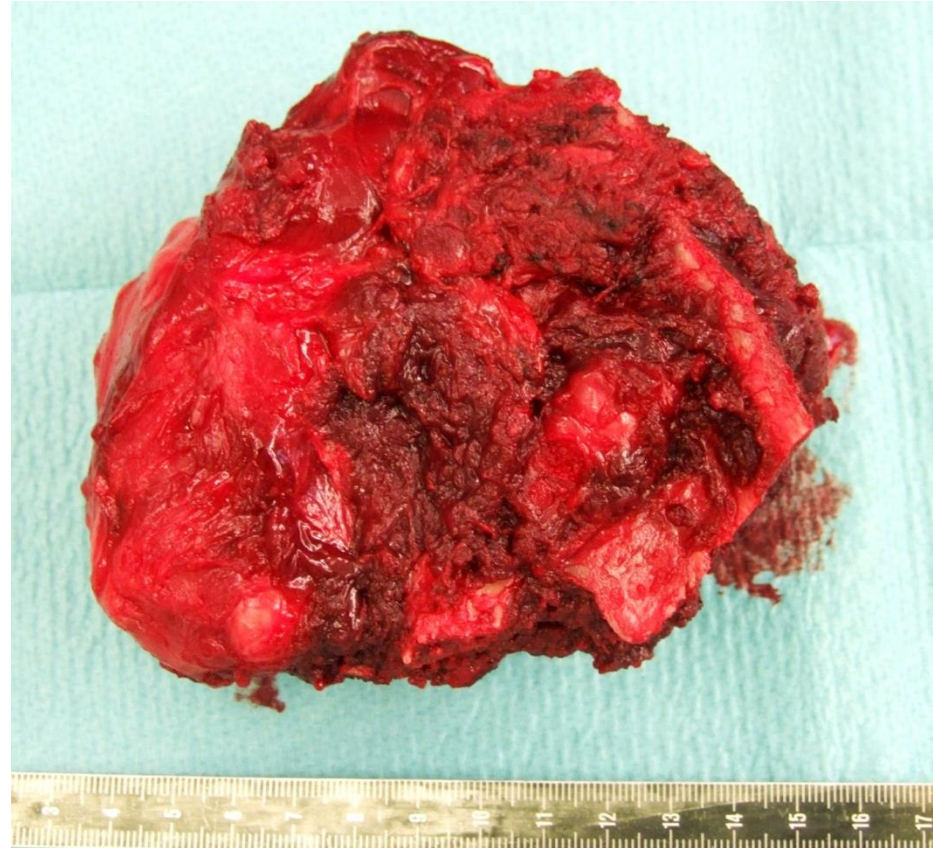
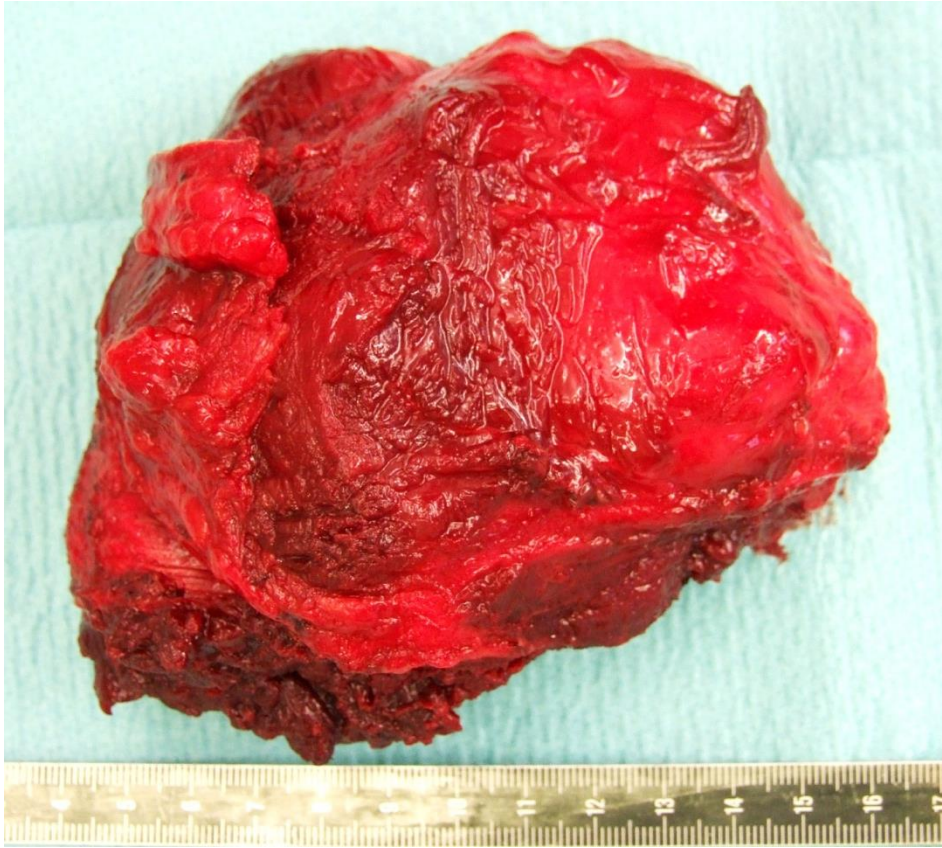
scapula

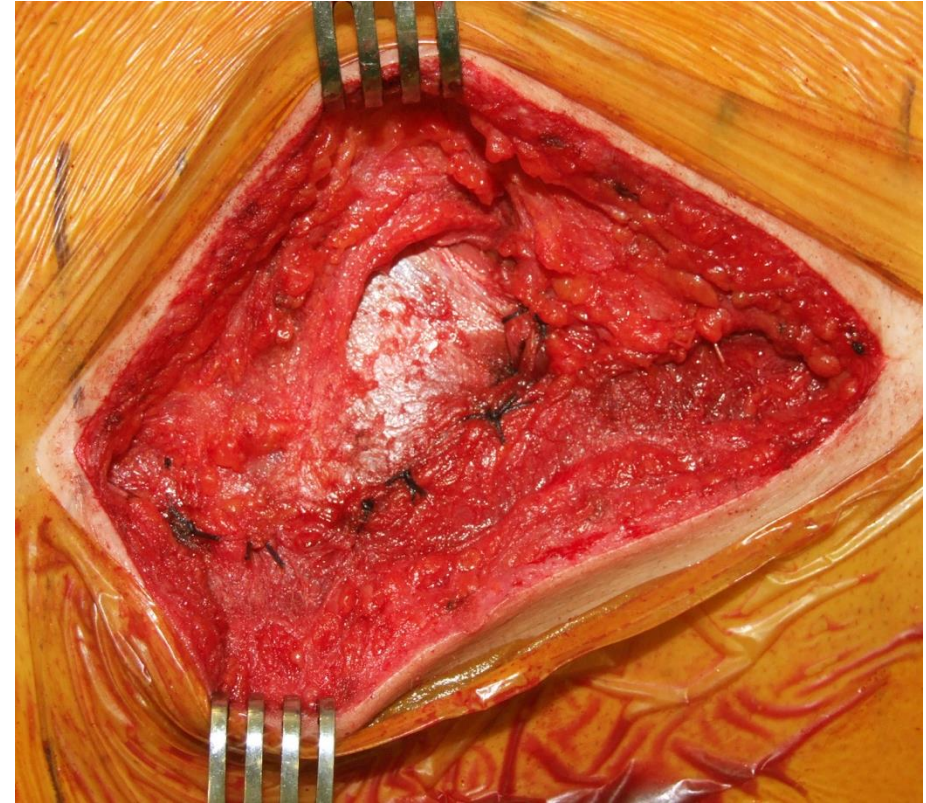
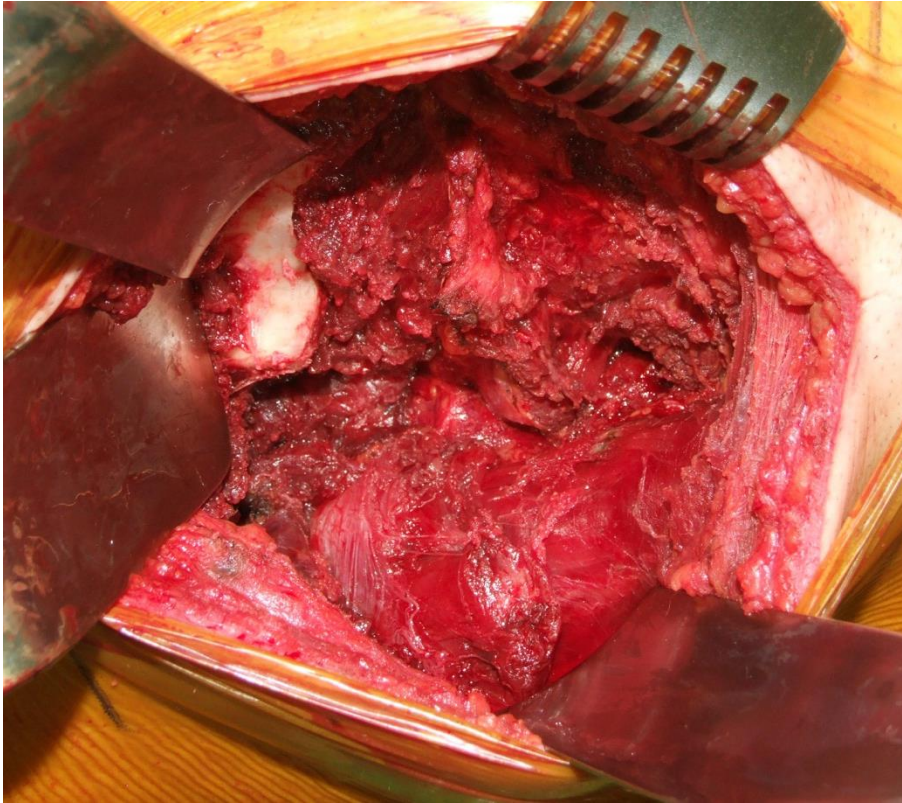resection



Scapula; partial inferior surgery, Feb 01, 2011



Scapula; partial inferior Surgery, Feb 01, 2011



Scapula; partial inferior Histology, Feb 1, 2011

Eingang: 01.02.2011
Ausgang: 09.02.2011

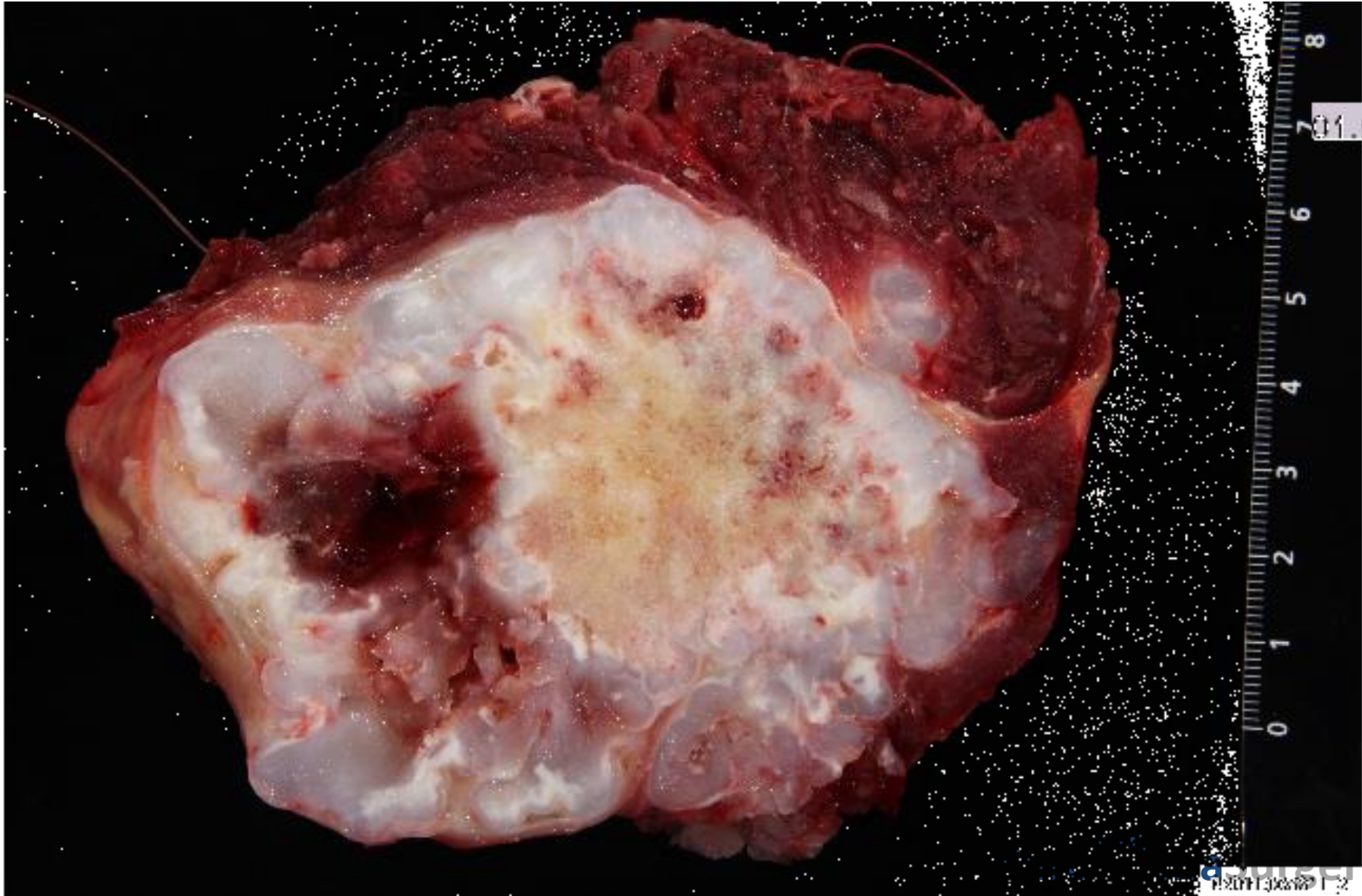
Klinische Angaben

Konventionelles low grade Chondrosarkom Scapula links (USZ B2011.3020). Spezifität?
Resektionsrand? Bemerkungen: Langer Faden Margo lat., kurzer Faden Margo med.

Angaben zur Probe

Distale Scapulaspitze links

Scapula; partial inferior Histology, Feb 1, 2011



Scapula; partial inferior Histology, Feb 1, 2011

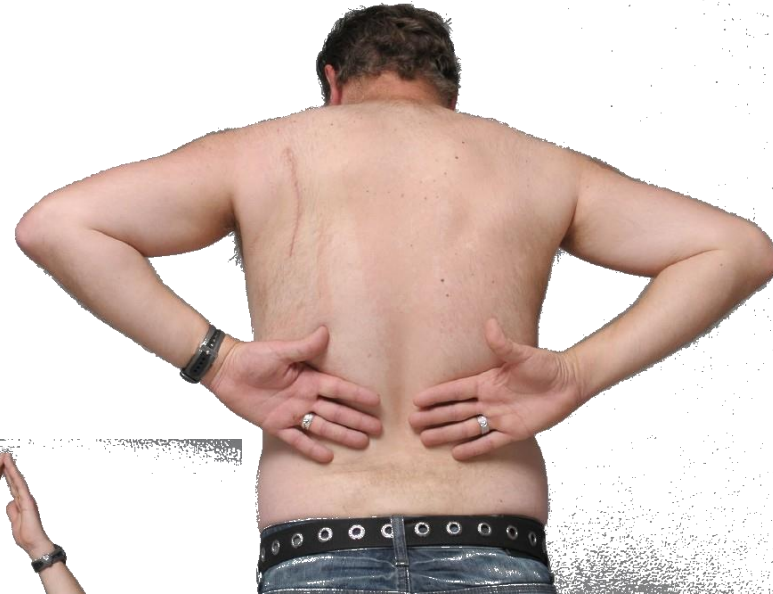
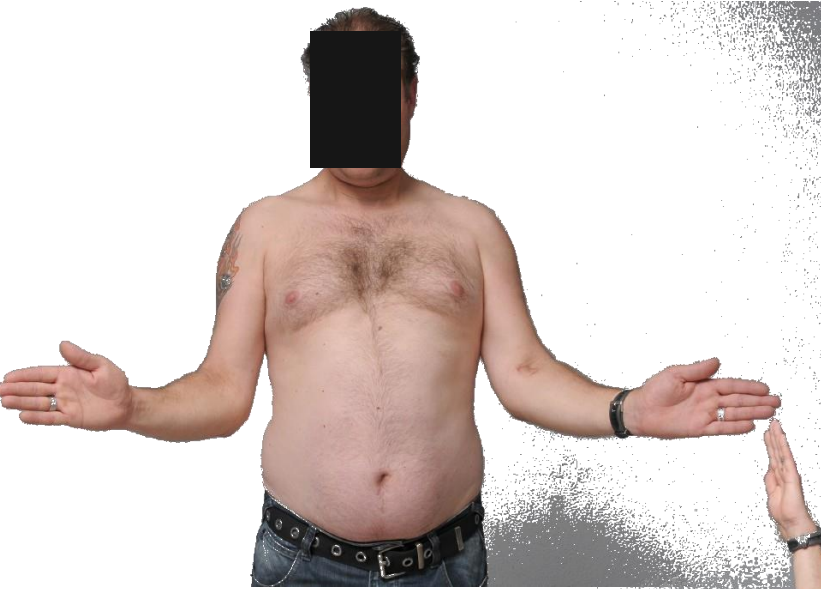G 2011.102;B 2011.3020;G 2011.58

Diagnose

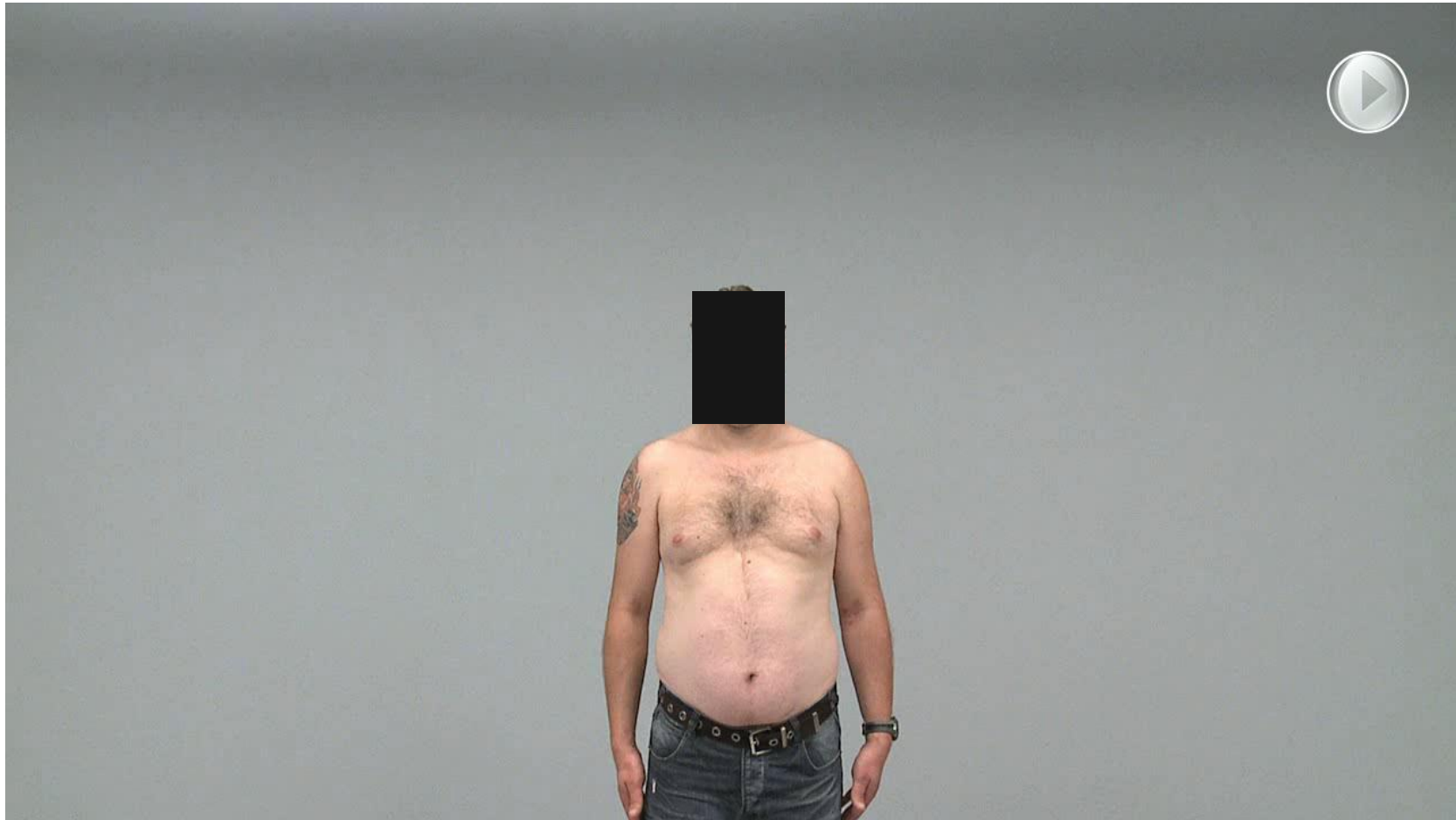
Scapula teilresektat von links mit einem konventionellen Chondrosarkom, Grad I, entstanden auf dem Boden eines Osteochondroms. Resektion im Gesunden.

Scapula; partial inferior

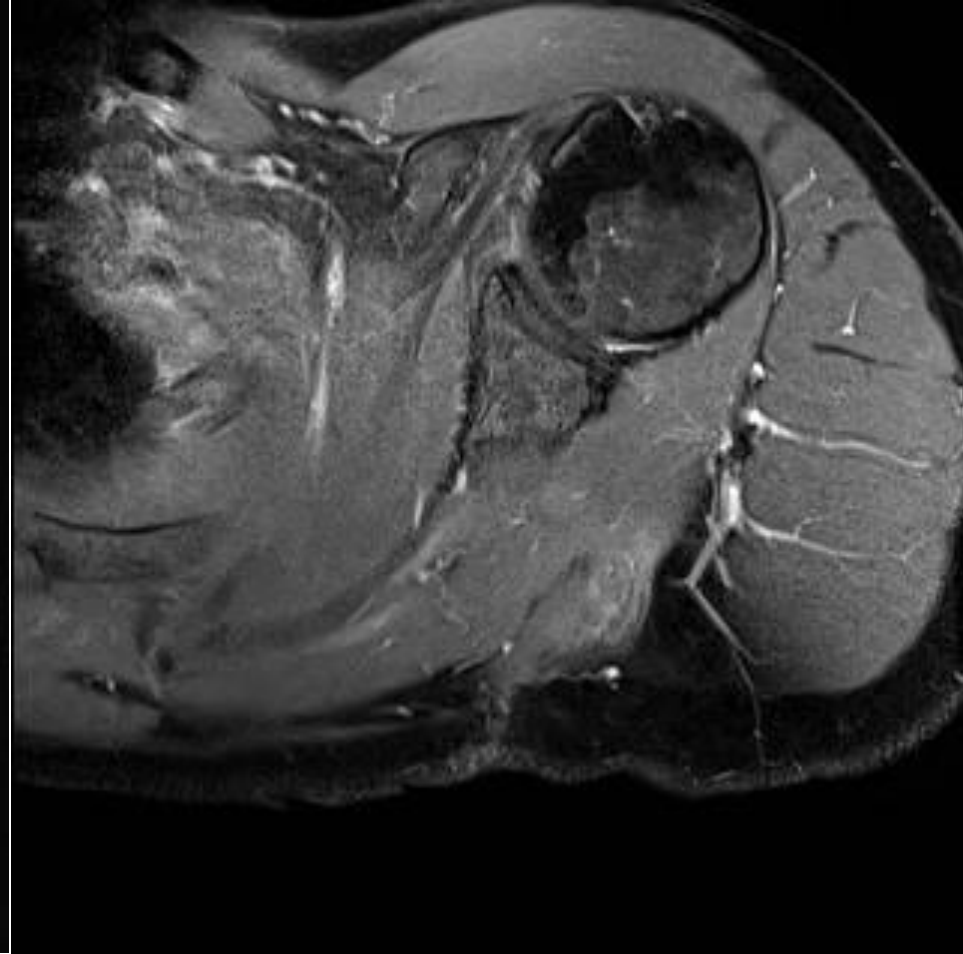
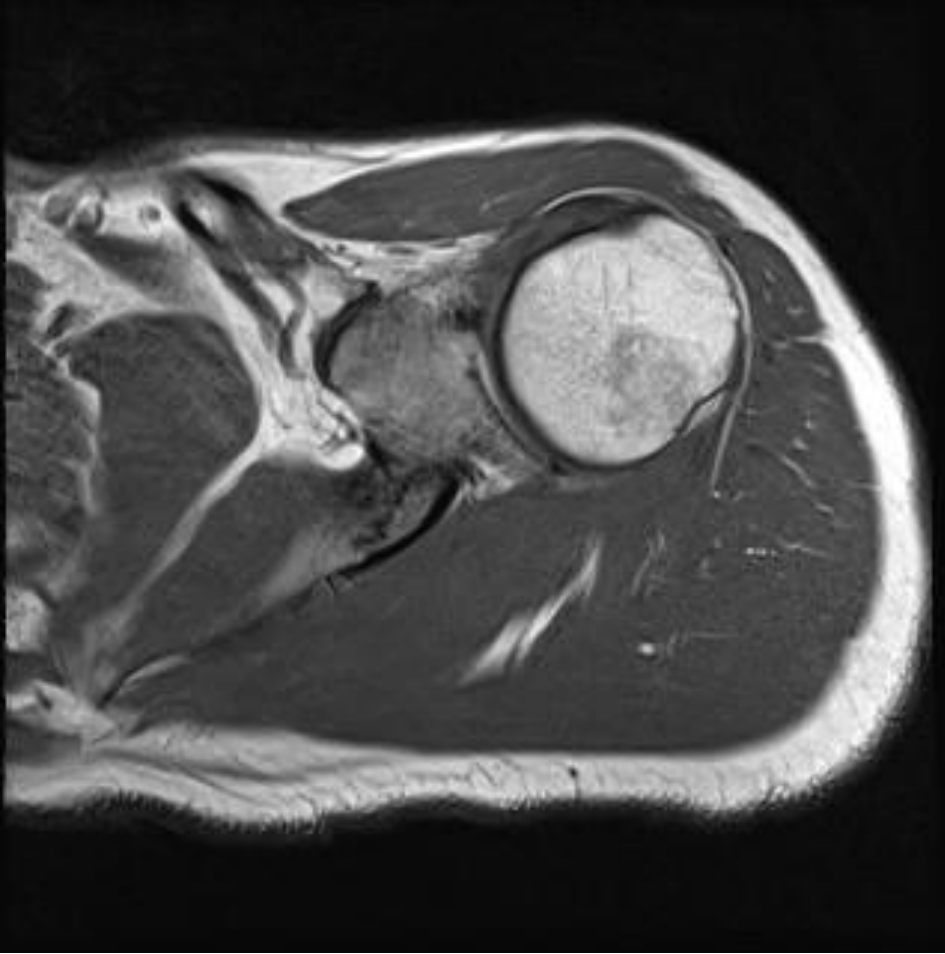Follow up, July 25, 2011



Scapula; partial inferior Follow up, July 25, 2011



Scapula; partial inferior MRI, Sep 28, 2011



No signs of recurrence

Scapula; partial inferior

September 19, 2012

