

Distal Femoral Resection

Annie Arteau, Bruno Fuchs

Introduction

This text is a general description of a distal femoral resection. Focus is on anatomical structures and muscle resection. Each femoral resection is different based on tumor biology, extension and tissue contamination. Good pre-operative imaging is mandatory as well as pre-operative planning. There are many approaches used. We usually do not use a straight anterior approach, but prefer either a lateral or a medial approach determined by the tumor location.

Based on tumor biology (biopsy first!) tumor resection is determined. Which structure can be saved? Nerves (sciatica, femoral, saphenous) or vessels involvement should be anticipated and discussed with the patient first. Important muscle resection can create functional deficit, particularly knee extension weakness. Expected function and major risk like infection or neurovascular deficit should be discussed pre-operatively with the patient; particularly saphenous nerve possible sacrifice and associated medial leg anesthesia.

For a distal femoral resection many anatomical structures should be considered. Normal anatomy must be known to avoid nerve or vessel damage. Remaining structures should be vascularised and innervated. All above structures must be known as well as their anatomic course.

A) Distal femoral transarticular resection: medial approach

A medial approach is chosen based on tumor extension. If a major soft tissue mass is present medially, resection is easier and safer from a medial incision. A medial approach provides a direct dissection, visualization and control of femoral / popliteal vessels. If needed for prosthesis coverage, sartorius or medial gastrocnemius flap can be used through an extended medial approach.

A transarticular or extraarticular (see extraarticular knee resection below) resection is planned based on preoperative imaging. The method of reconstruction is decided preoperatively and accordingly planned.

Skin incision

Bony landmarks are drawn on the skin as well as the level of osteotomy based on pre-operative imaging. Skin incision starts distally medial to patellar tendon and progresses proximally as an antero-medial incision. Biopsy track is resected with an ellipse of normal soft tissue. Proximally, incision ends about 5 cm proximal to osteotomy level.

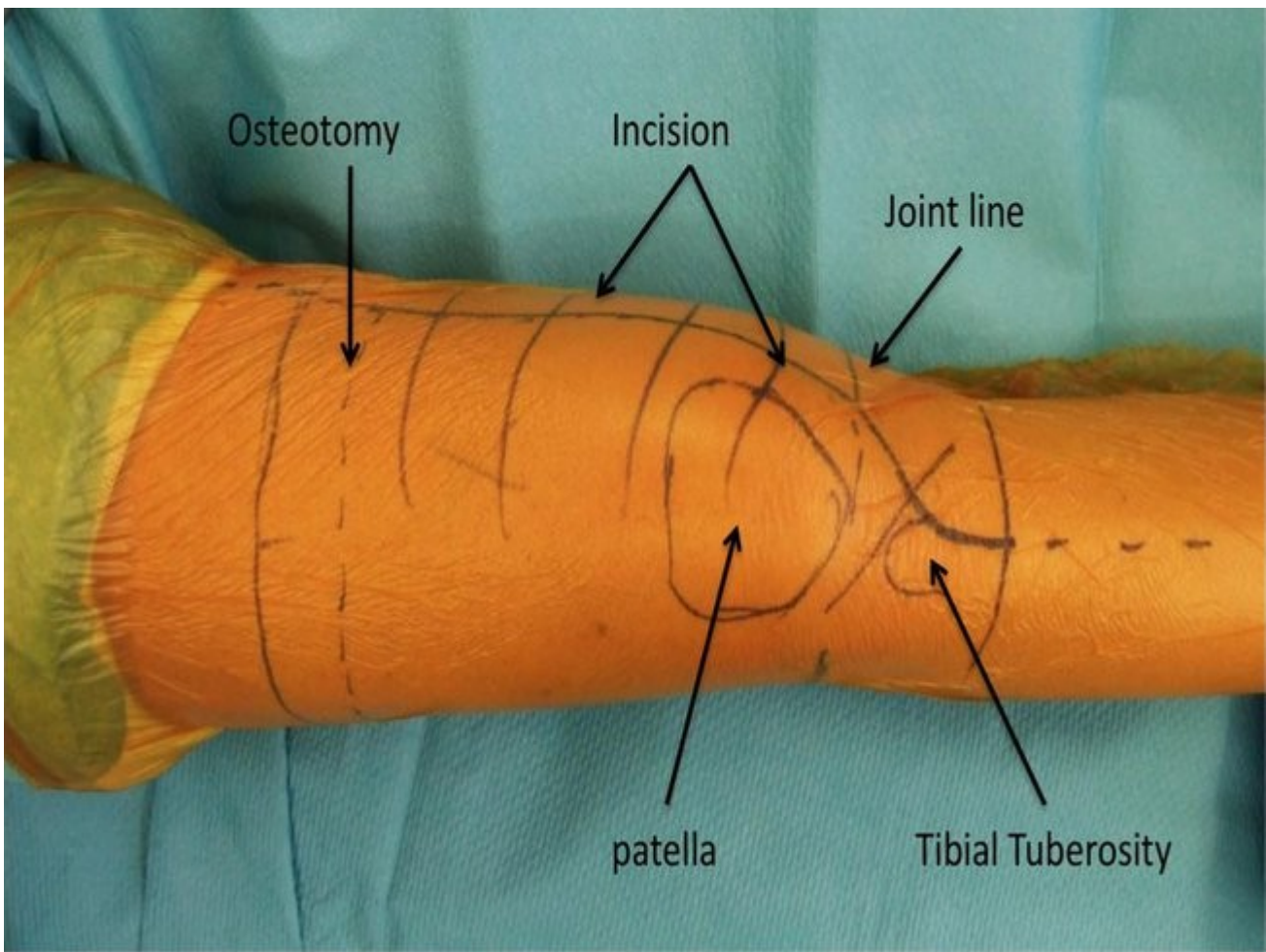


Figure 1: Skin landmarks

Vessels dissection, Preparation of Hunter's Canal

The first step includes the identification of the vessels. Dissection starts with medial fascia opening just over the sartorius muscle proximally to Hunter's canal. Sartorius muscle is in a tendon sheath. A plane can be developed between sartorius and vastus medialis. Then sartorius muscle is retracted postero-medially after sacrifice of some of its multiple vascular pedicles. Alternatively, sartorius muscle can be released from its tibial insertion within the pes anserinus and used as a local flap for prosthesis coverage. Maximal preservation of sartorius vascular pedicles is done if a flap is planned. Superficial femoral artery, femoral vein and saphenous nerve travels just underneath sartorius muscle as anterior structures. At distal 1/3 or 1/4 of the thigh, femoral vessels and saphenous nerve enter Hunter's canal. Hunter's canal is a triangular tunnel (Figure 2). Roof is formed by a thick fascia that bridges vastus medialis and adductor magnus. At the distal part of the canal, saphenous nerve exits the canal anteriorly (Figure 3). It will travel distally as a subcutaneous and medial structure that gives skin sensibility to the antero-medial leg. Hunter's canal roof is then opened carefully to protect saphenous nerve. Alternatively, saphenous nerve can be sacrificed to improve exposure. Adductor hiatus is exposed. Adductor hiatus is formed by adductor magnus tendon that inserts at the tuberculum adductorium. Adductor magnus insertion can be safely released from adductor tubercle. The stump length depends on tumor extension. This allows complete vessel exposure (Fig 4).

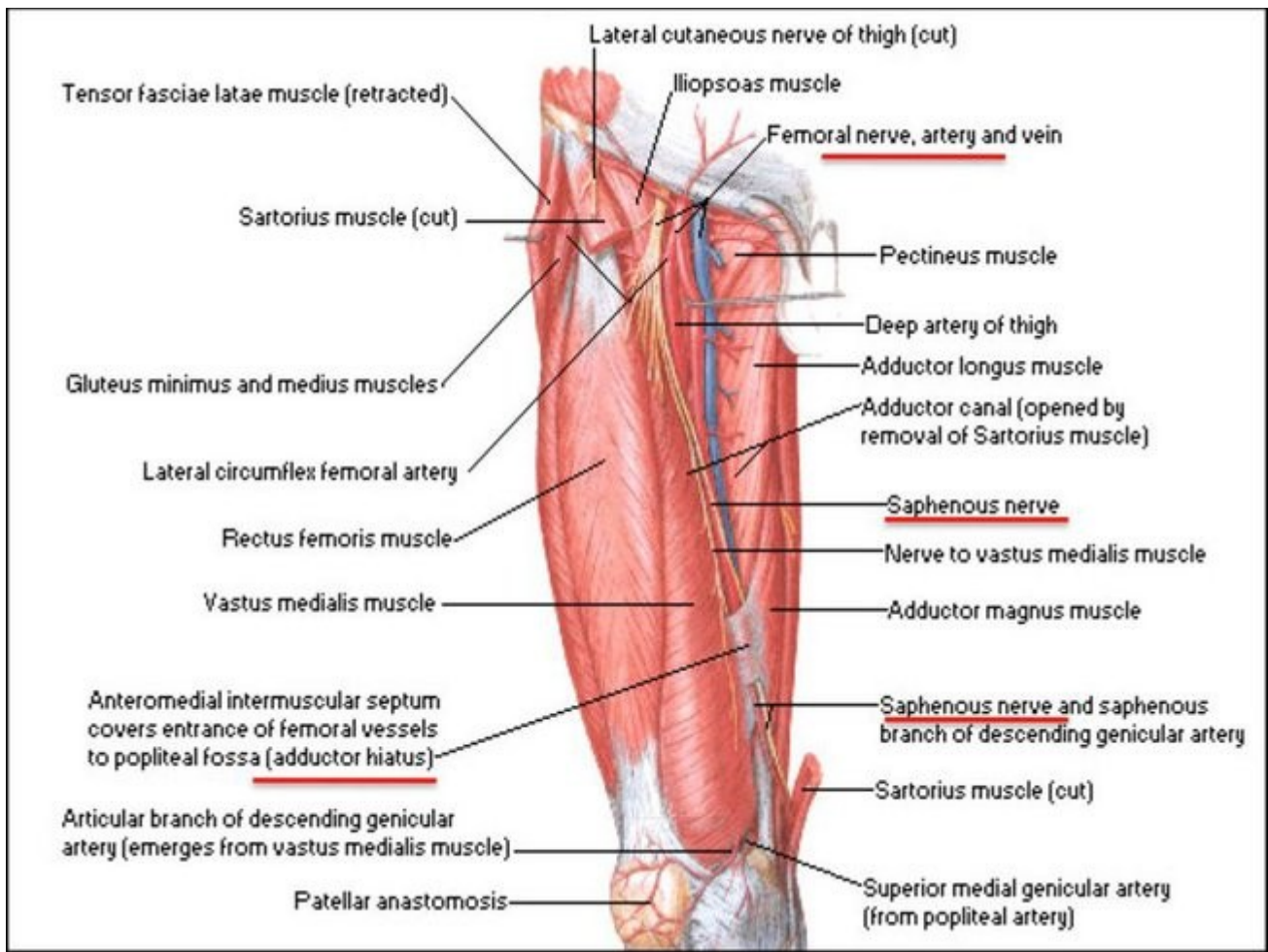


Figure 2: Hunter's canal anatomy

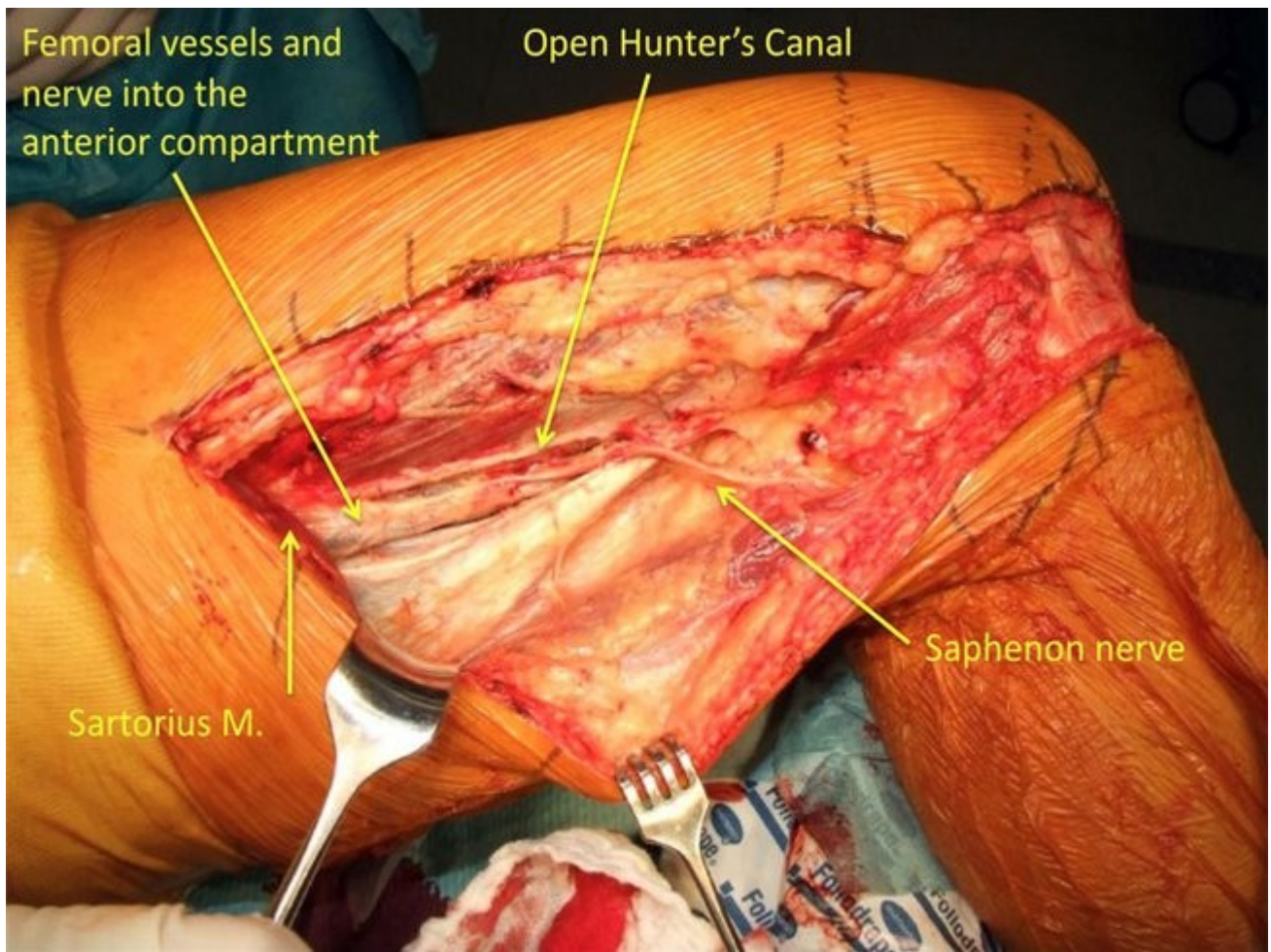


Figure 3: Deep to the sartorius muscle, superficial femoral vessels are found. Saphenous nerve exits Hunter's canal to become a superficial structure.

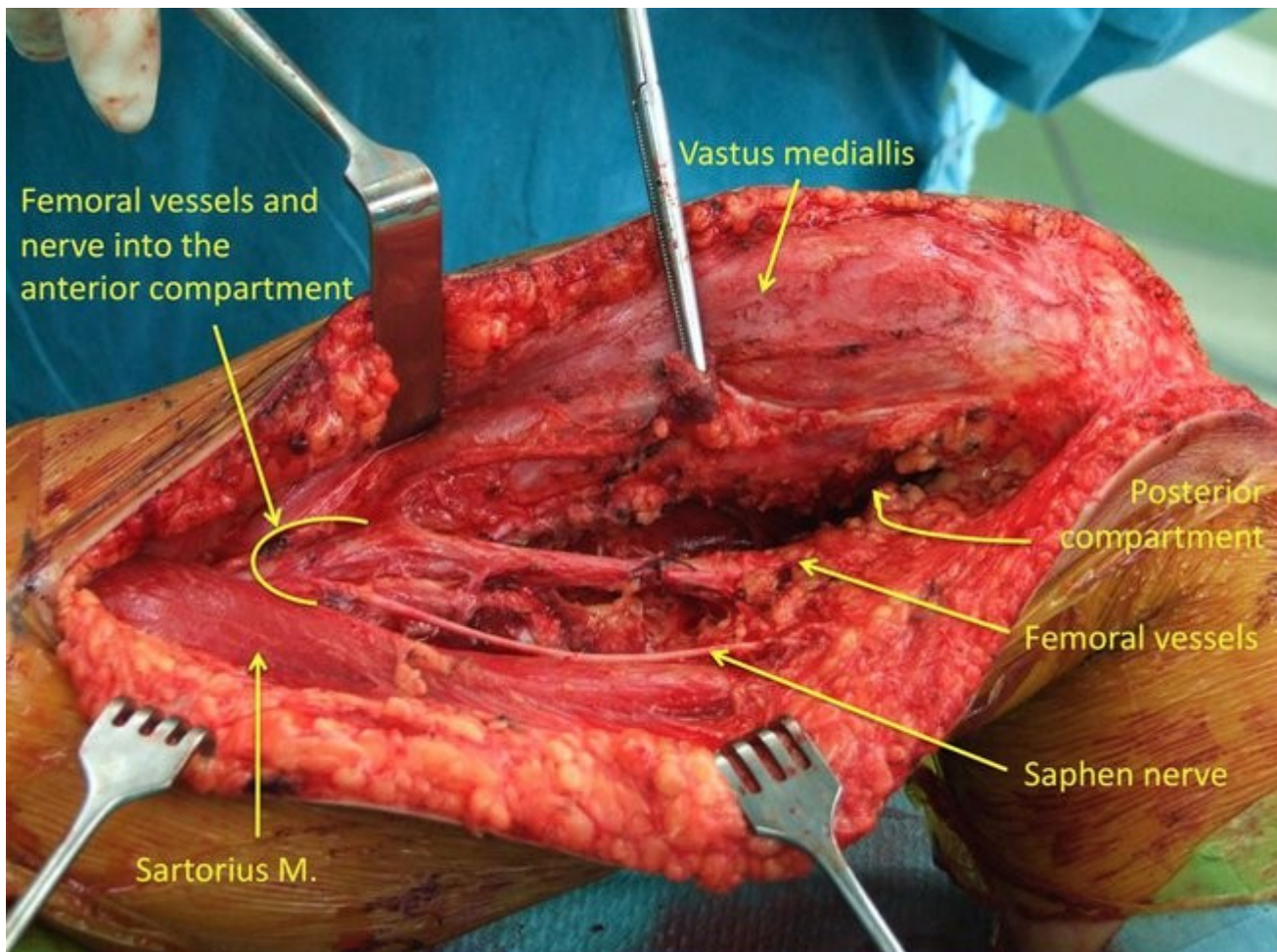


Figure 4: Complete superficial femoral vessels exposure after Hunter's canal preparation and adductor magnus insertion release.

In the posterior compartment, tibial division of sciatic nerve will travel with femoral artery and vein. Tibial nerve is identified with vessels. Medial muscle dissection can be done at this step or after joint opening. The extent of vastus medialis resection depends of tumor extension.

Osteotomy

Osteotomy can be done at this step. Specimen is then dissected in an antegrade fashion from proximal to distal. Alternatively, as shown in figure 5, with a pathologic fracture, it may be easier (or safer) to start distally with an arthrotomy and progress proximally in a retrograde fashion. Before performing the osteotomy, k-wire can be inserted proximally to the tumor and distally at the tibial side to ensure final rotation of the reconstruction. The level of the osteotomy is determined based on preoperative imaging and planning. Level of resection is measured intraoperatively and can be confirmed by intraoperative x-ray to ensure safe tumor margin and to restore exact leg length. Two blunt retractors are installed all around femur shaft to the level of resection to protect soft tissue, vessels and nerves.

Joint opening

First, the medial retinaculum is dissected in a separate layer and preserved for prosthesis coverage. Medial parapatellar arthrotomy is performed. Proximally, arthrotomy can follow a "sub-vastus" approach to preserve muscle vastus medialis as a single unit with rectus femoris if tumor extension allows this type of resection. The joint capsule is opened along the medial border of the patellar

tendon and progresses proximally following femoral capsular insertion if tumor extension permits it. This type of opening provides a large medial capsular flap for prosthesis coverage. Joint is inspected for abnormal fluid or contamination. Both cruciate ligaments are sacrificed. Medial collateral ligament is released from femoral insertion. Medial gastrocnemius is released from femoral condyle as well as posteromedial capsule paying attention not to damage its vascular supply. Popliteal artery, vein and tibial nerve should be protected during posterior capsule release. Extensor mechanism is retracted laterally allowing visualization of lateral knee joint. A valgus stress is helpful as well as internal rotation of the femur. Lateral capsule, lateral collateral ligament and popliteus tendon are released from inside the joint. The common fibular nerve is in danger during this step. Within the posterior thigh compartment, the common fibularis nerve travels between semimembranous muscle and biceps femoris. The semimembranous inserts on the posterior surface of the medial tibial condyle and the biceps femoris inserts at the fibular head. At the level of the knee joint, the nerve is just posterior to the biceps femoris tendon. A lateral capsular release from inside the joint at the femoral side of the joint can be done according to the tumor extent. Then a valgus-flexion stress is added and the lateral gastrocnemius is released from the distal femur (Figure 5). The leg must be hold for the rest of the surgery after joint opening to prevent traction nerve injury.

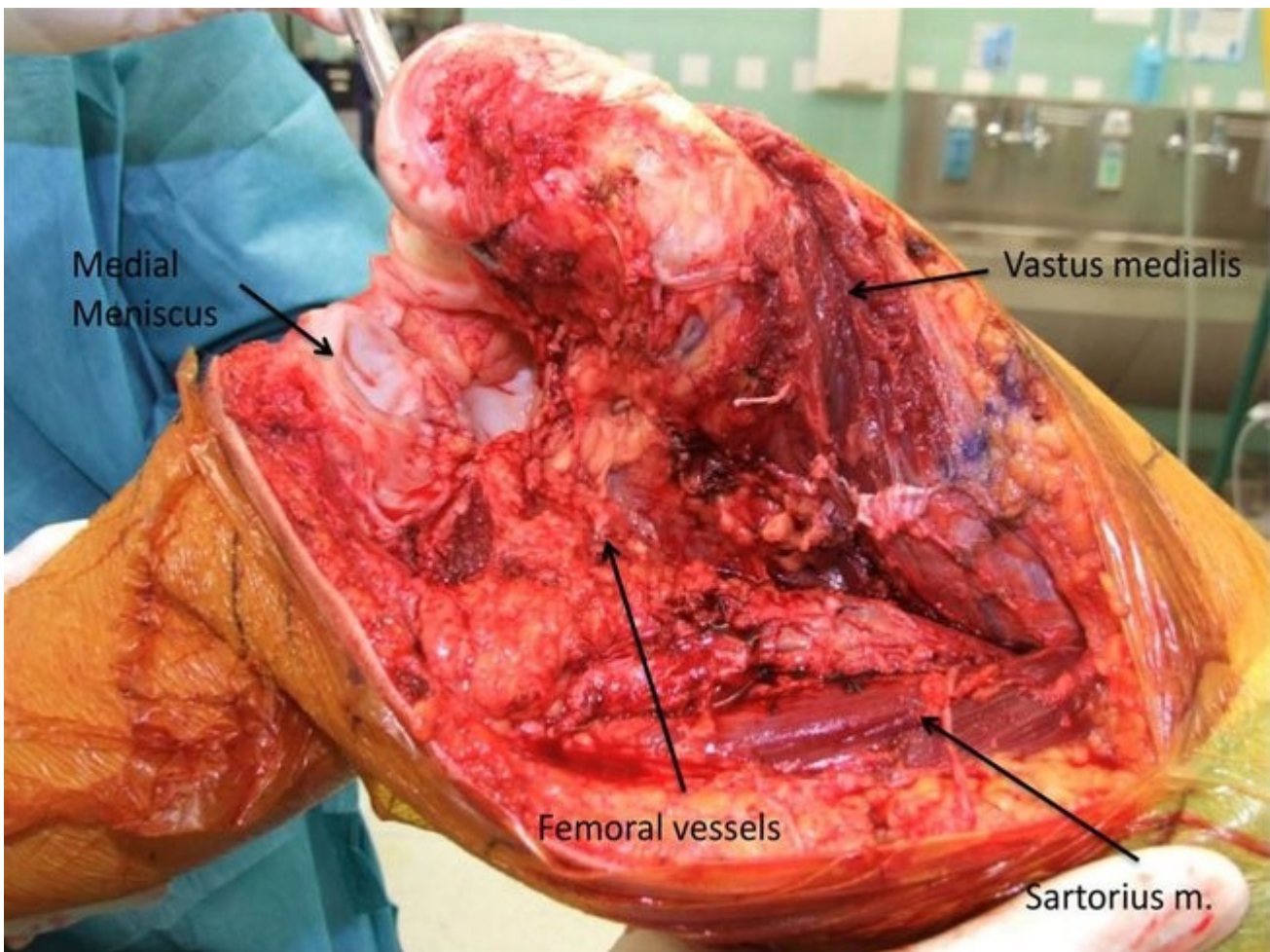


Figure 5: Medial dissection after joint opening. Femoral vessels should be protected during this step.

Muscle dissection

After joint opening, femur can be flexed, the extensor mechanism can be retracted laterally and the femoral vessels posteriorly with tibial nerve. Common fibular nerve is posterior and lateral. This allows safer lateral and posterior dissection.

Anterior compartment muscles (rectus, m. articularis, vastus medialis, intermedius and lateralis) dissection is completed. Based on preoperative MRI, a cuff of muscles is resected with the tumor (tangential dissection of muscles). Medially, adductor longus and magnus insertion are released from femoral insertion (Figure 5). Superficial femoral vessels are superficial to adductor magnus and longus and should be carefully retracted and protected medially during this step. Muscle stump length left with the tumor depends on tumor extension.

Laterally, vastus lateralis is dissected based on tumor extension. Short head of the origin of the biceps femoris is dissected from the postero-lateral femur. Distal femur is flexed. Posterior dissection is completed with direct visualization of femoral vessels.

Osteotomy

If retrograde dissection was planned, the last step is the femoral osteotomy. Again, length of resection is measured, k-wires help for rotation. Blunt retractors are used to prevent soft tissue injuries. Intraoperative measurement of resection length is done and compared with preoperative planning.

Specimen is now free. Specimen is measured to compare to preoperative planning and to plan reconstruction length.

Reconstruction

Many different reconstruction options are available. Probably the most “classic” reconstruction is done with tumor endoprosthesis. Length of prosthesis replacement is determined preoperatively based on length of resection. Leg length should be equal.

Tibia resection is done accordingly considering the specific prosthesis requirement. The tibia canal is prepared. Proximal femur is reamed following company instructions. Reaming instructions depend on prosthesis type and cementation or not. Prosthesis is assembled, tibial stem is inserted, tibial plateau is cemented. Femoral component is completely installed and linked.

A careful hemostasis is done before closure to avoid post operative hematoma. A drain is put in line with the incision.

Prosthesis coverage

Preservation of medial joint capsule and retinaculum provides soft tissue coverage for prosthesis, therefore, careful dissection during resection is critical. Sometimes, medial soft tissue preservation is not possible because of tumor extension or inadequate tissue quality. Then a local flap must be used to cover prosthesis. Two local flaps are available: medial gastrocnemius and sartorius muscle. A free flap can also be used.

Sartorius muscle can be detached from its tibial insertion and transferred anteriorly to cover the defect (figure 6). Sartorius mobilization is possible after sacrifice of some of its vascular pedicles.

Five to nine vascular pedicles, starting at the deep femoral artery, perfuse the muscle in a segmental fashion but a dense anastomotic network exists between the pedicles[1]. This allows the surgeon to

sacrifice some pedicles for muscle better mobilization. Innervation is from one or two branches of the femoral nerve that enters muscle undersurface proximally. If a small capsular defect is anticipated, a sartorius flap is easily available and safely harvested if some vascular pedicles are preserved.

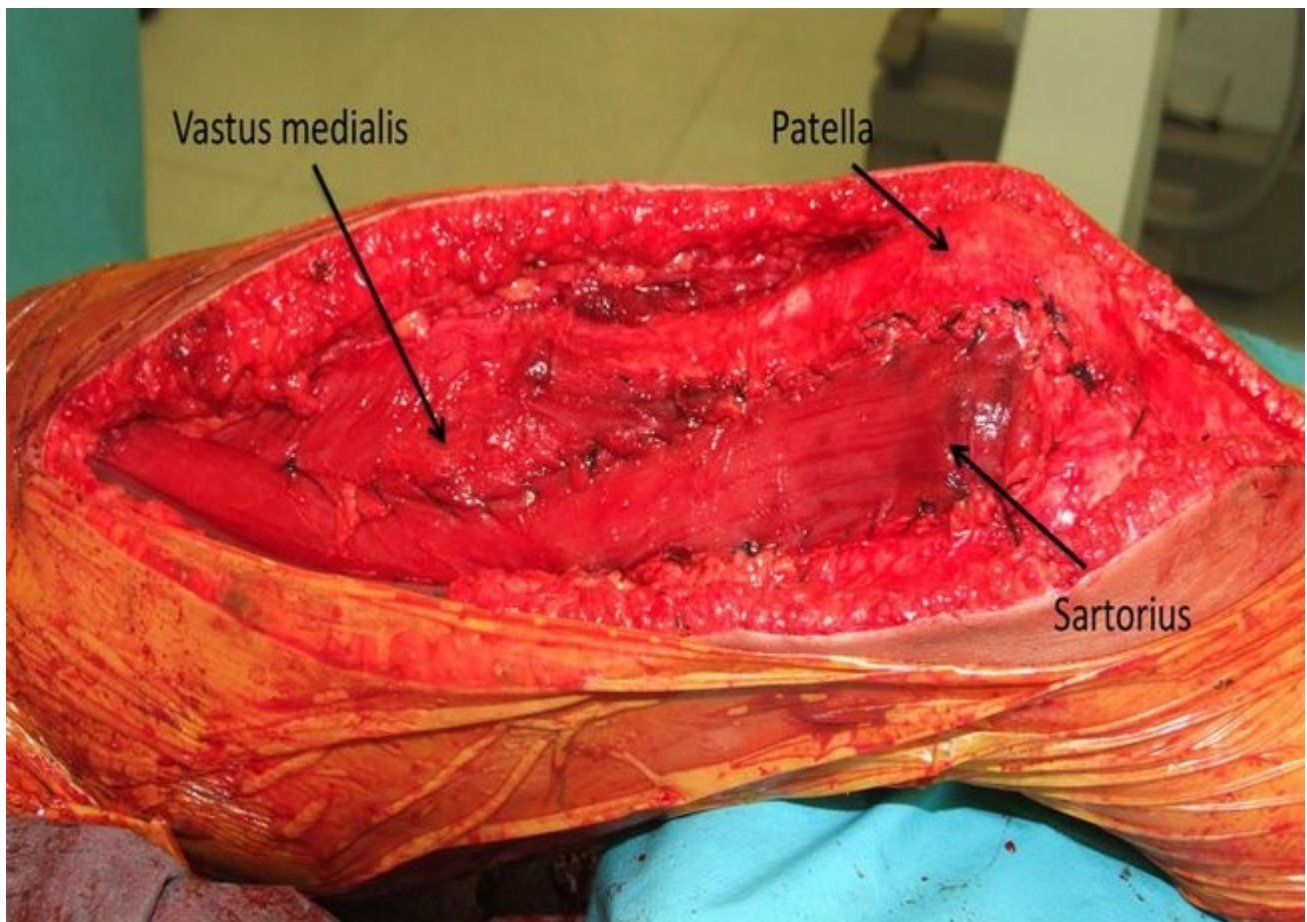


Figure 6: Sartorius flap used to cover prosthesis

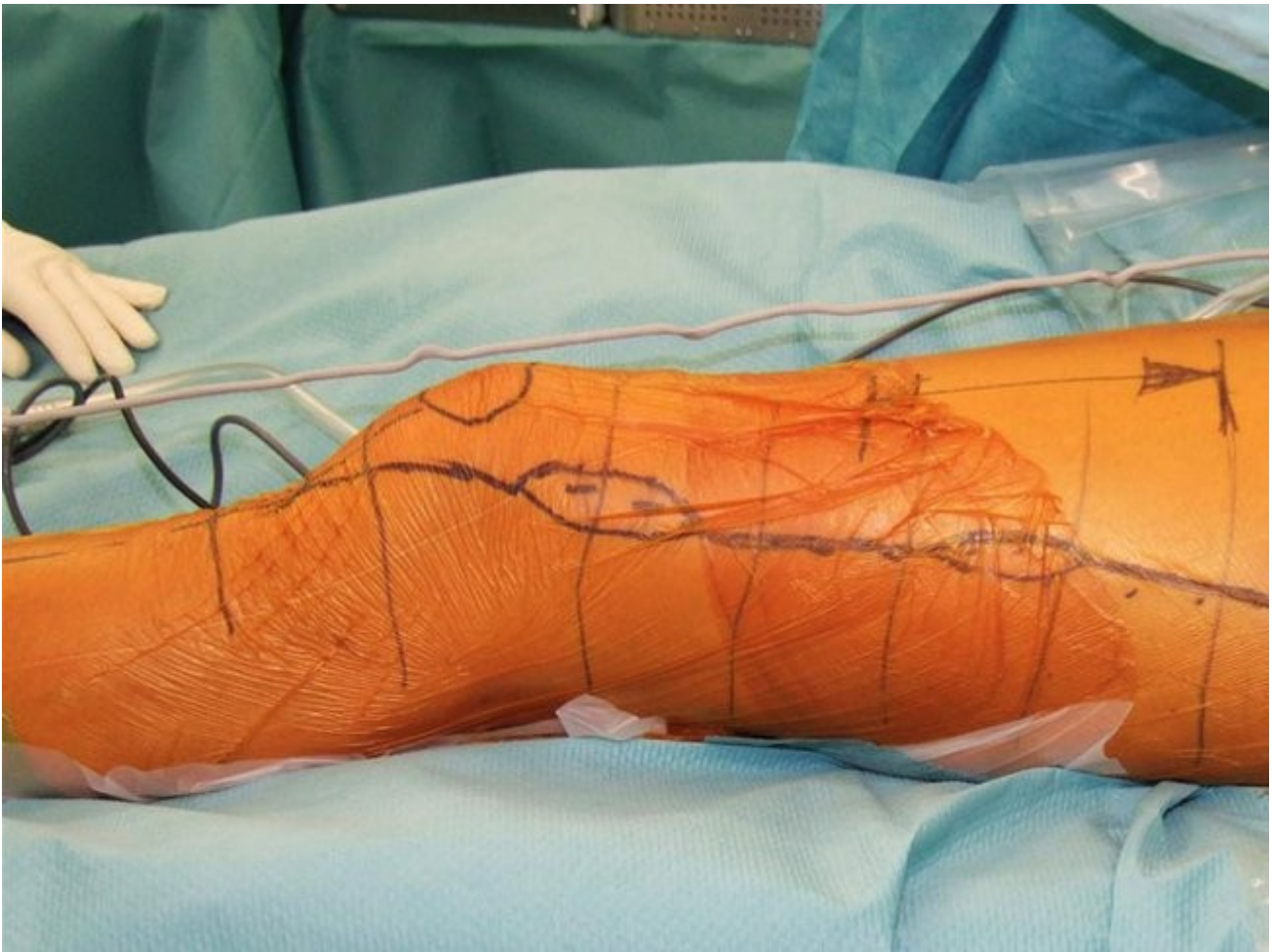
A medial gastrocnemius flap can also be used to cover the soft tissue defect. A plane is developed between gastroc and soleus muscles. Sural artery, the medial gastroc vascular pedicle from poplitea artery, is localized about 3 cm above the joint line. The plane between medial and lateral heads is developed from proximal to distal (median raphe). The sural nerve can be localized lateral to the raphe. Distally, medial gastrocnemius is detached with a small amount of achilles tendon. If knee extensor mechanism reconstruction is needed too, medial 1/3 of Achilles tendon can be harvested with the medial gastroc. Medial gastrocnemius flap can be mobilized to cover the medial prosthesis. Flap length can be increased incising the deep fascia.

Finally, a multiple layers closure is done as well as a perfect skin closure. A neuro vascular exam is performed as soon as patient is awake.

B) Distal femoral transarticular resection: lateral approach

Skin incision

Incision is lateral, below the knee joint it follows lateral border of patellar tendon. Elliptical resection of the previous scar and biopsy is done (Figure 7).



Fascia lata

Skin incision is just posterior to fascia lata. An ellipse of fascia and muscle around the biopsy is resected en bloc with the tumor. Try to preserve maximum of the fascia distally for closure. Lateral retinaculum of knee joint should be preserved too if possible. Alternatively, fascia lata insertion on Gerdy tuberculum can be elevated and preserved for prosthesis coverage.

Isolation of sciatic nerve

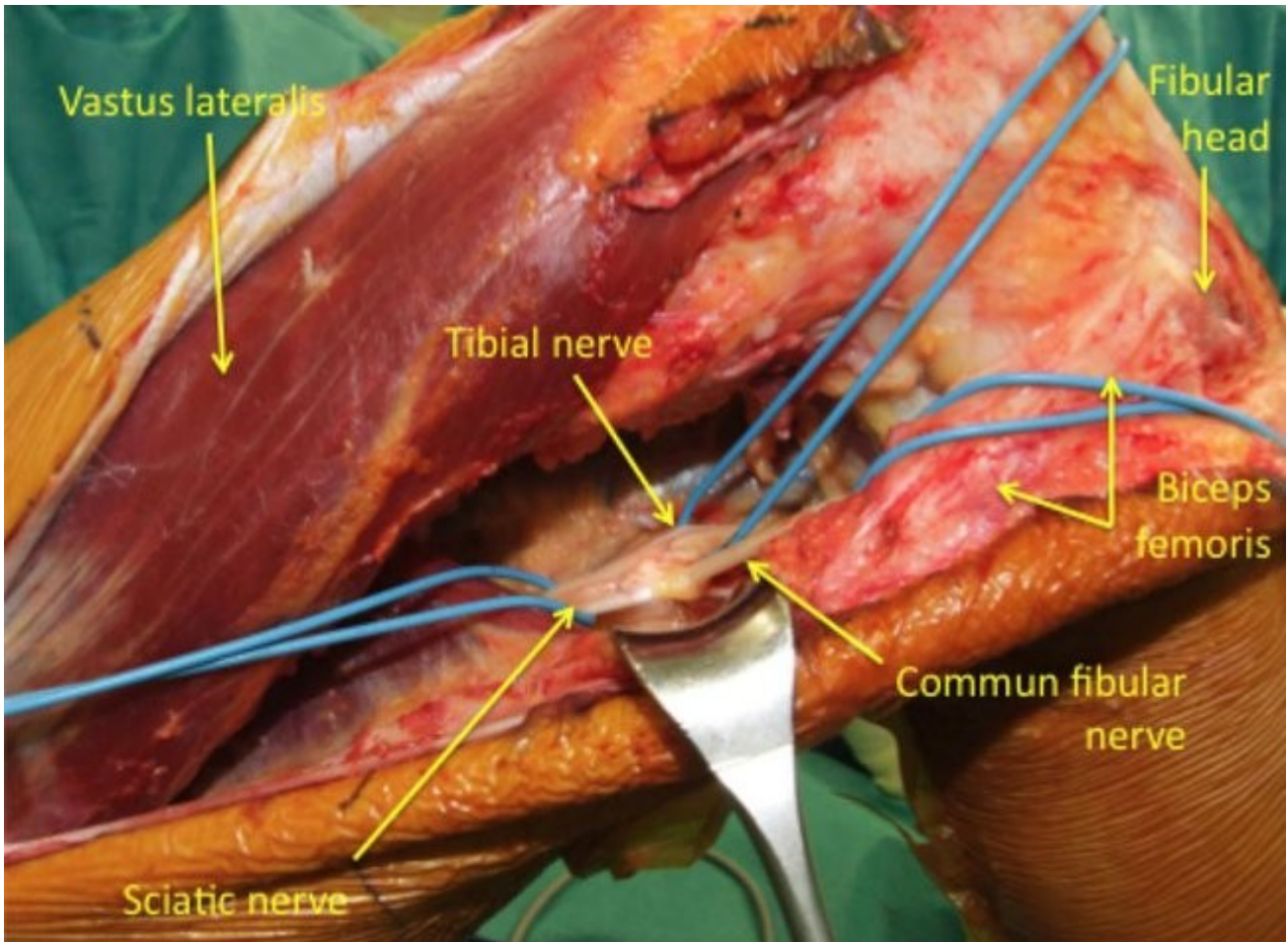


Figure 8: Sciatic nerve isolation with tibial and fibular division

The vastus lateralis is retracted medially to expose the lateral intermuscular septum. This is then opened to find access to the posterior compartment with the biceps femoris muscle underneath it. Common fibular nerve will appear just posterior to biceps tendon at about distal $\frac{1}{4}$ of the thigh. The nerve is dissected from distally to proximally. It travels between biceps and semimembranous muscle in the posterior compartment. Based on preoperative imaging the nerve can be safely followed. The sciatic nerve division is found in a “retrograde” fashion. Then you can follow tibial division distally. Femoral vessels will appear on the nerve course distally. The vastus lateralis muscle is dissected according to tumor extension. Tangential dissection is sometimes necessary. The short head of the biceps femoris is also dissected accordingly to tumor extension.

Osteotomy

Osteotomy can be done at this step. Specimen is then dissected in an antegrade fashion from proximal to distal (Figure 9). Alternatively, as shown in figure 5, with a pathologic fracture, it may be easier or safer to start distally with arthrotomy and progress proximally in a retrograde fashion.

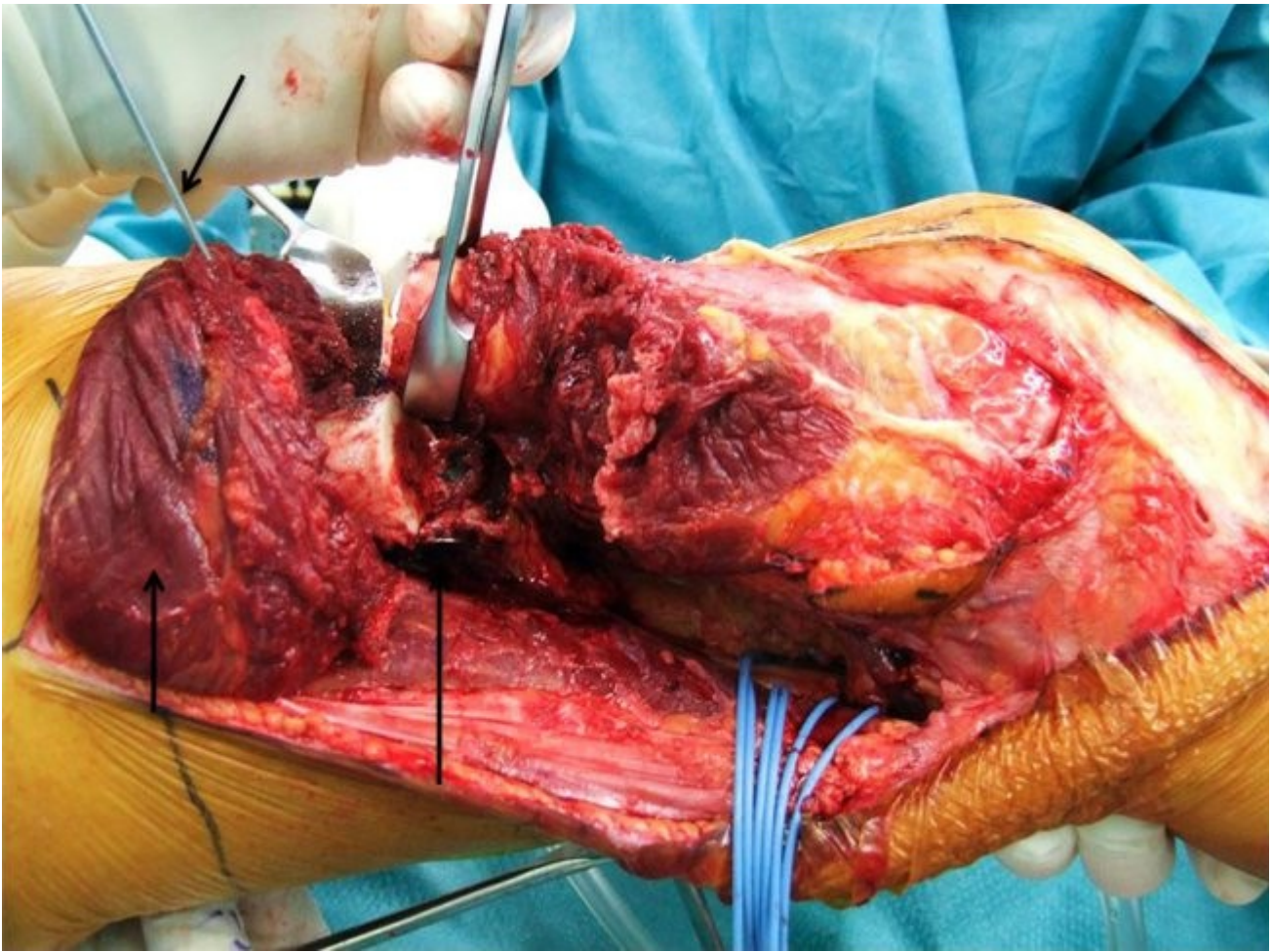


Figure 9: Osteotomy is done after K-wire placement to account for the rotation. Dissection can progress in an antegrad fashion. Joint opening is done as the last step.

Before performing osteotomy, k-wire can be put proximally to the tumor and distally at tibial side to ensure final rotation and leg length of the reconstruction. Level of osteotomy is determined based on preoperative imaging and planning. The level of resection is measured intraoperatively and can be confirmed by intraoperative x-ray to ensure safe tumor margin and to restore exact leg length. Two blunt retractors are installed all around the femoral shaft to the level of the resection to protect soft tissues, vessels and nerves.

Joint preparation

Lateral retinaculum is preserved as a separate layer. Fascia lata can be elevated from Gerdy's tubercle to extend the exposure and to keep it for prosthesis coverage. The joint is opened using a lateral parapatellar arthrotomy. Distally, the vastus lateralis should not be separated from the rectus during arthrotomy to preserve vascularisation. A large lateral capsule flap is created for closure. Capsule is dissected along patellar tendon and following femoral insertion.

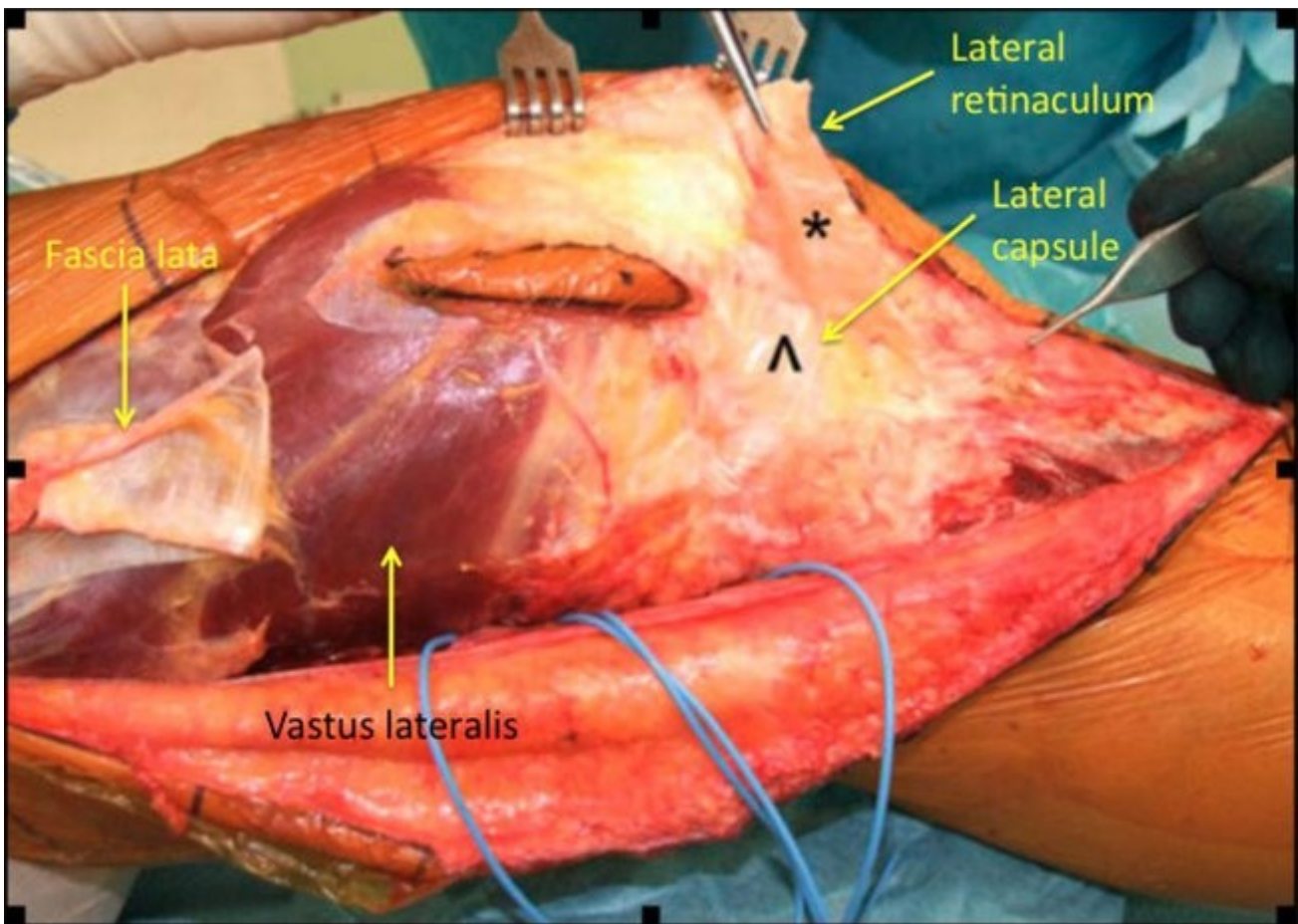


Figure 10: Lateral retinaculum dissection and fascia lata elevation from Gerdy's tubercle

Lateral collateral ligament is detached from femoral insertion, popliteus tendon and both cruciate ligaments are sacrificed. Medial capsule is dissected from its femoral insertion with MCL after medial retraction of extensor mechanism. Varus stress can improve exposure.

Then the lateral gastrocnemius can be released from the distal femur but first, go back to in the posterior compartment to follow nerve and vessels. Then you can release lateral gastrocnemius safely because popliteus vessels and tibial division of sciatic nerve are exposed. Finally, medial gastroc can be safely detached as well as posterior capsule. Both nerves and vessels should be protected during this step. Semimembraneous will remain with posterior capsule. Medial dissection can progress from distal to proximal.

Medial thigh dissection

Distal to proximal dissection is done. Extensor mechanism is retracted medially. Abduction of the entire femur will expose medial side. Sartorius is retracted medially and inferiorly with rectus.

Tumor extension dictates resection of vastus medialis, intermedius and rectus. Adductor magnus insertion is released from adductor tuberculum. This will expose superficial femoral vessels into adductor hiatus. Vessels are identified. Hunter's canal preparation is done. Medial dissection can progress close to the bone depending of tumor extension. Adductor magnus and longus are dissected from its femoral insertion. Perforating arteries from the deep femoral artery can be safely coagulated or clipped. If osteotomy is already done, dissection can also progress from proximal to distal.

Osteotomy

The osteotomy is not done at this step, medial dissection will end just proximal to the level of osteotomy planned with pre-operative imaging. Intraoperative measurement of the resection length is done. Osteotomy is performed after two blunt retractors installation.

Reconstruction

Reconstruction is done as with a medial approach.

Prosthesis coverage

Previous elevation of fascia lata from Gerdy tubercle create a good layer of soft tissue for prosthesis coverage. Alternatively, a lateral gastrocnemius flap can be used as a local flap. Like for a medial gastroc flap, a plane is developed between gastroc and soleus muscle. Vascular pedicle of lateral gastroc is also sural artery that can be found 3 cm proximally to the joint line. Again, a plane is developed between the medial and lateral heads. Distally, the lateral head is dissected with a small stump of Achilles tendon. Flap is mobilized anteriorly. Care must be taken to not compress the commun fibular nerve. Flap is passed medially to biceps tendon and fibular nerve.

Multiple layer closure and skin closure is done after drain installation.

C) Distal femoral extraarticular knee resection

Introduction

Indications to perform an extraarticular knee resection are: pathologic fracture with joint contamination, intraarticular tumor extension (along cruciate ligaments or into the posterior condyles who lies intraarticular), direct involvement of the knee, inappropriate biopsy placement and intraarticular contamination of a whoop's lesion. Extraarticular resection can be done from a medial or a lateral approach (see medial and lateral extraarticular resection above).

Joint preparation [1]

Medial or lateral retinaculum should be dissected from knee capsule as a separate layer and preserved for prosthesis coverage (Figure 10). Laterally, the fascia lata is dissected out of lateral retinaculum and elevated from Gerdy's tubercle. A careful dissection is done. Lateral or medial patellar facet is prepared without violating the joint capsule.

Two Kirschner wire are placed in a frontal plane into the patella under fluoroscopy control.

Osteotomy is performed with an oscillating saw, superficial to K-Wires. Patella osteotomy should preserve about 15 mm of bone for patellar replacement (Figure 11). Based on preoperative imaging, tangential dissection of the quadriceps tendon in a frontal plane is done avoiding suprapatellar recess or tumor penetration. Proximal dissection of the specimen is done accordingly to tumor extension. Proximal osteotomy is performed at this step.

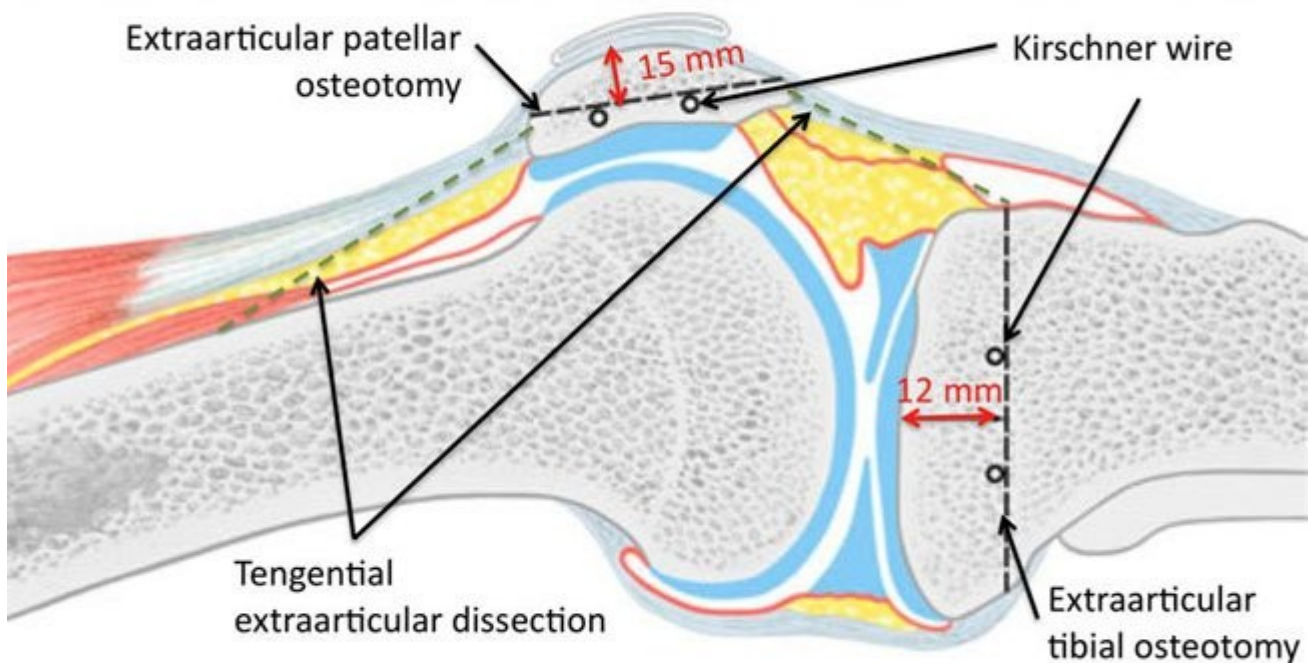


Figure 11: Patellar and tibial osteotomy. Tangential dissection of the quadriceps and patellar tendon in a frontal plane

Distally, Hoffa fat pad is left with the specimen because this structure is partly intraarticular. Again, dissection follows patellar tendon undersurface in a frontal plane.

Tibial osteotomy is planed about 12 mm below tibial plateau: the osteotomy is then distal to the joint capsule insertion and proximal to tibial tubercle. The tibial tubercle should be preserved to save the patellar tendon insertion. Two k-wires are placed in an axial plane under fluoroscopic control prior to osteotomy. Osteotomy is performed with an oscillating saw. Osteotomy is done below k-wires to avoid fracture propagation within the joint during this cut.

Finally medial or lateral dissection is completed. The specimen is rotated to allow opposite retinaculum dissection from joint capsule. The gastrocnemius origin is removed with the specimen to provide safe posterior capsular margin.

Specimen is now free.

Reconstruction

Reconstruction is done according to preoperative planning as with intraarticular resection. Patellar replacement is done like for a primary total knee arthroplasty.

Prosthesis coverage

Preserved medial or lateral retinaculum are used for prosthesis coverage. Local medial or lateral flaps are harvested if needed (see medial or lateral prosthesis coverage above).

A standard multiple layer closure is done as well as a standard post-operative mobilization protocol.